



## The Effectiveness of Bilateral Pectoralis Nerve Block in Cardiac Surgery Patients for Managing Postoperative Pain

Rajat Shuvra Das<sup>1\*</sup>, A.K.M. Faizul Hoque<sup>2</sup>, Ayesha Sultana<sup>3</sup>, Mohammad Abdul Hannan<sup>4</sup>, Mehdi Hassan<sup>5</sup>, Chandra Shekhar Karmakar<sup>6</sup>, A B M Sarwar Jahan<sup>7</sup>, Muhammed Sharif Uddin Siddique<sup>8</sup>, AKM Habibullah<sup>9</sup>

<sup>1</sup>Assistant Professor, Department of Anaesthesia, Analgesia and Intensive Care Medicine, Bangabandhu Sheikh Mujib Medical University, Shahbag, Dhaka.

Email: rajatsdas1351@bsmmu.edu.bd,

Orcid Id: 0009-0000-1513-0180

<sup>2</sup>Professor, Department of Anaesthesia, Analgesia and Intensive Care Medicine, Bangabandhu Sheikh Mujib Medical University, Shahbag, Dhaka.

Email: akmfaizul@gmail.com,

Orcid ID: 0009-0007-91922957

<sup>3</sup>Assistant Professor, Department of Anaesthesia, Analgesia and Intensive Care Medicine, Bangabandhu Sheikh Mujib Medical University, Shahbag, Dhaka.

Email: ayesha814736@gmail,

Orcid ID: 0009-0004-9107-6138

<sup>4</sup>Assistant Professor, Department of Anaesthesia, Analgesia and Intensive Care Medicine, Bangabandhu Sheikh Mujib Medical University, Shahbag, Dhaka.

Email: drhannan73@gmail.com,

Orcid ID: 0009-0006-1949-2756

<sup>5</sup>Assistant Professor, Department of Anaesthesia, Analgesia and Intensive Care Medicine, Bangabandhu Sheikh Mujib Medical University, Shahbag, Dhaka.

Email: mehdi hassanmm1@gmail.com,

Orcid ID: 0000-0002-4952-4556

<sup>6</sup>Assistant Professor, Department of Anaesthesia, Analgesia and Intensive Care Medicine, Bangabandhu Sheikh Mujib Medical University, Shahbag, Dhaka.

Email: tuser.saiful@gmail.com,

Orcid ID: 0009-0009-9497-9099

<sup>7</sup>Junior Consultant, Department of Anaesthesia, Analgesia and Intensive Care Medicine, Bangabandhu Sheikh Mujib Medical University, Shahbag, Dhaka.

Email: sarwar.mmc31@gmail.com,

Orcid ID: 0009-0003-9466-830X

<sup>8</sup>Resident, Department of Anaesthesia, Analgesia and Intensive Care Medicine, Bangabandhu Sheikh Mujib Medical University, Shahbag, Dhaka.

Email: sharifbsmmu@gmail.com,

Orcid ID: 0009-0007-6762-698X

### Abstract

**Background:** Effective pain management following cardiac surgery contributes to enhanced recovery and increased mobility. But the coagulation status of the cardiac surgery patients makes neuraxial blocks risky. An alternative to neuraxial blocks for post operative pain management after adult cardiac surgeries is the Pectoralis Nerve (Pecs) block. This innovative technique offers a safe and minimally invasive approach for post operative pain management after adult cardiac surgeries. The objective of the study was to investigate the effectiveness of bilateral pectoralis nerve block in cardiac surgery with regards to enhanced recovery and postoperative pain management. **Material & Methods:** This was a quasi-experimental study and was conducted in the Department of Anaesthesia, Analgesia and Intensive care medicine of Bangabandhu Sheikh Mujib Medical University (BSMMU) Hospital, Dhaka, Bangladesh during the period from January 2023 to June 2023. This study involved 40 adult cardiac surgery patients (25-65 years) undergoing coronary artery bypass grafting and valve repair or replacement surgeries via midline sternotomy. They were divided into two groups: Group A received conventional analgesia with intravenous paracetamol 01 gm TDS with continuous intravevous infusion of 1 microgram per kg body weight of fentanyl, and Group B received ultrasound guided bilateral Pectoral Nerve (PEC) block with volume of 0.2 ml per kg body weight of 0.25% bupivacaine with 5 mg of dexamethasone for each interfascial plane. Extubation criteria were used, and data were collected through a questionnaire for visual analogue score and vital parameters such as heart rate, blood pressure, respiratory rate, duration on invasive ventilation at 0 hour, 02 hour, 04 hour, 08 hour and 12 hour post operatively. **Results:** In total 40 patients from both the groups completed the study. The study found no significant differences in vital parameters between Group A and Group B. Group B showed significantly lower pain scores upto 12 hours post-extubation. Respiratory rate was significantly lower in Group B at six assessment times.



<sup>9</sup>Assistant Professor, Department of Anaesthesia, Analgesia and Intensive Care Medicine, Bangabandhu Sheikh Mujib Medical University, Shahbag, Dhaka.

Email: drupalhabib@gmail,

Orcid ID: 0009-0009-0773-6372

\*Corresponding author

Received: 30 September 2023

Revised: 02 November 2023

Accepted: 16 November 2023

Published: 31 December 2023

No significant differences were observed in hemodynamic variables. Group B had a shorter ICU stay compared to Group A, but no significant difference in hospital stays or duration of ventilator use between the groups. **Conclusions:** The Pectoral Nerve (Pecs) block is an effective and less invasive and safe procedure for managing postoperative pain and enhancing recovery in adult cardiac surgeries such as CABG, valve repair or replacement surgeries with a medial sternotomy.

**Keywords:-** Cardiac Surgery, Pectoralis Nerve Block, Pain Management.

## INTRODUCTION

Cardiac surgeries such as CABG, valve replacements procedures via a medial sternotomy can be linked to significant discomfort and pain in the postoperative period.<sup>[1]</sup> Effective dynamic pain control has become an essential requirement for achieving swift recovery in the initial stages following surgery.<sup>[2]</sup> Inadequate pain control in the early stages after surgery can have harmful impacts on the respiratory system (resulting in atelectasis, pneumonia, and stagnant bronchial secretions), the cardiovascular system (leading to higher oxygen consumption and rapid heart rate), as well as the musculoskeletal system (causing muscle weakness and underutilization). Additionally, it triggers stress reactions and elevated blood sugar levels.<sup>[3]</sup> In the age of enhanced recovery, effective pain relief after cardiac surgery plays a pivotal role in expediting recuperation, promoting mobility, and facilitating prompt discharge from the Intensive Care Unit (ICU). Traditionally, nonsteroidal anti-inflammatory drugs (NSAIDs) and opioids, which have adverse effects and slow healing times, are used to alleviate pain in postoperative cardiac surgical patients. By regulating the stress response and

reducing the demand for opioids, effective acute pain management protects immunological function. Both cellular and humoral immunological activities are inhibited by opioids, particularly morphine.<sup>[4]</sup> On the other hand, thoracic epidurals and paravertebral blocks have been widely utilized and tested over time, yielding favorable outcomes. Nevertheless, not all anesthesiologists feel at ease or possess the necessary expertise to administer these in-depth nerve blocks due to potential risks like development of epidural hematomas, along with concerns about anticoagulation. As an alternative for patients undergoing thoracic surgeries, the pectoral nerve (Pecs) block could be considered, encompassing Pecs 1 and Pecs 2 (modified Pecs 1) interfascial blocks. This technique presents a novel and less invasive regional pain management approach. The ultrasound-guided depiction of the Pecs block was initially introduced by Blanco et al. for breast surgeries.<sup>[5]</sup> Since its initial introduction, the Pecs block has demonstrated positive outcomes across a diverse range of surgeries involving the chest wall. These procedures include radical mastectomies, breast-conserving surgeries, breast implant placements, Automated Implantable



Cardioverter-Defibrillator (AICD) and pacemaker insertions, intercostal drainage tube placements, and treatments for rib fractures. The Pecs block involves a two-plane approach. During the procedure, in the first injection, 0.2 ml/kg body weight of 0.25% bupivacaine with 5mg of dexamethasone is administered between the pectoralis major and pectoralis minor muscles (known as Pecs 1) under realtime USG guidance. Subsequently, in the second puncture, 0.2 ml/kg body weight of 0.25% bupivacaine with 5mg of dexamethasone is introduced between the pectoralis minor and the serratus anterior muscle (referred to as Pecs 2)<sup>5</sup>, specifically at the level of the fourth rib under realtime USG guidance. The primary objective of the Pecs 1 block is to anesthetize the medial and lateral pectoral nerves. In contrast, the Pecs 2 block aims to target the anterior divisions of the thoracic intercostal nerves spanning from T2 to T6, along with the long thoracic nerve and the thoracodorsal nerve. The lateral pectoral nerve typically originates from C5, C6, and C7, while the medial pectoral nerve arises from C8 and T1. The anterior divisions of the thoracic intercostal nerves from T2 to T6 are situated posteriorly between the pleura and the posterior intercostal membrane, running within a plane between the intercostal muscles all the way to the sternum. The long thoracic nerve, also known as the serratus anterior nerve, emerges from C5 to C7, entering the axilla behind the remainder of the brachial plexus and lying atop the serratus anterior muscle.<sup>5</sup>

## Objectives

The objective of the study was to investigate the effectiveness of bilateral pectoralis nerve block in cardiac surgery with regards to ultrafast tracking and postoperative pain management.

## MATERIAL AND METHODS

This was a quasi-experimental study and was conducted in the Department of Anaesthesia, Analgesia and Intensive care medicine of Bangabandhu Sheikh Mujib Medical University (BSMMU) Hospital, Dhaka, Bangladesh during the period from January 2023 to June 2023.

A total of forty adult patients between the age of 25-65 years undergoing CABG or valve possesses through midline sternotomy are included in the study. Patients were randomly allocated into two groups at 20 each. Group -A- received conventional analgesia with 1 gm paracetamol TDS with continuous intravenous infusion of 1 microgram per kg body weight of fentanyl. Group B received bilateral PEC block. Group B received ultrasound guided bilateral Pectoral Nerve (PEC) block with volume of 0.2 ml per kg body weight of 0.25% bupivacaine with 5 mg of dexamethasone for each interfascial plane post-operatively. Patients are extubated once they fulfill the extubation. In English, a semi-structured questionnaire was designed. The questionnaire was created using the variables that were chosen based on the specified aims. The questionnaire included questions on socio-demographic variables, as well as pre- and post-operative results. Data were collected through a questionnaire for visual analogue score and vital parameters such as heart rate, blood pressure, respiratory rate, duration on invasive ventilation at 0 hour, 02 hour, 04 hour, 08 hour and 12 hour post operatively. A checklist was also designed to record desirable information from the admission record, history sheet, and relevant medical documents. Data were reviewed promptly following the interview and examination of the appropriate investigation

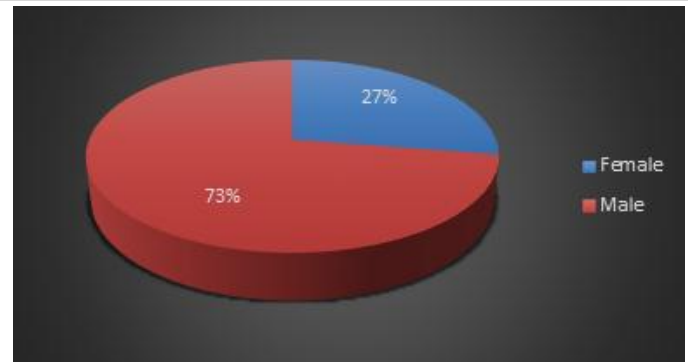
reports. All relevant data were acquired from each respondent using a predetermined interview schedule, measured parameters, and investigations. Participants who are scheduled for cardiac surgery for coronary artery bypass grafting via sternotomy, scheduled for mitral/aortic valve repair via sternotomy were included in the study. Patients with past history of allergy to local anesthesia, previous surgery, patients with known coagulopathy, preoperative critically ill, urgent operations should be excluded from the study.

**Statistical Analysis:** All data were recorded systematically in preformed data collection form and quantitative data was expressed as mean and standard deviation and qualitative data was expressed as frequency distribution and percentage. Statistical analysis was carried out by using Statistical analysis was done by using SPSS (Statistical Package for Social Science) Version 26 for windows 10. P value <0.05 was considered as statistically significant. Ethical clearance was obtained from Institutional Review Board (IRB) of BSMMU to undertake the current study.

## RESULTS

[Table 1] shows the Demographic Characteristics of the respondents. We found that there were no significant differences between Group A and Group B for age, height, weight, and BMI.

[Figure 1] shows that the respondents according to Sex, out of 40 respondents 73% were male and 27% were female.



**Figure 1:** Gender distribution of the respondents

Visual analogue score were significantly low in patients who received bilateral pectoralis nerve block (Group B) at 0, 2, 4, 8, and 12 h from post operatively ( $P < 0.05$ ). The pain scores progressively decreased in both groups over time.

There was no significant difference between the groups in the mean values of hemodynamic variables (blood pressure: BP, heart rate: HR) at six different assessment times. We also found that respiratory rate (RR) was significantly lower in group B than in group A at six assessment times ( $P < 0.005$ ).

[Table 4] shows the of postoperative parameters like duration of ventilator used (min), ICU stay (hours) and hospital stays (days) between group A and group B patients. The Mean duration of ventilator used in group A and B were  $112 \pm 10.85$  minutes and  $88 \pm 28$  minutes respectively which was statistically not significant. Mean duration of ICU stay of group A and B was  $80.25 \pm 8.45$  hours and  $60.55 \pm 9.26$  hours respectively. The differences between duration of ICU stay were statistically significant. Mean hospital stays of group A was



10.66 ± 2.34 days and group B was 9.45 ± 2. 22 days which was statistically not significant.

**Table 1:** Demographic Characteristics of the respondents

Variable	Group A	Group B	P value
Age	50.50±12.88	50.50±7.78	0.55
Height	154.50±2.5	151.50±4.95	0.72
Weight	65.25±13.18	62.80±6.64	0.24
BMI (kg/m <sup>2</sup> )	28±5	28±2	0.78

**Table 2:** Time course of visual analog scale (VAS) pain scores at rest

Time (h)	VAS rest		P value
	Group A	Group B	
VAS (0)	4.75±0.35	2.05±0.71	< 0.001
VAS (2)	3.75±1.06	1.5±0.77	< 0.001
VAS (4)	4.87±1.23	2±0.71	< 0.001
VAS (8)	4.24±1.35	2.5±1.28	< 0.001
VAS (12)	3.78±1.76	2.12±1.53	0.002

**Table 3:** Post-Operative Hemodynamic variables of the respondents

Time (h)	Blood Pressure, mmHg		P value	Heart Rate, beat/min		P value	Respiratory Rate, breath/min		P value
	Group A	Group B		Group A	Group B		Group A	Group B	
0	115.62 ± 23	115.59 ± 23	0.989	94.50 ± 19	90.68 ± 18	0.295	15 ± 12.65	11.6 ± 1.70	< 0.001
2nd	115.02 ± 15	115.89 ± 15	0.770	93 ± 14.8	90.84 ± 17	0.437	17 ± 12.90	13.2 ± 5.6	< 0.001
4th	113.8 ± 13.3	119.9 ± 24	0.300	93.80 ± 19.15	90.76 ± 17	0.344	18.70 ± 13.30	13.2 ± 3.45	< 0.001
8th	118 ± 12.7	121.17 ± 17.7	0.515	90.8 ± 17.9	85 ± 20.67	0.174	19.74 ± 11.76	15.4 ± 4.08	< 0.001
12th	116 ± 13.4	118 ± 15.6	0.523	85.40 ± 13.7	84.34 ± 18.8	0.728	20.52 ± 11.70	16 ± 3.77	0.004

**Table 4:** Post-Operative outcomes of the respondents

Post-operative outcomes	Group A	Group B	P value
Mean duration of ventilator used (min)	112±10.85	88±28	0.018
Mean duration of ICU stays (hours)	80.25 ± 8.45	60.55 ± 9.26	0.001
Mean hospital stays (days)	10.66 ± 2.34	9.45 ± 2. 22	0.08

## DISCUSSION

The use of ultrasound-guided Pecs block in chest wall surgeries for multimodal analgesia has seen a rapid increase in various medical

centers. However, effective regional anesthetic options for cardiac surgery are limited due to systemic heparinization during cardiopulmonary bypass and the risk of

postoperative hemodynamic instability. Severe postoperative pain can lead to complications such as reduced respiratory mechanics, limited mobility, and increased hormonal and metabolic activity, contributing to pulmonary issues, hypoxemia, myocardial ischemia, thromboembolism, delayed wound healing, and prolonged hospital stays. While neuraxial techniques are established in noncardiac thoracic surgery for superior analgesia, they are generally avoided in cardiac surgery due to the rare but severe risk of epidural hematoma. Paravertebral blockade is effective for chest wall analgesia but may require expertise and resources. In contrast, Pecs blockade is a relatively simple and safe fascial plane infiltration technique, previously used in breast surgery for chest wall analgesia. The current study applied bilateral Pecs block as part of multimodal analgesia in midline sternotomy patients undergoing cardiac surgery. Wahba and Kamal,<sup>[7]</sup> compared thoracic paravertebral block to Pecs block for analgesia after breast surgery and discovered that Pecs block performed prior to MRM resulted in less postoperative morphine consumption in the first 24 hours and lower pain intensity in the first 12 hours when compared to paravertebral block. Kulhari et al,<sup>[8]</sup> conducted a study comparing the effectiveness of Pecs block to thoracic paravertebral block for postoperative analgesia following radical mastectomy. Their findings indicated that the Pecs block proved to be a safe and efficient technique, offering superior pain relief when compared to thoracic paravertebral block. Additionally, the Pecs block resulted in a reduction in postoperative opioid consumption. In ELdeen's comparison between ultrasound-guided Pecs blockade and thoracic spinal blockade for conservative breast

surgery in breast cancer patients, the conclusion was drawn that the Pecs block stands out as a technically simple and easily learnable procedure with few contraindications. It was found to offer hemodynamic stability and demonstrate a low complication rate. Overall, ELdeen deemed the Pecs block a safe and effective technique for unilateral conservative breast surgery.<sup>[9]</sup> Results showed that patients receiving conventional analgesia with intravenous paracetamol 1 gm TDS and with continuous intravenous infusion of 1 microgram per kg body weight of fentanyl (Group A) had higher VAS scores during deep breathing or coughing compared to the Pecs block group (Group B), suggesting that Pecs block group (Group B) had lesser post operative pain than Group A. Group B also had significantly lower VAS scores postoperatively for nearly 12 hours, suggesting that USG guided bilateral PECS block efficiently managed postoperative pain in cardiac surgery through midline sternotomy.<sup>[10,11]</sup> Patients in Group B, experiencing superior analgesia, requiring a significantly shorter duration of ventilator support ( $88 \pm 28$  min) compared to the group A ( $112 \pm 10.85$  min) with a  $P < 0.0001$ . This indicates that patients in the PECS block group had a superior comfort profile compared to the conventional analgesia with paracetamol and fentanyl group.<sup>[12]</sup> Paracetamol has been studied in many surgical settings such as functional endoscopic sinus surgery, cholecystectomy, hysterectomy, and orthopedic surgeries with variable favorable results.<sup>[13,14]</sup> The direction of acetaminophen via a nasogastric tube or rectally after surgery is insufficient to accomplish an antipyretic plasma concentration (10 mg/ml); this was probably mainly because of late gastric emptying after

anesthesia and surgery.<sup>[15,16]</sup> In a study conducted by Cattabriga et al., they found that, in patients undertaking cardiac surgery, intravenous paracetamol delivers effective pain control.<sup>[17,18]</sup> Paracetamol has resulted in hypotension in critically ill patients although this effect could be explained as an allergic phenomenon.<sup>[19]</sup> The findings of the Apfel et al., systematic review study,<sup>[20]</sup> showed that the use of single-dose Paracetamol can reduce the amount of PONV in patients at least as much as antiemetic. The mechanism of this effect is not related to the reduction in the need for opioids and is a result of the reduction in pain intensity of patients (which self is a risk factor for PONV), and metabolism to AM404 in the brain (which inhibits the reuptake of anandamide).<sup>[21]</sup>

### Limitations of the study

Our study was a single centre study. We could only study a few adverse effects within a short study period. The main limitation of this study was the small sample size. Another limitation was short follow-up time.

### REFERENCES

1. Blanco R, Parras T, McDonnell JG, Prats-Galino A. Serratus plane block: a novel ultrasound-guided thoracic wall nerve block. *Anaesthesia*. 2013;68(11):1107-13. doi: 10.1111/anae.12344.
2. Kehlet H, Holte K. Effect of postoperative analgesia on surgical outcome. *Br J Anaesth*. 2001;87(1):62-72. doi: 10.1093/bja/87.1.62.
3. Cogan J. Pain management after cardiac surgery. *Semin Cardiothorac Vasc Anesth*. 2010;14(3):201-4. doi: 10.1177/1089253210378401.
4. Sacerdote P, Bianchi M, Gaspani L, Manfredi B, Maucione A, Terno G, et al. The effects of tramadol and morphine on immune responses and pain after surgery in cancer patients. *Anesth Analg*. 2000;90(6):1411-4. doi: 10.1097/0000539-200006000-00028.
5. Blanco R, Fajardo M, Parras Maldonado T. Ultrasound description of Pecs II (modified Pecs I): a novel approach to breast surgery. *Rev Esp Anesthesiol Reanim*. 2012;59(9):470-5. doi: 10.1016/j.redar.2012.07.003.
6. Khera T, Murugappan KR, Leibowitz A, Bareli N, Shankar P, Gilleland S, et al. Ultrasound-Guided Pecto-Intercostal Fascial Block for Postoperative Pain Management in Cardiac Surgery: A Prospective, Randomized, Placebo-Controlled Trial. *J Cardiothorac Vasc Anesth*. 2021;35(3):896-903. doi: 10.1053/j.jvca.2020.07.058.

### CONCLUSIONS

In conclusion, adult cardiac surgeries, especially those involving a medial sternotomy such as coronary artery bypass grafting, valve repair or replacement, often lead to postoperative pain and discomfort which if not managed adequately can cause haemodynamic instability and increased oxygen consumption. The effective management of pain is crucial for ensuring a speedy recovery and preventing harm to vital systems. The Pectoral Nerve (Pecs) block presents a less invasive and safe intervention for post operative pain control in adult cardiac surgeries. Initially developed for breast procedures, the Pecs block has proven its effectiveness across various chest surgeries. It not only provides significant pain relief but also mitigates risks associated with traditional methods like epidurals. This innovative approach addresses the limitations of conventional techniques and offers a targeted solution for the management of postoperative pain in adult cardiac surgeries such as CABG, valve replacement surgeries.



7. Wahba SS, Kamal SM. Thoracic paravertebral block versus pectoral nerve block for analgesia after breast surgery. *Egypt J Anaesth.* 2014;30:129-35.
8. Kulhari S, Bharti N, Bala I, Arora S, Singh G. Efficacy of pectoral nerve block versus thoracic paravertebral block for postoperative analgesia after radical mastectomy: A randomized controlled trial. *Br J Anaesth.* 2016;117:382-6.
9. ELdeen HM. Ultrasound guided pectoral nerve blockade versus thoracic spinal blockade for conservative breast surgery in cancer breast: A randomized controlled trial. *Egypt J Anaesth.* 2016;32:29-35.
10. Engoren M, Hadaway J, Schwann TA, Habib RH. Ketorolac improves graft patency after coronary artery bypass grafting: a propensity-matched analysis. *Ann Thorac Surg.* 2011;92(2):603-9.
11. Warner TD, Giuliano F, Vojnovic I, Bukasa A, Mitchell JA, Vane JR. Nonsteroid drug selectivities for cyclo-oxygenase-1 rather than cyclo-oxygenase-2 are associated with human gastrointestinal toxicity: a full in vitro analysis. *Proc Natl Acad Sci.* 1999;96(13):7563-8.
12. Funk CD, FitzGerald GA. COX-2 inhibitors and cardiovascular risk. *J Cardiovasc Pharmacol.* 2007;50(5):470-9.
13. Berger MM, Berger-Gryllaki M, Wiesel PH, Revelly JP, Hurni M, Cayeux C, et al. Intestinal absorption in patients after cardiac surgery. *Crit Care Med.* 2000;28(7):2217-23. doi: 10.1097/00003246-200007000-00006.
14. Arslan M, Celep B, Çiçek R, Kalender HÜ, Yılmaz H. Comparing the efficacy of preemptive intravenous paracetamol on the reducing effect of opioid usage in cholecystectomy. *J Res Med Sci.* 2013;18(3):172.
15. Bannwarth B, Netter P, Lopicque F, Gillet P, Péré P, Boccard E, et al. Plasma and cerebrospinal fluid concentrations of paracetamol after a single intravenous dose of propacetamol. *Br J Clin Pharmacol.* 1992;34(1):79-81. doi: 10.1111/j.1365-2125.1992.tb04112.x.
16. Jebaraj B, Maitra S, Baidya DK, Khanna P. Intravenous paracetamol reduces postoperative opioid consumption after orthopedic surgery: a systematic review of clinical trials. *Pain Res Treat.* 2013;2013:402510. doi: 10.1155/2013/402510.
17. Douzjian DJ, Kulik A. Old drug, new route: a systematic review of intravenous acetaminophen after adult cardiac surgery. *J Cardiothorac Vasc Anesth.* 2017;31(2):694-701. 31.
18. Cattabriga I, Pacini D, Lamazza G, Talarico F, Di Bartolomeo R, Grillone G, et al. Intravenous paracetamol as adjunctive treatment for postoperative pain after cardiac surgery: a double blind randomized controlled trial. *Eur J Cardiothorac Surg.* 2007;32(3):527-31. 32.
19. Józwiak-Bebenista M, Nowak JZ. Paracetamol: mechanism of action, applications and safety concern. *Acta Pol Pharm.* 2014;71(1):11-23.
20. Apfel CC, Turan A, Souza K, Pergolizzi J, Hornuss C. Intravenous acetaminophen reduces postoperative nausea and vomiting: a systematic review and meta-analysis. *Pain* 2013;154(5):677-89.
21. Choukèr A, Kaufmann I, Kreth S, Hauer D, Feuerecker M, Thieme D, et al. Motion sickness, stress and the endocannabinoid system. *PLoS One.* 2010;5(5):e10752. doi: 10.1371/journal.pone.0010752.

Source of Support: Nil, Conflict of Interest: None declared