



Clinical Analysis of Histopathological Diagnosis and Laparotomy Surgery Indications at A Tertiary Care Hospital

Asma Khatun¹, Tahmina Khatun², Shahinur Rahman³, Rahima Sultana⁴, Nazneen Rahman⁵, Md. Habibur Rahman⁶, Kazi Khadeza Farhin⁷, Farhana Hyder Chowdhury⁸

¹Assistant Professor, Department of Obstetrics and Gynaecology, Netrokona Medical College, Netrokona, Bangladesh

Email: dr.asmajolly@gmail.com,

Orcid ID: 0009-0003-2006-1230

²Medical officer, Department of Obstetrics and Gynaecology, Kurmitola General Hospital, Dhaka, Bangladesh

Email: drtahminapolly@gmail.com,

Orcid ID: 0009-0002-5002-3342

³Junior Consultant, Department of Obstetrics and Gynaecology, Kurmitola General Hospital, Dhaka, Bangladesh

Email: fahmed_farooque@yahoo.com,

Orcid ID: 0009-0001-3933-0811

⁴Junior Consultant, Department of Obstetrics and Gynaecology, Kurmitola General Hospital, Dhaka, Bangladesh,

Email: rahimaratna@gmail.com,

Orcid ID: 0009-0009-0755-6320

⁵Medical officer, Department of Obstetrics and Gynaecology, Kurmitola General Hospital, Dhaka, Bangladesh

Email: rbpuspa@gmail.com,

Orcid ID: 0000-0001-6084-5943

⁶Superintendent, Shariatpur 100 Bed Sadar Hospita, Shariatpur, Bangladesh

Email: dr.habib1987@gmail.com,

Orcid ID: 0009-0007-2309-0183

⁷Medical officer, Department of Obstetrics and Gynaecology, Kurmitola General Hospital, Dhaka, Bangladesh

Email: drkfarhin@gmail.com,

Orcid ID: 0009-0005-2593

⁸Medical officer, Department of Obstetrics and Gynaecology, Kurmitola General Hospital, Dhaka, Bangladesh

Email: farhanachowdhury82@yahoo.com,

Orcid ID: 0009-0008-7579-2889

*Corresponding author

Received: 02 August 2023

Revised: 10 September 2023

Accepted: 22 September 2023

Published: 31 October 2023

Abstract

Background: Laparotomy: Abdominal surgery for diagnosis (exploratory) or treatment (therapeutic), especially important for conditions like cancer staging and endometriosis. Clinical assessment crucial, especially in resource-limited settings. The aim of this study was to evaluate the histopathological diagnosis in informing laparotomy surgery indications at a tertiary care hospital.

Material & Methods: This was a cross-sectional study and was conducted in the Department of Obstetrics and Gynaecology of Sir Salimullah Medical College Mitford Hospital, Dhaka, Bangladesh during the period from May 2008 to April 2009. **Results:** In total 110 patients from female patient who were histopathologically diagnosed of oral cancer were included in the study. In our study we found mean age of patients was 37.55 ± 15.58 years. We found all patients had abdominal pain and the majority of the patients had 55% ovarian tumor. We found the majority 30% had benign ovarian tumor and 22% had malignant ovarian tumor and histopathological findings. Out of all patients 31.0% had malignant ovarian tumor, 21.0% had benign ovarian tumor respectively. **Conclusion:** Laparotomy is a vital surgical procedure for both diagnosis and treatment of abdominal conditions. Properly chosen and performed, it can be life-saving and greatly enhance patients' quality of life.

Keywords:- Histopathological diagnosis, Indication, laparotomy.



INTRODUCTION

Laparotomy is a surgical procedure involving an incision through the abdominal wall to gain access into the abdominal cavity. It is also known as coeliotomy. It is used to visualize and examine the structures inside the abdominal cavity.^[1,2] In diagnostic laparotomy (most often referred to as an exploratory), the nature of the disease is unknown and laparotomy is deemed the best way to identify the cause. In therapeutic laparoscopy, a cause has been identified (e.g. cancer of ovary) and laparotomy is required for its therapy.^[3,4] The procedure may be recommended for a patient who has abdominal pain of unknown origin or has sustained an injury to the abdomen. In addition, bleeding into the abdominal cavity is considered a medical emergency. Exploratory laparotomy is used to determine the source of pain or the extent of injury and perform repair if needed.^[5,6,7] The laparotomy may be performed to determine the cause of a patient's symptoms or to establish the extent of the disease.^[2] For example, in endometriosis exploratory laparotomy may be used to examine the abdominal and pelvic organs (such as ovaries, fallopian tubes, urinary bladder and rectum) for the evidence of disease. Any growth found may then be removed. Exploratory laparotomy also plays an important role in the staging of certain malignancies like ovarian cancers. Cancer staging is used to describe how far a cancer has spread.^[8] A laparotomy enables a surgeon to directly examine the abdominal organs for evidence of cancer and remove samples of tissue for further examination. When laparotomy is used for this purpose, it is called staging laparotomy or pathological staging.^[9] Cancer of the following any operative

procedure, ruptured uterus, septic abortion, infection of female genital tract-a second laparotomy to drain residual abscess, twisted ovarian cyst, salpingitis, missing IUCD may be investigated by laparotomy.^[10,11,12] Laparotomy however must never be done without proper indication. In properly selected cases laparotomy as already been proved is a lifesaving procedure and unique in improving the quality of life of women and therefore the choice of treatment.^[13,14,15]

In our country, laparotomy is performed for more or less similar indications as those performed in advanced countries. We have to diagnose the cases more on the clinical ground rather than modern investigations because of limited facilities and economic constraint. Most of our patients are illiterate, ignorant and poor. They often attend the doctor late and cannot explain their problems properly. As a result their findings often do not correlate with their complaints. The results following laparotomy depend on the reasons why it was performed. The procedure may indicate that further treatment is necessary, for example if cancer was detected chemotherapy, radiotherapy, or more surgery may be recommended. In some cases the abnormality is able to be treated during laparotomy and no further treatment is necessary.

Objectives

The main objective of the study was to evaluate the histopathological diagnosis in laparotomy surgery indications at a tertiary care hospital.

MATERIAL AND METHODS

This was a cross-sectional study and was conducted in the Department of Obstetrics and

Gynaecology of Sir Salimullah Medical College Mitford Hospital, Dhaka, Bangladesh during the period from May 2008 to April 2009.

A total of 100 patients were included in the study. Female patient who were histopathologically diagnosed were included in the study. Data regarding the patient's age, symptoms, clinical diagnosis, per operative findings, histological findings. All patients were selected consecutively after considering inclusion and exclusion criteria. The patients unwilling to give informed consent were excluded in the study.

Statistical Analysis: All data were recorded systematically in preformed data collection form and quantitative data was expressed as mean and standard deviation and qualitative data was expressed as frequency distribution and percentage. Statistical analysis was performed by using SPSS (Statistical Package for Social Sciences) for windows version 10. 95% confidence limit was taken. The patients unwilling to give informed consent were excluded in the study.

RESULTS

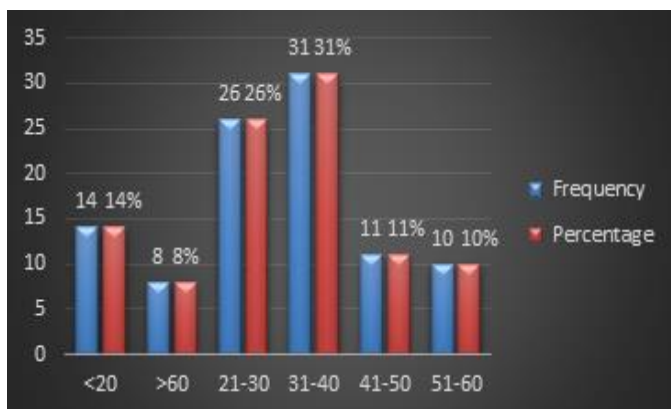


Figure 1: Distribution of the respondents by age

[Figure 1] shows the age distribution of the patients. Out of all respondents maximum 31.0% were within 31 to 40 years age group followed by 26.0% within 21 to 30 years, 14.0% up to 20 years, 11.0% within 41 to 50 years, 10.0% 51 to 60 years and 8.0% above 60 years age range. Mean (SD) age of patients was 37.55±15.58 years. All patients were within 17 to 75 years age range.

[Table 1] shows the different presenting features of the patients. All patients of the present study had abdominal pain, 65.0% had abdominal lump, 13.0% had urinary or bowel complaints, 12.0% had vaginal discharge, 10.0% had dysmenorrhoea, 9.0% had menorrhagia, 3.0% had dyspareunia and 3.0% had irregular bleeding.

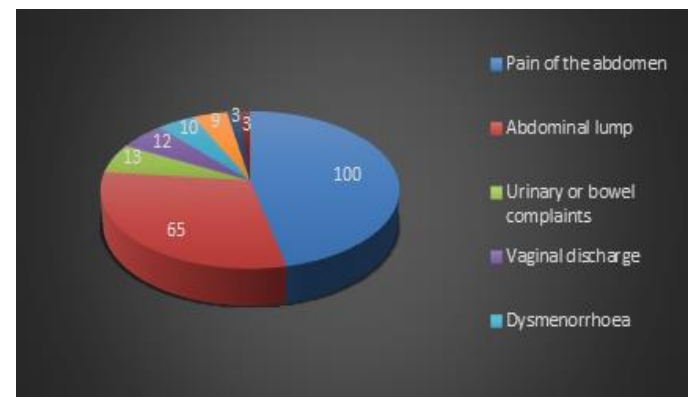


Figure 2: Distribution of the respondents by symptoms

Before laparotomy all patients were diagnosed clinically. Table shows the clinical diagnosis of the patients. Out of all patients 55.0% had ovarian tumor, 13.0% had twisted ovarian cyst, 10.0% had ectopic pregnancy, 7.0% ovarian cyst, 7.0% had tubo ovarian mass, 5.0% endometriosis and 3.0% ruptured uterus. [Table 2]

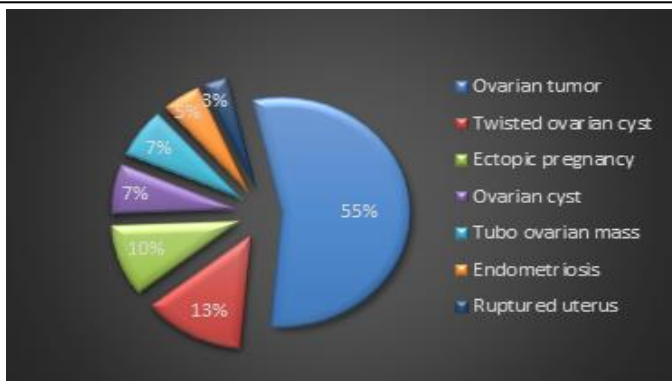


Figure 3: Distribution of the respondents by clinical diagnosis for laparotomy indications

[Table 3] shows the per operative findings of the patients. Out of all patients of present study

30.0% had benign ovarian tumour, 22.0% had malignant ovarian tumor, 17.0% ruptured ectopic pregnancy, 9.0% had bilateral chocolate cyst, 4.0% had ovarian cyst, rests 9.0%, 3.0% of each had hydrosalpinx. Ruptured uterus, and Subserous pedunculated fibroid respectively.

[Table 4] shows the different types of histopathological findings. Out of all patients 31.0% had malignant ovarian tumor, 21.0% had benign ovarian tumor, 17.0% had ectopic pregnancy, 13.0% had ovarian cyst, 9.0% had endometriosis, and rests 9.0% had ruptured uterus, chronic salphingo- oophoritis, and fibroid uterus.

Table 1: Distribution of the respondents by symptoms.

Symptoms	Frequency	Percentage
Pain of the abdomen	100	100
Abdominal lump	65	65
Urinary or bowel complaints	13	13
Vaginal discharge	12	12
Dysmenorrhoea	10	10
Menorrhagia	9	9
Dyspareunia	3	3
Irregular bleeding	3	3

Table 2: Distribution of the respondents by clinical diagnosis for laparotomy indications (n=100)

Clinical diagnosis	Frequency	Percentage
Ovarian tumor	55	55
Twisted ovarian cyst	13	13
Ectopic pregnancy	10	10
Ovarian cyst	7	7
Tubo ovarian mass	7	7
Endometriosis	5	5
Ruptured uterus	3	3

Table 3: Distribution of the respondents by indications of Pre operative findings

Pre operative findings	Frequency	Percentage
Benign ovarian tumor	30	30
Malignant ovarian tumor	22	22

Ruputed ectopic pregnancy	17	17
Twisted ovarian cyst	9	9
Bilateral chocolate cyst	9	9
Ovarian cyst	4	4
Hydrosalpinx	3	3
Ruptured uterus	3	3
Subserous pedunculated fibroid	3	3

Table 4: Distribution of the respondents by indications of Histopathology findings

Histopathology findings	Frequency	Percentage
Malignant ovarian tumor	31	31
Benign ovarian tumor	21	21
Ectopic pregnancy	17	17
Ovarian cyst	13	13
Endometriosis	9	9
Ruptured uterus	3	3
Ch. Salphingo-oophoritis	3	3
Fibroid uterus	3	3

DISCUSSION

A laparotomy is performed under general anaesthesia. The surgeon makes a large, single cut through the skin and muscle of the abdomen, so that the underlying organs can be clearly viewed. The exposed organs are then carefully examined. Once diagnosed, the problem may be fixed on the spot (for example, a perforated bowel may be repaired).

This cross sectional study was conducted from 1st May 2008 to 30th April 2009 for duration of one year with an aim to find out the clinical presentation, per-operative and histopathological findings. Women with acute Gynaecological and Obstetric emergency who admitted for surgical management in the Department of Obstetrics and Gynaecology, Sir Salimullah Medical College & Mitford Hospital, Dhaka were enrolled in this study. Purposively collected total 100 admitted patients of 17 to 75

years age group were evaluated for this study. Mean age of the study group was 37.55 (+ 15.58) years. Out of all respondents maximum 31.0% were within 21 to 30 years age group which was comparable with Ali and Shah (2007) series and some other studies where 16 to 25 years of age women were the commonest sufferer (Brown 1988; Muir and Belsey 1980; Rushwan 1980).^[16,17,18,19] In Ali and Shah (2007) series the age group between 16 to 30 years was the commonest having gynaecological problems. 16 In the present series before laparotomy all patients were diagnosed clinically. Of them 55.0% had clinical suspicion of ovarian tumour, 13.0% had twisted ovarian cyst, 10.0% had ectopic pregnancy, 7.0% ovarian cyst, 7.0% had tubo ovarian mass, 5.0% endometriosis and 3.0% ruptured uterus. Per operatively 30.0% had benign ovarian tumor, 22.0% had malignant ovarian tumor, 17.0% ruptured ectopic pregnancy, 9.0% had bilateral chocolate

cyst, 4.0% had ovarian cyst, rests 9.0 %, 3.0% of each had hydrosalpinx, Ruptured uterus, and Subserous pedunculated fibroid respectively. After operation all specimen sent for histopathology. Out of all patients 31.0% had malignant ovarian tumor, 21.0% had benign ovarian tumor, 17.0% had ectopic pregnancy, 13.0% had ovarian cyst, 9.0% had endometriosis, and rests 9.0% had ruptured uterus, chronic salphingo-oophoritis, and fibroid uterus. In Ali and Shah (2007) series PID was the most common (40.90%) emergency followed by ruptured functional ovarian cyst (20.45%) and uterine perforation (18.8%) while adnexal torsion was the least common (6.81%).¹⁶ In a study Tayyiba et al (2009) compared clinical presentations of Benign and Malignant Ovarian Tumors of 110 cases, of whom 80 (72%) had benign and the rest malignant disease. Mean age of patients with malignancy was 49.07±18.5 years and for benign 36.95±8.2 years. In our series mean age was 39.55(+15.0) and 47.43(+23.39) years respectively for malignant and benign ovarian tumor.^[20] Eleven patients with benign tumors in Tayyiba et al (2009) series were asymptomatic, while 66% had abdominal pain. On the other hand 70% patients with ovarian malignancy had abdominal symptoms with abdominal pain in (76%). Abdominal enlargement and abdominal mass were significantly more in malignant tumors. Gastrointestinal symptoms were present in both groups but more significant in malignant group (p=0.004). Constitutional symptoms like loss of appetite and weight loss were only present in malignant group (p=0.001). Seventy percent of the malignant tumors presented at late stage (11 &

IV). Histopathology of benign tumors revealed follicular/luteal cyst in 32% cases while serous cyst adenoma in 23%. Histopathology of malignant tumors

Limitations of the study

Our study was a single centre study. We had many limitations. The study was conducted over a one-year period from May 2008 to April 2009. This relatively short time frame might not capture seasonal variations or long-term trends in the clinical presentation of gynecological and obstetric emergencies. The study does not provide detailed information about the clinical presentation of patients, such as specific symptoms or physical examination findings. More detailed clinical data could have enhanced the understanding of the conditions studied.

CONCLUSIONS

Laparotomy is a flexible surgical technique having both diagnostic and therapeutic uses. It is a crucial tool for identifying and treating a wide range of abdominal conditions, from unexplained abdominal pain to severe injuries and emergencies. Laparotomy's significance extends to the diagnosis and staging of diseases such as ovarian cancer and endometriosis. However, it is essential to emphasize that laparotomy should only be performed when medically indicated, and careful patient selection is paramount. When used judiciously, laparotomy has proven to be a lifesaving procedure that significantly improves the quality of life for patients, particularly women.



REFERENCES

- Schachtrupp A, Fackeldey V, Klinge U, Hoer J, Tittel A, Toens C, et al. Temporary closure of the abdominal wall (laparostomy). *Hernia*. 2002;6(4):155-62. doi: 10.1007/s10029-002-0085-x.
- Jernigan TW, Fabian TC, Croce MA, Moore N, Pritchard FE, Minard G, et al. Staged management of giant abdominal wall defects: acute and long-term results. *Ann Surg*. 2003;238(3):349-55; discussion 355-7. doi: 10.1097/01.sla.0000086544.42647.84.
- Schrenk P, Woisetschläger R, Wayand WU, Rieger R, Sulzbacher H. Diagnostic laparoscopy: a survey of 92 patients. *Am J Surg*. 1994;168(4):348-51. doi: 10.1016/s0002-9610(05)80163-1.
- Udwadia TE, Udwadia RT, Menon K, Kaul P, Kukreja L, Jain R, et al. Laparoscopic surgery in the developing world. An overview of the Indian scene. *Int Surg*. 1995;80:371-5.
- Easter DW, Cuschieri A, Nathanmn LK, Lavelle-Joncs M. The utility of diagnostic laparoscopy for abdominal disorders. *Arch Sm'g*. 1992;127:379-383.
- Nar AS, Bawa A, Mishra A, Mittal A. Role of diagnostic laparoscopy in chronic abdominal conditions with uncertain diagnosis. *Niger J Surg*. 2014;20(2):75-8. doi: 10.4103/1117-6806.137301.
- Al-Akeely MH. The impact of elective diagnostic laparoscopy in chronic abdominal disorders. *Saudi J Gastroenterol*. 2006;12(1):27-30. doi: 10.4103/1319-3767.27741.
- Bateman BG, Kolp LA, Mills S. Endoscopic versus laparotomy management of endometriomas. *Fertil Steril*. 1994;62: 690-5.
- Yuen PM, Lo KWK, Rogers M. A comparison of laparotomy and laparoscopy in the management of ovarian masses. *J Gynecol Surg*. 1995;1:19-25.
- Sackier J. Diagnostic laparoscopy in nonmalignant disease. *Smg Clin North Am*. 1992;72:1033-1043.
- Howard FM. Surgical management of benign cystic teratoma: laparoscopy vs. laparotomy. *J Reprod Med*. 1995;40:495-9.
- Lin P, Ealcone T, Tulandi T. Excision of ovarian dermoid cyst by laparoscopy and by laparotomy. *Am J Obstet Gynec*. 1995;173:769-71
- Mais V, Ajossa S, Piras B, Marongiu D, Guerriero S, Melis GB. Treatment of nonendometriotic benign adnexal cysts: a randomized comparison of laparoscopy and laparotomy. *Obstet Gynecol*. 1995;86:770-4
- Berci G. Elective and emergent I: tparoscopy. *World, I Sttrg*. 1993;17:8-15.
- Cuschicri A. The spectrum of laparoscopic surgm 7. *World I Sttrg*. 1992;16:1089-1097.
- Ali S, Shah STA. Gynaecological Emergencies. *Professional Med J*. 2007;14(1):43-9
- Brown SP, Eckersley JRT, Dudley HAF. The gynaecological profile of acute general surgery JR. *Coll Surg*. 1988;33:13-15
- Muir DG, Belsey MA. Pelvic inflammatory disease and its consequences in developing worlds. *Am. J. Obstet Gynaecol*. 1980;138(7)913-28.
- Rushwan H. Etiologic factors in Pelvic inflammatory disease in Sudanese women: *Am. J. Obstet Gynaecol*. 1980,138-877-9.
- Wasim T, Majrroh A, Siddiq S. Comparison of clinical presentation of benign and malignant ovarian tumours. *J Pak Med Assoc*. 2009;59(1):18-21.

Source of Support: Nil, Conflict of Interest: None declare