



Echocardiographic Wall Motion Abnormalities in Hypertensive Patients with Electrocardiographic Left Ventricular Hypertrophy

Hemanta I Gomes^{1*}, CM Shaheen Kabir², Syed Dawood Md. Taimur³, Md. Javed Iqbal⁴

¹Assistant Professor, Cardiology, Ibrahim Cardiac Hospital & Research Institute, Dhaka, Bangladesh.

Email: hemig67@gmail.com

Orcid ID: 0000-0001-7871-6250

²Associate Professor, Cardiology, Ibrahim Cardiac Hospital & Research Institute, Dhaka, Bangladesh.

Email: skabir67@yahoo.com

Orcid ID: 0000-0003-4155-1290

³Assistant Professor, Cardiology, Ibrahim Cardiac Hospital & Research Institute, Dhaka, Bangladesh.

Email: sdmmtaimur@gmail.com,

Orcid ID: 0000-0001-7871-6250

⁴Assistant Professor, Cardiology, Ibrahim Cardiac Hospital & Research Institute, Dhaka, Bangladesh.

Email: dr.javed.iqbal@gmail.com

Orcid ID: 0000-0001-7871-6250

*Corresponding author

Received: 06 August 2022

Revised: 26 September 2022

Accepted: 08 October 2022

Published: 22 October 2022

Abstract

Background: During the cardiac cycle with the effect on cardiac function, Echocardiographic wall motion abnormalities are kinetic alterations in the cardiac wall motion. It can be characterized as per their grades and their distribution pattern like segmental or global. It can be attributed to a coronary territory or follow a non-coronary distribution. **Aim of the study:** The aim of the study was to evaluate the patterns of echocardiographic wall motion abnormalities among hypertensive patients with electrocardiographic left ventricular hypertrophy. **Material & Methods:** This was prospective observational study which was conducted in the Department of Cardiology, Ibrahim Cardiac Hospital & Research Institute, Dhaka, Bangladesh from January 2020 to January 2021. In total 76 hypertensive patients with electrocardiographic left ventricular hypertrophy were included as the study subjects for this study. This study was approved by the ethical committee of the mentioned hospital. A predesigned questioner was used in data collection. All data were collected, processed and analyzed by using MS Office and SPSS version 23 programs as per necessity. **Results:** In this study, in analyzing the status of wall motion abnormalities (WMA) among the participants we observed that, 22% of the patients were with segmental wall motion abnormalities, 18% were with global dysfunction and 59% were fully free from any type of WMA. Among patients with global dysfunctions, 71% were with mild and 12% were with moderate-to-severe dysfunction whereas this ratio was 47:24 in segmental abnormality patients. On the other hand, in analyzing the severity and location of patients with segmental WMA we observed that 47%, 24%, 53%, 41%, 18%, 24%, 29%, 47%, 35%, 53% and 41% were with mild dysfunction, moderate-to-severe dysfunction, inferior wall dysfunction, antero-septal dysfunction, anterior wall dysfunction, lateral wall dysfunction, posterior wall dysfunction, posterior septal dysfunction, LV base dysfunction, LV mid-cavity dysfunction and LV apical dysfunction respectively. **Conclusion:** In this study, majority of the participants were found free from any type of wall motion abnormality. 'Mild dysfunction', inferior wall dysfunction, anterior wall dysfunction, lateral wall dysfunction, posterior septal dysfunction, LV base dysfunction, LV mid-cavity dysfunction and LV apical dysfunction are found as some more frequent dysfunctions among patients with WMA.

Keywords:- Echocardiographic, Wall motion abnormalities, Hypertension, Left ventricular hypertrophy.



INTRODUCTION

Echocardiographic wall motion abnormalities are kinetic alterations in the cardiac wall motion during the cardiac cycle with an effect on cardiac function. Left ventricular hypertrophy, valvular heart disease, enlarged left atrium, and wall motion abnormalities can also be major causes of heart failure and are related to CAD (coronary artery disease).^[1] Echocardiography is the gold standard for diagnosing cardiac dysfunction associated with heart failure and can be used to detect other cardiac abnormalities.^[2,3] Myocardial infarction (MI) or severe ischemia are the most common causes of left ventricular wall motion abnormalities which can reduce the LV pump function.^[4] Information regarding the prevalence and correlation of WM abnormalities in ambulatory high-risk hypertensive patients is limited.^[5] Hypertension is a major determinant of LVF (left ventricular hypertrophy) and is associated with the increased risk of left ventricular systolic dysfunction.^[6] Global left ventricular EF (ejection fraction), a measure of left ventricular chamber function highly useful as an indicator of the left ventricular systolic dysfunction and that can be normal despite segmental wall motion abnormalities, especially when ejection fraction is measured from the linear echocardiographic left ventricular dimensions at mid-cavity level or from single-plane contrast ventriculograms.^[7] Two-dimensional echocardiography allows semiquantitative evaluation of the wall motion abnormalities which are pathophysiologically associated with CHD (coronary heart disease).^[4,8,9] For measuring the wall motion abnormalities, the wall motion score index (WMSI) is a simple method to quantify global and regional systolic

function and has been shown to be an accurate estimate of left ventricular ejection fraction.^[10,11] Wall motion score index is an independent predictor of outcomes following STEMI and non-STEMI.^[12] This study was conducted to evaluate the patterns of echocardiographic wall motion abnormalities among hypertensive patients with electrocardiographic left ventricular hypertrophy.

MATERIAL AND METHODS

This prospective observational study was conducted in the Department of Cardiology, Ibrahim Cardiac Hospital & Research Institute, Dhaka, Bangladesh from January 2020 to January 2021. In total 76 hypertensive patients with electrocardiographic left ventricular hypertrophy were included as the study subjects for this study. This study was approved by the ethical committee of the mentioned hospital. The total intervention was conducted in accordance with the principles of human research specified in the Helsinki Declaration and executed in compliance with currently applicable regulations and the provisions of the General Data Protection Regulation (GDPR).^[13,14,15] As per the inclusion criteria of this study, only hypertensive patients of several ages with hypertension were included. On the other hand, as per the exclusion criteria, patients with electrocardiographic left ventricular hypertrophy were included as the study subjects. On the other hand, cases with intraventricular conduction disturbances or congenital heart disease, rheumatic heart disease, cardiomyopathy, patients on permanent pacemaker (PPM), using drugs like verapamil, right ventricular hypertrophy and patients who did not consent for the study were excluded. All necessary data regarding clinical

and demographic status, comorbidities, risk factors, histories and echocardiographic findings were recorded and analyzed. A predesigned questioner was used in data collection. All data were collected, processed and analyzed by using MS Office and SPSS version 23 programs as per necessity.

RESULTS

In this current study, among total 76 participants, 62% were male and the rest 38% were female. So male participants were dominant in number and the male-female ratio was 1.6:1. (Table 1) The mean (\pm SD) systolic BP (mm Hg), diastolic BP (mm Hg), and heart rate (bpm) of the participants were found as 173.37 ± 33.38 , 97.67 ± 19.61 and 82.37 ± 8.78 respectively. (Table 1) On the other hand, the mean (\pm SD) total cholesterol, mg/dL, and HDL cholesterol, mg/dL of the participants were 231.65 ± 31.78 and 67.94 ± 28.77 respectively. (Table 1) Among the total participants, 30(40%), 24(32%), 20(26%), and 2(2%) were with clinical CVD, diabetes, CHD, and MI respectively as the comorbidities and/or risk factors. (Figure I) In this study, in analyzing the status of wall motion abnormalities (WMA) among the participants we observed that 45(59%) were fully free from any type of WMA, 17(23%) of the patients were with segmental wall motion abnormalities, 14(18%) were with global

dysfunction and. (Table 2) On the other hand, in analyzing the severity and location of patients with segmental WMA we observed that 53%, 53% 47%, 47%, 41%, 41% 35%, 29%, 24%, and 18% were with Inferior wall dysfunction, LV mid-cavity dysfunction, mild dysfunction, Posterior septal dysfunction, Antero-septal dysfunction, LV apical dysfunction, LV base dysfunction, Posterior wall dysfunction, moderate-to-severe dysfunction, Lateral wall dysfunction and inferior wall dysfunction, anteroseptal dysfunction, anterior wall dysfunction respectively. (Table 3) Among patients with global dysfunctions, 54(71%) were with mild and 22(29%) were with moderate-to-severe dysfunction whereas this ratio was 47:24 in segmental abnormality patients.

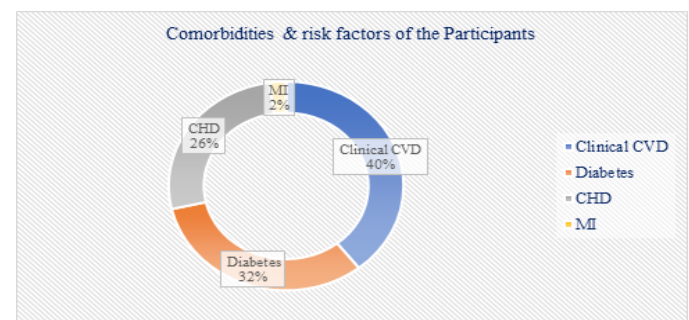


Figure I: Comorbidities & risk factors of the Participants (N=76)

Table 1: Demographic and clinical status of participants (N=76)

Demographic and clinical status	Frequency (%)	Mean \pm SD
Sex		
Male	47(62%)	
Female	29(38%)	
Male Female Ratio		
Male:Female	1.6:1	
BMI, kg/m ²		27.18 \pm 3.66



Age in year (Mean \pm SD)		63.63 \pm 7.39
BP and heart rate		
Systolic BP (mm Hg)		173.37 \pm 33.38
Diastolic BP (mm Hg)		97.67 \pm 19.61
Heart rate (bpm)		82.37 \pm 8.78
Lipid status		
Total Cholesterol (mg/dL)		231.65 \pm 31.78
HDL Cholesterol (mg/dL)		67.94 \pm 28.77
Comorbidities & risk factors		
Clinical CVD	30(40%)	
Diabetes	24(32%)	
CHD	20(26%)	
MI	2(2%)	

Table 2: Status of wall motion abnormalities (WMA) among participants (N=76)

Characteristics	n	%
Free from WMA	45	59%
Segmental abnormalities	17	23%
Global abnormalities	14	18%

Table 3: Severity and location of segmental WMA among participants (N=76)

Characteristics	n	%
Inferior wall dysfunction	9	53%
LV mid-cavity dysfunction	9	53%
Mild dysfunction	8	47%
Posterior septal dysfunction	8	47%
Antero-septal dysfunction	7	41%
LV apical dysfunction	7	41%
LV base dysfunction	6	35%
Posterior wall dysfunction	5	29%
Moderate-to-severe dysfunction	4	24%
Lateral wall dysfunction	4	24%
Anterior wall dysfunction	3	18%

Table 4: Severity and location of global WMA among participants (N=76)

Characteristics	n	%
Mild dysfunction	54	71%
Moderate-to-severe dysfunction	22	29%

DISCUSSION

The study aimed to evaluate the patterns of echocardiographic wall motion abnormalities among hypertensive patients with electrocardiographic left ventricular hypertrophy. In this study, in analyzing the status of wall motion abnormalities (WMA) among the participants we observed that 22% of the patients were with segmental wall motion abnormalities, 18% were with global dysfunction and 59% were fully free from any type of WMA. On the other hand, in analyzing the severity and location of patients with segmental WMA we observed that 53%, 53% 47%, 47%, 41%, 41% 35%, 29%, 24%, and 18% were with Inferior wall dysfunction, LV mid-cavity dysfunction, mild dysfunction, Posterior septal dysfunction, Antero-septal dysfunction, LV apical dysfunction, LV base dysfunction, Posterior wall dysfunction, moderate-to-severe dysfunction, Lateral wall dysfunction and inferior wall dysfunction, anteroseptal dysfunction, anterior wall dysfunction respectively. In a cardiovascular health study, 12.5% prevalence of LV wall motion abnormalities (WMA) was found and in the LIFE echo, sub-study patients were nearly 3 times higher than the 4.3% reported among hypertensive adult patients.^[5] One most potential explanation was the selection of subjects with ECG left ventricular hypertrophy for LIFE, in view of the known association of higher LV mass with CHD,^[15,16] MI (myocardial infarction), and larger myocardial infarction

size.^[17,18] Among patients with global dysfunctions, 71% were with mild and 29% were with moderate-to-severe dysfunction. Besides these, a good number of segmental abnormality patients with inferior wall dysfunction, anterior septal dysfunction, posterior septal dysfunction, LV base dysfunction, LV mid-cavity dysfunction, and LV apical dysfunction. Segmental wall motion abnormalities (WMA) can be related to subclinical coronary artery disease.^[4] Up to one-third of acute MI can be clinically silent; [19, 20] up to 30% of acute MI never manifest diagnostic Q waves; a diagnostic Q wave disappears in 10% to 30% of Q-wave infarctions^[21] or is not diagnosed 2 years after an acute MI.^[22] Therefore, silent ischemia Myocardial infarction or chronic ischemia, or hibernating myocardium may cause wall motion abnormalities at rest. Although mild hypokinesia may be a normal variant,^[23] hypokinesia is strongly associated with significant CHD.^[4] All the findings of this study may be helpful in the treatment arena of WMA and in further similar studies.

Limitations of the Study

This was a single-centered study with a small-sized. The present study was conducted at a very short period of time. So, the results of this study may not reflect the exact picture of the whole country.



CONCLUSIONS

In this study, majority of the participants were found free from any type of wall motion abnormality. 'Mild dysfunction', inferior wall dysfunction, anterior wall dysfunction, lateral wall dysfunction, posterior septal dysfunction,

LV base dysfunction, LV mid-cavity dysfunction and LV apical dysfunction are found as some more frequent dysfunctions among patients with WMA. For getting more specific findings we would like to recommend conducting more studies with larger-sized sized samples in several places.

REFERENCES

1. Leung DY, Chi C, Allman C, Boyd A, Ng AC, Kadappu KK, et al. Prognostic implications of left atrial volume index in patients in sinus rhythm. *Am J Cardiol.* 2010;105(11):1635-9. DOI: 10.1016/j.amjcard.2010.01.027.
2. Hunt SA, Abraham WT, Chin MH, Feldman AM, Francis GS, Ganiats TG, et al. 2009 focused update incorporated into the ACC/AHA 2005 Guidelines for the Diagnosis and Management of Heart Failure in Adults: a report of the American College of Cardiology Foundation/American Heart Association Task Force on Practice Guidelines: developed in collaboration with the International Society for Heart and Lung Transplantation. *Circulation.* 2009;119(14):e391-479. DOI: 10.1161/CIRCULATIONAHA.109.192065.
3. Aronow WS, Fleg JL, Pepine CJ, Artinian NT, Bakris G, Brown AS, et al. ACCF/AHA 2011 expert consensus document on hypertension in the elderly: a report of the American College of Cardiology Foundation Task Force on Clinical Expert Consensus Documents. *Circulation.* 2011;123(21):2434-506. DOI: 10.1161/CIR.0b013e31821daaf6.
4. Lewis SJ, Sawada SG, Ryan T, Segar DS, Armstrong WF, Feigenbaum H. Segmental wall motion abnormalities in the absence of clinically documented myocardial infarction: clinical significance and evidence of hibernating myocardium. *Am Heart J.* 1991;121(4 Pt 1):1088-94. DOI: 10.1016/0002-8703(91)90666-6.
5. Gardin JM, Siscovick D, Anton-Culver H, Lynch JC, Smith VE, Klopfenstein HS, et al. Sex, age, and disease affect echocardiographic left ventricular mass and systolic function in the free-living elderly. The Cardiovascular Health Study. *Circulation.* 1995;91(6):1739-48 DOI: 10.1161/01.cir.91.6.1739.
6. Devereux RB, Bella JN, Palmieri V, Oberman A, Kitzman DW, Hopkins PN, et al. Left ventricular systolic dysfunction in a biracial sample of hypertensive adults: The Hypertension Genetic Epidemiology Network (HyperGEN) Study. *Hypertension.* 2001;38(3):417-23. DOI: 10.1161/01.hyp.38.3.417.
7. Teichholz LE, Kreulen T, Herman MV, Gorlin R. Problems in echocardiographic volume determinations: echocardiographic-angiographic correlations in the presence of absence of asynergy. *Am J Cardiol.* 1976;37(1):7-11. DOI: 10.1016/0002-9149(76)90491-4.
8. Kisslo JA, Robertson D, Gilbert BW, von Ramm O, Behar VS. A comparison of real-time, two-dimensional echocardiography and cine angiography in detecting left ventricular asynergy. *Circulation.* 1977;55(1):134-41. DOI: 10.1161/01.cir.55.1.134.
9. Freeman AP, Giles RW, Walsh WF, Fisher R, Murray IP, Wilcken DE. Regional left ventricular wall motion assessment: comparison of two-dimensional echocardiography and radionuclide angiography with contrast angiography in healed myocardial infarction. *Am J Cardiol.* 1985;56(1):8-12. DOI: 10.1016/0002-9149(85)90556-9.
10. Lang RM, Badano LP, Mor-Avi V, Afilalo J, Armstrong A, Ernande L, et al. Recommendations for cardiac chamber quantification by echocardiography in adults: an update from the American Society of Echocardiography and the European Association of Cardiovascular Imaging. *J Am Soc Echocardiogr.* 2015;28(1):1-39.e14. DOI: 10.1016/j.echo.2014.10.003.
11. McGowan JH, Cleland JG. Reliability of reporting left ventricular systolic function by echocardiography: a systematic review of 3 methods. *Am Heart J.*



- 2003;146(3):388-97. DOI: 10.1016/S0002-8703(03)00248-5.
12. Møller JE, Hillis GS, Oh JK, Reeder GS, Gersh BJ, Pellikka PA. Wall motion score index and ejection fraction for risk stratification after acute myocardial infarction. *Am Heart J.* 2006;151(2):419-25. DOI: 10.1016/j.ahj.2005.03.042.
13. World Medical Association. World Medical Association Declaration of Helsinki: ethical principles for medical research involving human subjects. *JAMA.* 2013;310(20):2191-4. doi: 10.1001/jama.2013.281053.
14. Marovic B, Curcin V. Impact of the European General Data Protection Regulation (GDPR) on Health Data Management in a European Union Candidate Country: A Case Study of Serbia. *JMIR Med Inform.* 2020;8(4):e14604. DOI: 10.2196/14604.
15. Pech HJ, Witte J, Romaniuk R, Parsi RA, Porstmann W. Left ventricular mass in coronary artery disease without hypertension. Hemodynamic and angiocardiographic study. *Br Heart J.* 1974;36(4):362-7. doi: 10.1136/hrt.36.4.362.
16. Strauer BE. Ventricular function and coronary hemodynamics in hypertensive heart disease. *Am J Cardiol.* 1979;44(5):999-1006. DOI: 10.1016/0002-9149(79)90235-2.
17. Yotsukura M, Suzuki J, Yamaguchi T, Sasaki K, Koide Y, Mizuno H, et al. Prognosis following acute myocardial infarction in patients with ECG evidence of left ventricular hypertrophy prior to infarction. *J Electrocardiol.* 1998;31(2):91-9. DOI: 10.1016/s0022-0736(98)90039-5.
18. Koyanagi S, Eastham C, Marcus ML. Effects of chronic hypertension and left ventricular hypertrophy on the incidence of sudden cardiac death after coronary artery occlusion in conscious dogs. *Circulation.* 1982;65(6):1192-7. DOI: 10.1161/01.cir.65.6.1192.
19. Margolis JR, Kannel WS, Feinleib M, Dawber TR, McNamara PM. Clinical features of unrecognized myocardial infarction--silent and symptomatic. Eighteen-year follow-up: the Framingham study. *Am J Cardiol.* 1973;32(1):1-7. DOI: 10.1016/s0002-9149(73)80079-7.
20. Medalie JH, Goldbourt U. Unrecognized myocardial infarction: five-year incidence, mortality, and risk factors. *Ann Intern Med.* 1976;84(5):526-31. doi: 10.7326/0003-4819-84-5-526.
21. Wasserman AG, Bren GB, Ross AM, Richardson DW, Hutchinson RG, Rios JC. Prognostic implications of diagnostic Q waves after myocardial infarction. *Circulation.* 1982;65(7):1451-5. DOI: 10.1161/01.cir.65.7.1451.
22. Bergovec M, Zigman M, Prpić H, Mihatov S, Vukosavić D. Global and regional parameters of left ventricular performance in healthy subjects during rest and exercise assessed by radionuclide ventriculography. *Int J Card Imaging.* 1993;9(1):39-48. DOI: 10.1007/BF01142931.
23. Haendchen RV, Wyatt HL, Maurer G, Zwehl W, Bear M, Meerbaum S, et al. Quantitation of regional cardiac function by two-dimensional echocardiography. I. Patterns of contraction in the normal left ventricle. *Circulation.* 1983;67(6):1234-45. DOI: 10.1161/01.cir.67.6.1234.

Source of Support: Nil, Conflict of Interest: None declared