

Changing Trends in the Management of Penetrating Abdominal Trauma - from Mandatory Laparotomy towards Conservative Management.

Shashikala C K¹, Gautham M V², Suraj Kagwad³

¹Associate Professor, Department of General Surgery, Bangalore Medical College and Research Institute, Bangalore.

²Post Graduate Student, Department of General Surgery, Bangalore Medical College and Research Institute, Bangalore.

³Junior Resident, Department of emergency medicine, Bangalore Medical College and Research Institute, Bangalore.

Received: August 2016

Accepted: August 2016

Copyright: © the author(s), publisher. It is an open-access article distributed under the terms of the Creative Commons Attribution Non-Commercial License, which permits unrestricted non-commercial use, distribution, and reproduction in any medium, provided the original work is properly cited.

ABSTRACT

Background: Penetrating abdominal trauma is a commonly encountered emergency surgical condition. Though it is less common compared to blunt abdominal trauma, it is more dramatic due to the nature of the causative modes of injury involved. Mandatory laparotomy, which was earlier advocated for these cases, has gradually been replaced by conservative management in carefully selected cases thereby avoiding the unnecessary complications associated with laparotomy. Aims and objectives: To study the efficacy of conservative management in cases of penetrating abdominal trauma thereby obviating the need for unnecessary laparotomy. **Methods:** It was a prospective study conducted in a tertiary hospital, involving 64 patients, over a 2 year period. All patients underwent a CT scan to identify their injuries following a clinical examination and patients were managed conservatively or underwent laparotomy based on the CT findings. **Results:** Of the 64 patients 53 were managed conservatively making it a success rate of 82.81%. Only 2 patients who had a negative CT scan needed a subsequent laparotomy making it a very reliable investigation in these patients. **Conclusion:** Conservative management for penetrating abdominal trauma patients is effective in the majority of cases and hence can be advocated in the initial management plan of these cases supplemented by serial assessment of physical symptoms and signs, unless laparotomy is considered necessary based on their initial CT or physical examination findings.

Keywords: Penetrating abdominal trauma, mandatory laparotomy, conservative management, CT scan.

INTRODUCTION

Trauma, accidental or deliberate, is the most common cause of mortality in adults <40 years of age.^[1] Abdomen is third in the list of most commonly injured regions in trauma.^[2] Abdominal trauma can be either blunt or penetrating. Although blunt abdominal trauma predominates to be the most common mode of abdominal injury ^[1,3], penetrating abdominal trauma still remains one of the commonly encountered emergency conditions in surgical practice.

Name & Address of Corresponding Author

Dr. Gautham M V
Post Graduate,
Department of General Surgery,
Bangalore Medical College and Research Institute,
Bangalore.

There are various modes of penetrating abdominal trauma such as stab injury, gunshot wounds (GSW), animal gore injury and road traffic accidents (RTA). Traditionally most cases of penetrating abdominal trauma were managed by emergency exploratory laparotomy, but recent trends have changed towards conservative management of a subset of carefully

selected patients of penetrating trauma who are hemodynamically stable, thereby avoiding unnecessary emergency laparotomies in this predominantly young patient group and the concomitant morbidities associated with surgical intervention. Here we report our experience in the conservative management of a few selected cases of penetrating abdominal trauma.

MATERIALS AND METHODS

This was a prospective study conducted in a tertiary care hospital in South India from July 2014 to January 2016. A total of 64 patients with penetrating abdominal trauma presenting to the trauma and emergency centre of the hospital were enrolled in the study. The proposed management plan was explained and written informed consent taken from all patients.

Inclusion criteria:

- Patients with penetrating abdominal trauma due to any mode of injury presenting to the trauma and emergency centre of our hospital

- Patients who underwent non-surgical resuscitation or treatment in other centres before being referred to our hospital.

Exclusion criteria:

- Patients with other associated injuries such as head injury or fractures which required immediate surgical intervention.
- Patients with hemodynamic instability.
- Patients with RTA as the mode of penetrating injury.
- Patients who underwent any surgical procedure at other centres before being referred to our hospital.
- Patients in whom chest or erect abdominal radiograph showed air under diaphragm on admission, who required immediate exploratory laparotomy.
- Patients with visible bowel loops or abdominal organ herniation through the abdominal defect.
- Patients with no breach in anterior abdominal fascia on primary wound exploration.
- Patients who refused to consent for proposed treatment.

Methodology:

All patients were admitted and primarily resuscitated according to ATLS guidelines. Following stabilization of vitals, base line blood investigations were done, which included a complete blood picture, random blood sugar, renal function tests (RFT), serum electrolytes, liver function tests, prothrombin time and INR. A chest radiograph, erect abdominal radiograph and an ultrasound (USG) abdomen were done on admission. Following the baseline investigations, a wound exploration was done and the wound cleaned and sutured in layers, if no contamination was found and sterile dressing was placed.

A contrast enhanced CT (CECT) or non-contrast computed tomography (NCCT) of the abdomen and pelvis with or without thorax was done in all 64 patients. Patients undergoing non-surgical management were then closely monitored hourly for first 24 hours, including vitals and clinical examination of the abdomen for signs of peritonitis. After the first 24 hours, monitoring was done every 6 hours for the next two days and then daily until discharge. Patients undergoing surgical intervention were managed according to standard protocol and followed up.

RESULTS

A total of 64 patients were included in the study of which 51 were males and 13 were females (M:F 4:1). Age of patients ranged from 17 to 67 years (median age 35 years). Male to female ratio is shown in [Figure 1].

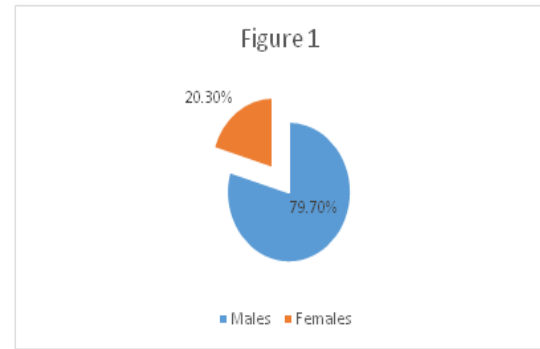


Figure 1: Gender Distribution.

Stab injury to the abdomen was the most common mode of injury seen in 40 males and 4 females (44 of 64 cases) accounting for 68.7% of patients. The next common mode of injury was animal gore injury seen in 8 males and 9 females (17 of 64 cases) representing 26.6% of cases. Gunshot injury was seen in 3 out of 64 cases, all three being males, which formed 4.7% of cases. Road traffic accidents (RTA) causing penetrating abdominal trauma were excluded from the study even though they had only abdominal injury, as associated blunt trauma component could not be ruled out in such high velocity injuries. Various types of injuries are shown in [Figure 2].

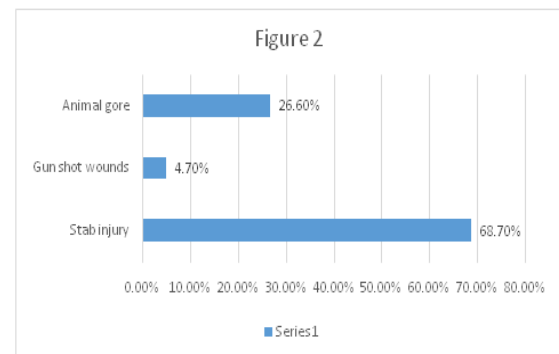


Figure 2: Types of Injury.

Of the 64 patients, 38 presented first to our hospital (59.4%), while 26 were referred from other centres (40.6%). 11 patients presented within 1 hour of injury (17.2%), 45 within 1 to 12 hours (70.3%) and 8 patients after 12 hours (12.5%) of trauma.

All patients were subjected to computed tomography (CT) scan of abdomen and pelvis as a routine irrespective of their radiograph and USG findings. 4 underwent NCCT due to deranged RFT while the rest 60 patients underwent CECT. 16 of 64 patients had an external injury site in close proximity to the thorax and hence CT thorax was also included. CT showed no internal injuries in 40 of 64 patients (62.5%).

Isolated liver injury with mild to moderate hemoperitoneum was seen in 8 patients, while 4 patients showed a non-bleeding mesenteric hematoma. Two patients had renal injury as

documented by their CT, one of whom had an upper pole renal laceration while the other had a renal pedicle injury. Renal perfusion scan was done in the patient with renal pedicle injury, which showed adequate renal perfusion. All the above 14 patients (21.9%), including those with renal injury were managed conservatively. Figure 3 shows the CT findings.

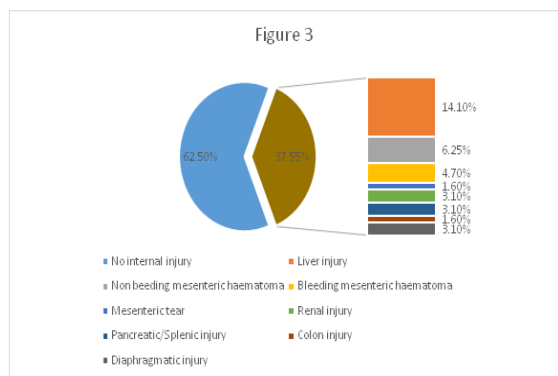


Figure 3: CT Findings.

7 patients with stab injury (10.9%) required surgical intervention based on their CT findings. Diaphragmatic injury was seen in 2 patients (3.1%), for which repair was done by a laparotomy incision and intercostal drainage (ICD) tube was placed. Injury to the tail of pancreas with splenic hilar injury was seen in 1 patient (1.6%) for whom a distal pancreatectomy with splenectomy was done. Bleeding mesenteric hematoma was seen in 3 patients (4.7%) who underwent a laparotomy and ligation of bleeders. Descending colonic perforation with localized pneumoperitoneum was seen in 1 patient (1.6%) which was repaired with a segmental resection and primary anastomosis.

Of the 3 patients with gun shot wounds (GSW), 1 had multiple pellets lodged in the epigastrium with two pellets in the general peritoneal cavity and a left lobe grade 2 liver laceration who was managed conservatively. 1 patient had a jejunal mesenteric tear with decreased jejunal viability and underwent a primary resection and anastomosis. The other patient had a lower pole splenic laceration who was initially managed conservatively but eventually required a splenectomy after 2 days due to a consistent fall in hemoglobin levels.

Of the 40 patients who showed no internal injury in their initial CT scan, 2 patients (3.1%) eventually required a laparotomy. Both the patients developed increasing abdominal pain and distension with tachycardia and tachypnea and were hence operated. 1 patient was operated on day 2 and was found to have an ascending colon perforation near hepatic flexure for which a primary closure was done. The other patient was operated on day 3 and had a negative laparotomy.

All patients were followed up for a period of 6 months. There was no mortality or significant

morbidity seen in patients undergoing conservative management. The success rate in those selected for conservative management by initial physical examination and CT scan was 96.4% (53 out of 55) while the overall rate of success with conservative management was 82.81% (53 out of 64 patients).

DISCUSSION

This study includes 64 patients of penetrating abdominal trauma of which 51 (79.7%) were males and 13 (20.3%) were females. Most studies show a higher incidence of penetrating abdominal trauma in males. Torres and Gonzalez in a study of 89 patients reported an incidence of 79.8% in males and 20.2% in females which is similar to our study.^[4]

The age range in our study was 17- 67 years with a median age of 35 years. The most common age group was 16- 30 years in the study by Torres and Gonzalez.^[4] Studies show that a predominantly younger age group is usually by trauma and an unnecessary laparotomy therefore causes a significant morbidity. According to a study by Shaftan et al there was a 92% incidence of stab injury in penetrating trauma.^[5] Our study showed 68.7% stab injury constituting two-thirds of the cases.

87.5% of the patients presented within first 12 hours of trauma. Clinical assessment plays a very important role in the initial assessment of the patient and to decide the modality of treatment. Physical examination is extremely reliable in deciding the need for laparotomy.^[6] A study by Robin et al. published in 1989 comprising 333 patients concluded that most serious injuries would declare themselves on initial clinical assessment.^[7] Velmahos et al in a study of 192 patients showed that clinical examination had a sensitivity of 100% and specificity of 95%.^[8]

After examination, all patients were subjected to a routine CT scan abdomen and pelvis with or without a CT thorax. CT is a very accurate investigation for the detection of penetrating abdominal trauma and the decision to manage conservatively can be taken based on CT alone. This observation is supported by various studies. A prospective study by Shanmuganathan et al in 2004 in 200 patients reported an accuracy of 98% of contrast CT in penetrating trauma.^[9] Salim et al, in a study of 156 patients reported that the negative predictive value of CT was 100%.^[10] CT is also very specific and sensitive for gun shot wounds as shown by Velmahos et al in 2005.^[11] In our study 2 patients out of 40 with a negative CT scan subsequently underwent a laparotomy one of which was negative thereby making it effective in 97.5% cases.

Liver was the most commonly injured solid organ in our study accounting for 14.1% of cases, all of which were managed conservatively. Liver injuries

usually do not require surgery and liver being the most commonly injured organ in penetrating trauma^[12], majority of the patients of penetrating abdominal trauma can undergo non-surgical management. Shanmuganathan et al reported successful non surgical management in 91.3% of patients with isolated liver injury. He also reported 6 cases of renal injury, none requiring surgery.^[9] Our series had 2 patients of renal injury both well managed conservatively. However confirming a good perfusion is absolutely essential for considering conservative treatment in these patients.

Based on the CT findings, 85.9% (55 out of 64) of patients were planned for conservative management. Of these, 96.4% (53 out of 55) patients recovered well without surgical intervention. In our study, 53 out of 64 patients were managed effectively without laparotomy making it an overall success rate of 82.81% and all had no significant adverse events at the end of a follow up of 6 months.

The percentage of patients undergoing successful conservative management varies from 47%- 96.9%. Demetriades et al in a prospective study of 651 patients reported a favourable outcome with conservative management in 306 patients (47%).^[13] Later in 2006, in a series of 43 patients, he reported that 95.3% patients were managed conservatively without complications.^[12] Conservative management has been advocated in gun shot wounds as well. Though our study had a positive outcome in 33.3% of patients with gun shot injuries to the abdomen, other studies have reported a success rate as high as 96.9%.^[14]

A retrospective review of 792 patients with abdominal gun shot wounds treated with selective non-operative management reported by Velmahos et al, showed that 712 patients (90%) were successfully managed non-operatively.^[15] If these patients had been managed by routine laparotomy, the unnecessary laparotomy rate would have been 47%. A study from Harlem Hospital, published in 1974, reported a 43.9% negative exploration rate after penetrating abdominal trauma, with a complication rate of 8.7%.^[16] Nance and Cohn from the Charity Hospital in New Orleans evaluated a new policy of selective non operative management versus earlier policy of mandatory laparotomy. The rate of unnecessary laparotomy significantly decreased from 67% to 25% with conservative management. A high complication rate of 24% was associated with earlier mandatory surgical treatment.^[17]

Hence conservative management is safer and more favourable with lesser morbidity and complications and obviates the need for unnecessary laparotomy especially in the younger age group who are frequently associated with penetrating abdominal trauma. Although our study showed no significant difference in the duration of hospital stay ($p>0.05$), Leppaniemi et al. in their series of 51 patients with stab wounds to the anterior abdomen reported a

morbidity rate of 19% following mandatory laparotomy and 8% after observation and the mean duration of hospital stay was shorter in the observation group ($p = 0.002$).^[18]

CONCLUSION

Conservative management in a group of carefully selected patients with penetrating abdominal trauma is an established standard of care, which minimizes surgical morbidity and improves the quality of life. Careful initial examination complemented by CT scan can be used to select the patients who can be managed non-operatively.

REFERENCES

1. Aldemir M, Tacyildiz I, Girgin S. Predicting factors for mortality in the penetrating abdominal trauma. *Acta Chir Belg.* 2004;104:429-34.
2. Hemmila MR, Wahl WL. Management of the Injured Patient. In: Doherty GM, editor. *Current Surgical Diagnosis and Treatment.* McGraw-Hill Medical; 2008. pp. 227-8.
3. Smith J, Caldwell E, D'Amours S, Jalaludin B, Sugrue M. Abdominal trauma: A disease in evolution. *ANZ J Surg.* 2005; 75:790-4.
4. B I Monzon-Torres, Maria Ortega-Gonzalez. Penetrating abdominal trauma. *SAJS.* 2004;42:11-13.
5. Shaftan GW. Indications for operation in abdominal trauma. *Am J Surg.* 1960;99:657-664.
6. Peck JJ, Berne TV. Posterior abdominal stab wounds. *J Trauma.* 1981, 21:298-306.
7. Robin AP, Andrews JR, Lange DA, Roberts RR, Moskal M, Barrett JA. Selective management of anterior abdominal stab wounds. *J Trauma.* 1989;29:1684-1689.
8. Velmahos GC, Demetriades D, Cornwell EE, Asensio J, Belzberg H, Berne TV. Gunshot wounds to the buttocks: predicting the need for operation. *Dis Colon Rectum.* 1997; 40: 307-311.
9. Shanmuganathan K, Mirvis SE, Chiu WC, Killeen KL, Hogan GJ, Scalea TM. Penetrating torso trauma: triple-contrast helical CT in peritoneal violation and organ injury—a prospective study in 200 patients. *Radiology.* 2004;231:775-784.
10. Salim A, Sangthong B, Martin M, et al. Use of computed tomography in anterior abdominal stab wounds. *Arch Surg.* 2006; 141:745-752.
11. Velmahos GC, Constantinou C, Tillou A, Brown CV, Salim A, Demetriades D. Abdominal computed tomographic scan for patients with gunshot wounds to the abdomen selected for nonoperative management. *J Trauma.* 2005;59:1155-1161.
12. Demetriades D, Hadjizacharia P, Constantinou C, et al. Selective nonoperative management of penetrating abdominal solid organ injuries. *Ann Surg.* 2006;244:620-628.
13. Demetriades D, Rabinowitz B. Indications for operation in abdominal stab wounds: a prospective study of 651 patients. *Ann Surg.* 1987;205:129-132.
14. Velmahos GC, Demetriades D, Foianini E, Tatevossian R, Cornwell EE 3rd, Asensio J, Belzberg H, Berne TV: A selective approach to the management on gunshot wounds to the back. *Am J Surg.* 1997; 174:342-346.
15. Velmahos GC, Demetriades D, Toutouzias KG, et al. Selective nonoperative management in 1,856 patients with abdominal gunshot wounds: should routine laparotomy still be the standard of care? *Ann Surg.* 2001;234:395-403.

16. Forde KA, Ganepola GA. Is mandatory exploration for penetrating abdominal trauma extinct? The morbidity and mortality of negative exploration in a large municipal hospital. *J Trauma*. 1974;14:764–766.
17. Nance FC, Cohn I Jr. Surgical management in the management of stab wounds of the abdomen: a retrospective and prospective analysis based on a study of 600 stabbed patients. *Ann Surg*. 1969;170:569–580.
18. Leppaniemi AK, Haapiainen RK. Selective nonoperative management of abdominal stab wounds: prospective, randomized study. *World J Surg*. 1996; 20:1101–1105.

How to cite this article: Shashikala C K, Gautham M V, Suraj Kagwad. Changing Trends in the Management of Penetrating Abdominal Trauma- from Mandatory Laparotomy towards Conservative Management. *Ann. Int. Med. Den. Res.* 2016; 2(6):SG19-SG23.

Source of Support: Nil, **Conflict of Interest:** None declared