

# A Prospective Comparative Study to evaluate drainage of liver abscess by 20 Fr PVC catheter versus 10 Fr pigtail catheter.

Minakshi Gadahire,<sup>1</sup> Raghav Shrotriya<sup>2</sup>

<sup>1</sup>Associate Professor, Department of General Surgery, Lokmanya Tilak Municipal Medical College and Hospital, Mumbai, India.

<sup>2</sup>Senior Resident, Department of General Surgery, Lokmanya Tilak Municipal Medical College and Hospital, Mumbai, India.

Received: August 2016

Accepted: August 2016

**Copyright:** © the author(s), publisher. It is an open-access article distributed under the terms of the Creative Commons Attribution Non-Commercial License, which permits unrestricted non-commercial use, distribution, and reproduction in any medium, provided the original work is properly cited.

## ABSTRACT

**Background:** Large liver abscess requires drainage by pigtail catheter. These catheters tend to get blocked frequently and thus takes long period of time to completely drain. So we wanted to study whether inserting a large bore catheter would drain the abscess faster thus decreasing the stay and requirement of antibiotics. **Aim:** To study the effectiveness of wide bore PVC catheter (20 Fr) in drainage of large peripheral liver abscess as compared to the use of pigtail catheter (10 Fr). **Methods:** The study was prospective comparative study done at a tertiary care hospital. Over a period of 22 months, 60 patients of amoebic liver abscess were assigned to undergo pigtail catheter drainage by 10 Fr. Versus wide bore 20 Fr PVC catheter drain and the outcomes were compared. **Results:** Use of wide bore (20 Fr) PVC catheter significantly decreased the duration of treatment, led to faster drainage of abscess and decreased incidence of recurrence in large amoebic liver abscess, as compared to pigtail catheter drainage by the standard 10 Fr pigtail catheter. **Conclusion:** 20 Fr PVC catheter is safe and efficacious for evacuating large solitary peripheral liver abscesses and should be preferred to narrow bore pigtail catheter.

**Keywords:** Large Liver abscess, pigtail catheter drainage of liver abscess, amoebic liver abscess.

## INTRODUCTION

Around 15% of Amoebic Liver Abscesses (ALA) may be refractory to medical therapy.<sup>[1]</sup> In such cases, percutaneous drainage by 10Fr pigtail catheter placed under USG guidance is presently considered as the treatment of choice.<sup>[2-4]</sup> The pigtail catheter gets repeatedly blocked, requires regular flushing and takes a long time to evacuate the abscess. We conducted a prospective comparative study in 60 patients to determine the relative safety and efficacy of a new procedure of draining the large peripheral right lobe liver abscesses using wide bore 20 Fr PVC catheter as compared to the conventionally used 10 Fr pigtail catheter.

### Name & Address of Corresponding Author

Dr. Minakshi Gadahire,  
1st floor, R No-25, College building,  
LTMMC & Hospital, Sion,  
Mumbai- 400022,  
Maharashtra, India.  
Email: gadhireminakshi@yahoo.in

## MATERIALS AND METHODS

All patients with solitary large liver abscess who were admitted in our hospital between December

2010 and October 2012 were considered candidates for the study.

**Inclusion criteria-** Age 18-70 years, patients with the classic triad of right upper quadrant pain, hepatomegaly and low-grade fever were taken and were subjected to ultrasonography and if it showed a single, large (size > 7 cms. in any dimension or volume > 250 cc), liquefied and peripheral (liver parenchyma <1 cm on USG or no discernible parenchyma) liver abscess in right lobe of liver, patient was enrolled in the study.

**Exclusion Criteria-** Patients younger than 18 yrs or older than 70 years, ruptured amoebic liver abscess, vitally unstable patient, multiple non communicating abscess cavities, abscess in left lobe of liver, abscess having thicker peripheral parenchyma and patients lost to early follow up.

### **Procedure**

All patients gave written informed consent, and the study was approved by the local ethics committee. Sealed envelopes containing the names of the treatments were used to randomly assign 60 eligible patients to undergo percutaneous drainage of abscess by 10 Fr pigtail catheter or 20 Fr PVC catheter (30 patients in each group).

At presentation, all patients with clinical suspicion of liver abscess underwent USG. According to the

inclusion criteria as described above, patients were enrolled for the study and allocation of procedure was done depending upon name of the procedure in the envelope. Routine investigations and sero-status were done. Those with deranged PT-INR were transfused FFP to normalize the coagulation profile before our intervention. All patients were started on routine medical therapy including Ciprofloxacin, Metronidazole and Chloroquine. Those who were allocated 20 Fr. PVC catheter drainage underwent CECT (Abdomen) for better delineation of the anatomy of the abscess and check for thickness of peripheral liver tissue specially laterally along the anterior axillary line.

Percutaneous treatment was performed within 48 hours after admission. 10Fr pigtail catheter drainage was done by standard procedure by ultrasonologist under USG guidance. 20 Fr PVC Catheter was inserted under vision by open technique in the 8th intercostal space as seen on CT plates to provide a window to the abscess with thinnest area of surrounding liver parenchyma. 20 Fr. PVC catheter was inserted percutaneously by taking incision of 1 cm in between 7th and 8th intercostal space after giving local anaesthesia. Then intercostal muscles are dissected by artery forceps and liver abscess is aspirated by needle and in same direction 20 Fr. PVC catheter is inserted in the liver abscess. Following the catheter insertion, X-Ray chest and abdomen were done. For the first twelve to twenty four hours, hourly watch was kept on the temperature, pulse, respiration, and abdominal girth to check for signs of haemorrhage or peritonitis. This procedure is done in operation theatre, this caution is taken so that if there is pneumothorax, we can immediately insert an ICD tube.

During catheter placement into the abscess cavity, anchovy sauce like material was obtained from all 60 patients and was sent for routine microscopy and culture sensitivity. The antibiotics were adjusted according to the results of culture and sensitivity testing of the abscess. Patients with negative culture results were continued on the initial drug treatment.

Follow up USG was performed on Day 3, 6, 9 to see for size of residual abscess cavity. Catheters were removed if output had decreased to less than 20ml / 20hr and if USG showed residual size of the cavity less than 3 cm. In case the output was persistently high or the abscess cavity had not collapsed and if patients were clinically improved, they were discharged with catheter in situ and asked to follow up after 1 week with a follow up USG and catheter was then removed according to the criteria as discussed above. However only 10 Fr. Pigtail catheter patients took longer period for decompression of abscess and those patients were discharged with pigtail catheter in situ. Intravenous antibiotic therapy was followed by a four week course of appropriate oral antibiotics. All patients underwent clinical follow-up and monitoring during

daily rounds until they were discharged from the hospital. Follow-up USG was performed every third day as previously described.

After discharge from the hospital, patients underwent follow-up evaluations in the outpatient clinic at least once a week during treatment and biweekly until 6 months from the beginning of the treatment. Patient with a 10 Fr. Pigtail catheter were discharged as large number of new emergency patients have to be admitted where in we do not deny admission to any patient requiring emergency surgical procedures. So the patients in 10 Fr. Pigtail group who were clinically stable enough to be discharged were asked to follow-up on opd basis with daily chart of pigtail output. These patients underwent follow up sonography every three days until there was no (or <20 ml) catheter output for 20 hours, and then the catheter was removed.

Patients outcome, including length of hospital stay, complications related to the procedure, and treatment failure were recorded. Treatment was considered successful if all of the following criteria were met: The patients improved clinically (i.e. subsidence of fever and local signs and symptoms), elevated leukocyte counts were normalized, follow-up imaging showed resolution of the abscess (total resolution or reduction in size to <3 cm) and no evidence of relapse or recurrence was seen during follow-up.

#### **Statistical Analysis:**

Nonpaired Student's t- test was used to assess the statistical significance of differences in the periods of hospitalization and the time needed for clinical improvement, period of catheter removal, reduction in size of abscess cavity, and total or near-total resolution of the abscess after percutaneous treatment. The chi-square test was used to compare the rates of recurrence and complication between the two treatment techniques. P-value of less than .05 was considered statistically significant.

## **RESULTS**

The average size of the abscess in our study was 795 ml as per the USG findings. This study reveals that mean duration for which catheter was kept was 13.17 days in 10 Fr. Pigtail group which was significantly more as compared to 6.83 days among 20Fr. PVC Catheter group.

Table 1 shows comparison of mean percentage reduction in Lmax (maximum dimension of the abscess) between the two groups. At day 3, mean reduction was 25.71% in 10 Fr. Pigtail group, which was significantly less than 43.14% among the 20 Fr. Catheter group. The same trend was observed at day 6 and 9. This shows that the 20 Fr. PVC wide bore catheter is more efficient in draining the pus of large liver abscess as compared to the pigtail, more significantly in the initial phase of 3-6 days. Table 2 describes the complications related to both the

procedure, where there was pneumothorax in two patients of 20 Fr. PVC catheter group. Table 3 shows the duration of drainage catheter which reveals that mean duration for which drainage catheter was kept was 13.17days in Pigtail group which was significantly more as compared to 6.83 days among PVC catheter group which means that pigtail took more as compared to 6.83 days among PVC catheter group which means that pigtail took longer time to drain and had to be kept for a longer period. Table IV, shows mean duration of stay in hospital was 10.07 days among Pigtail group that was comparable with 9.43 days among PVC drain group and the difference was not statistically significant, as the pigtail group of patients were discharged with pigtail in situ after clinical improvement.

Figure 1, depicts the difference in the rate of recurrence after percutaneous catheter drainage. It was observed that 13.3% of the cases in Pigtail group had recurrence as per the USG findings at 1 month, whereas there was no recurrence seen in 20 Fr. PVC catheter group.

**Table 1: Reduction in size of liver abscess**

Duration in Days	Mean % of Reduction in L <sub>max</sub> (cms) ( $\bar{X} \pm SD$ )				p value
	N	Pigtail	N	Catheter	
D3	30	25.71 ± 23.08	30	43.14 ± 13.66	*0.0007
D6	26	37.82 ± 12.80	20	59.13 ± 14.34	*0.0000
D9	12	43.38 ± 17.62	02	58.78 ± 04.32	*0.0234
D12	08	54.44 ± 11.42	01	60.31 ± (-)	0.1893(NS)

By Student's t-Test \* = Significant, NS = Non Significant

**Table 2: Complications related to both the procedure**

Complications	Pigtail (N=30)		PVC Catheter (N=30)	
	No.	%	No.	%
Pneumothorax	-	-	02	06.7
Bilious fistula	01	03.3	-	-
Recurrent blockage	02	06.7	-	-

By Chi - Square Test p> 0.05 Not Significant

**Table 3: Comparison of mean duration of drainage between the two groups**

Groups	Mean Duration of drain (days) ( $\bar{X} \pm SD$ )
Pigtail (N= 30)	13.17 ± 6.11
Drain (N= 30)	6.83 ± 2.59
p value	*0.0000

By Student's t-Test \*Significant

## DISCUSSION

Pyogenic liver abscess are usually multiple and small, whereas Amoebic liver abscess are solitary and large and has a lot of necrotic liver parenchyma and therefore is not drained efficiently by the 10 Fr pigtail catheters. So we tried to find out whether

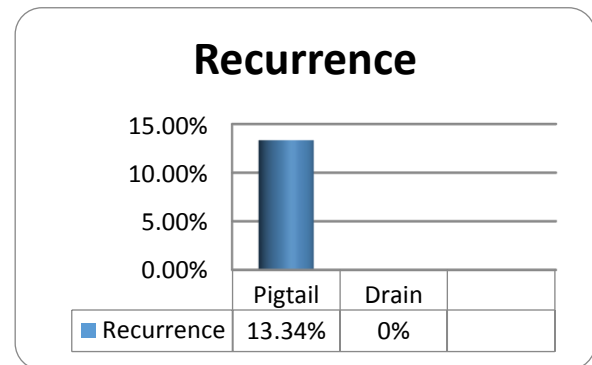
large size catheter would drain the pus faster with less chances of blockage of tubes. CT scan and USG was done for all the patients of the PVC-catheter arm to delineate the three dimensional anatomy of the abscess. Based on the findings, the decision to put wide bore catheter had to be changed in favour of putting a pigtail catheter in two cases as the thickness of the surrounding liver parenchyma was found to be more.

**Table 4: Comparison of mean duration of hospital stay between the two groups**

Groups	Mean Duration of hospital stay(days) ( $\bar{X} \pm SD$ )
Pigtail (N= 30)	10.07 ± 5.30
Drain (N= 30)	9.43 ± 3.08
p value	0.5696

By Student's t-test

Not Significant



**Figure 1: Rate of recurrence [Pigtail – 10 Fr. Catheter, Drain – 20 Fr. PVC catheter]**

The average size of the abscess in our study (868 ml for 20 Fr.Catheter and 722 ml for 10 Fr.pigtail on USG) was larger than in other series.<sup>[5,6]</sup> In contrast to some of the earlier reports that show that the initial size of the abscess cavity did not affect the ultimate outcome, we believe that large abscesses are more difficult to evacuate completely in one attempt.<sup>[7]</sup> The reasons for failure of percutaneous catheter drainage, as reported in some of the earlier series, have been either thick pus not amenable to percutaneous drainage (this problem can be overcome by using larger bore catheters) or premature removal of the drainage catheter (strict adherence to the criteria for catheter removal can prevent this problem).<sup>[3,4,8]</sup>

In our series, the average number of days after which the catheter was removed, was just about double for the pigtail (13.17) as compared to 20 Fr. PVC catheter (6.83), which means that pigtail took longer time to PVC catheter and had to be kept for a longer period. The average hospital stay (9.75 days) of the patients who underwent percutaneous 20 Fr. PVC catheter drainage in our study was shorter than that reported in two earlier series.<sup>[8,9]</sup> The shorter hospital stay could also be related to the fact that, unlike the practice in previous studies, we did not wait for total

radiologic resolution (non visualisation of the abscess cavity) before discharge.<sup>[8,9]</sup>

In keeping with the findings of earlier reports, both treatment techniques resulted in rapid clinical relief, with most patients showing resolution of fever, local symptoms, and leukocytosis within 2 days of the procedure.<sup>[9,10]</sup> The time required for complete sonographic resolution of abscess cavities after percutaneous treatment ranges from 2 weeks to 9 months.<sup>[6, 10]</sup> In fact, total resolution may not occur, and small residual cavities may persist for years. Such cavities are usually indistinguishable from simple hepatic cysts.<sup>[11]</sup> It must be noted that 10 Fr. pigtail catheter gets repeatedly blocked due the thick, viscous pus and require flushing by saline flush. This problem was not found in the wide bore 20 Fr. PVC catheter.

In our series complications occurred in six patients out of 60 (10%). Two patients had recurrent blockage of the pigtail catheter and had to be flushed regularly. One pigtail catheter got removed accidentally. One patient developed a bilious fistula post pigtailing which resolved without any active intervention in 20 days. Two of the patients developed pneumothorax while the procedure of 20 Fr. PVC catheter insertion and had to undergo ICD insertion intra-operatively. These two were the initial cases in which the catheter was inserted through the seventh intercostal space. Our observation with the help of CT scan has taught us that inserting the catheter through the eighth intercostal space in the midaxillary line is a safe way of avoiding such complications.

We took all patients having large single liver abscess for our study, serological tests were not conducted to differentiate pyogenic from amoebic liver abscess. Our basic aim was to check whether large diameter catheter helps in faster drainage of abscess. In majority of cases diagnosis was made on history, examination, USG. CT scan was done only for 20 FR. PVC catheter group to be more careful as we were using large bore catheter study for the first time.

The flow of various body fluids through catheters has been demonstrated to follow the Poiseuille's law. According to this law, catheter diameter is a theoretic component of flow rate, with wide bore catheters having an advantage over the ones with smaller diameter. Our review of the literature suggests similar success for small- and large-diameter catheters. Park et al tabulated the average number of days of drainage for small and large catheters from reported series.<sup>[12]</sup> Unexpectedly, drainage times were less with the small-diameter catheters than with the large-diameter catheters. The most plausible explanation for this paradox is that less-viscous collections were drained with small catheters. In the other cases, the viscosity of the material drained was great enough so that even the

large-diameter catheters did not enhance drainage proportionately.

Park et al conducted experiments testing a variety of fluids for their viscosity and flow through different sizes of catheters under standard condition.<sup>[12]</sup> They found that the flow of all these fluids, including pus, was according to Poiseuille's law. From a practical point of view, the experiment showed the benefit of using larger catheters; thereby confirming that particularly for more viscous fluid, larger catheters provide significantly faster flow than smaller catheters do.

In a preclinical and in vitro study by Niinami et al, 19 Fr tubes were compared with 28 Fr tubes.<sup>[13]</sup> When the ability to catheter water at a set pressure of 10 mmHg was measured, the larger tube had a drainage capacity nine fold higher than the smaller. Demonstration of cavity / lesion on imaging after completion of treatment and on follow up does not mean to re-start the treatment rather relies on symptoms and appearance of new lesion.

## CONCLUSION

We propose a newer way of drainage of large hepatic abscesses which may provide faster relief to the patient and reduces the total expenditure as well as length of treatment and thereby the associated morbidity. Based on our review of existing literature and our experience to date, we suggest the following to guide the management of large solitary hepatic abscesses:

Wide bore (20 Fr) PVC catheter is safe and efficacious and fast way of evacuating the massive solitary peripheral liver abscesses (>7 cm or > 250 ml) and should be preferred to narrow bore 10 Fr. pigtail catheter.

## REFERENCES

1. Thompson JE, Forlenza S, Verma R. Amoebic liver abscess: a therapeutic approach. *Rev Infect Dis* 1985; 7: 171-179.
2. Rajak CL, Gupta S, Jain S, et al. Percutaneous treatment of liver abscesses: needle aspiration versus catheter drainage. *AJR* 1998; 170: 1035-1039.
3. VanSonnenberg E, Mueller PR, Schiffman HR. et al. Intrahepatic amoebic abscesses: indications for and results of percutaneous catheter drainage. *Radiology* 1985; 156: 631-35.
4. Saraswat VA, Agarwal DK, Baijal, et al. Percutaneous catheter drainage of amoebic liver abscess. *Clin Radiol* 1992; 45: 187-189.
5. Baek SY, Lee MG, Cho KS, Lee SC, Sung KB, Auh YH. Therapeutic percutaneous aspiration of hepatic abscesses: effectiveness in 25 patients. *AIR* 1993; 160: 799-802.
6. Giorgio A, Amoroso P, Francica G, et al. Echoguided percutaneous puncture: a safe and valuable therapeutic tool for amoebic liver abscess. *Gastrointest Radiol* 1988; 13:336-340.
7. Stain SC, Yellin AE, Donovan AJ, Brien HW. Pyogenic liver abscess: Modern treatment. *Arch Surg* 1996; 126: 991-996.
8. Bertel CK, van Heerden JA, Sheedy PF. 2nd Treatment of pyogenic hepatic abscess. Surgical vs percutaneous drainage. *Arch Surg* 1986;121: 554-558.

9. Artar B, Levendoglu H, Cuasay NS. CT-guided percutaneous aspiration and catheter drainage of pyogenic liver abscesses. *Am J Gastroenterol* 1986; 81: 550-555.
10. Singh JP, Kashyap A. A comparative evaluation of percutaneous catheter drainage for resistant amebic liver abscesses. *Am J Surg* 1989; 158: 58-62.
11. Ralls PW, Quinn MF, Boswell WD Jr, Calletti PM, Radin DR, Halls J. Pattern of resolution in successfully treated hepatic amebic abscess: sonographic evaluation. *Radiology* 1983; 149: 541-543.
12. Park JK, Kraus FC, Haaga JR. Fluid flow during percutaneous drainage procedures: an in vitro study of the effects of fluid viscosity, catheter size, and adjunctive urokinase. *Am J Roentgenol* 1993; 160: 165-169.
13. Niinami H, Tabata M, Takeuchi Y. Experimental assessment of the drainage capacity of small silastic chest drains. *Asian Cardiovasc Thorac Ann.* 2006; 14: 223-226.

**How to cite this article:** Gadahire M, Shrotriya R. A Prospective Comparative Study to evaluate drainage of liver abscess by 20 Fr PVC catheter versus 10 Fr pigtail catheter. *Ann. Int. Med. Den. Res.* 2016; 2(5):SG14-SG18.

**Source of Support:** Nil, **Conflict of Interest:** None declared