

Adhesive Meckel's Diverticulitis Causing Intestinal Obstruction in a Nine Months Old Child.

Rakshit Ahuja¹, Ajay Verma²

¹Trainee Resident, Department of Surgery, Teerthankar Mahaveer Medical College & Research Centre, Moradabad, UP, India.

²Consultant, Pediatric Surgery, Teerthankar Mahaveer Medical College & Research Centre, Moradabad, UP, India.

Received: September 2016

Accepted: September 2016

Copyright: © the author(s), publisher. It is an open-access article distributed under the terms of the Creative Commons Attribution Non-Commercial License, which permits unrestricted non-commercial use, distribution, and reproduction in any medium, provided the original work is properly cited.

ABSTRACT

Meckel's diverticulum is often detected incidentally in children with recurrent pain abdomen or bleeding per rectum. Meckel's diverticulum can also be the leading point in intussusception. We present a case of nine months old male child who presented with adhesive meckel's diverticulitis.

Keywords: Meckel's diverticulum, Intestinal Obstruction.

INTRODUCTION

Intestinal obstruction in paediatric population is a surgical emergency which poses the need for prompt diagnosis and quick intervention. Such patients are often brought to the emergency department with complains of bile stained vomiting, abdominal distension and failure to pass faeces. Diseases like duodenal atresia, ileal atresia and meconium ileus present in early days of life. Hypertrophic pyloric stenosis, incarcerated hernia, duplication of alimentary canal with short cystic segment but large intraluminal cysts, annular pancreas and Hirschsprung's disease present later in infancy. Intussusception is seen most commonly in infancy with initiation of dietary changes. Meckel's diverticulum with an umbilical band may lead to volvulus of small intestine. Necrotizing enterocolitis in new born period may present later in life with obstruction due to adhesion and stricture formation.

Name & Address of Corresponding Author

Dr. Ajay Verma
MBBS, MCh (Pediatric Surgery),
Teerthankar Mahaveer Medical College & Research Centre,
Moradabad, Uttar Pradesh, India.

CASE REPORT

A nine month old male, was brought to the emergency department with complains of abdominal distension for past 5 days and multiple episodes of greenish coloured vomiting. There was no history of bleeding per rectum or blood stained faeces. The baby had developed abdominal distension since past 5 days of presentation to the hospital, with multiple episodes of bilious vomiting, absence of bowel

movements for the past 4 days. On examination, baby was afebrile and dehydrated; abdomen was distended, diffusely tender, tense and firm with no palpable mass. On erect abdomen x-ray, gaseous dilatation of small bowel loops with multiple air fluid levels were seen, no gas under diaphragm was noted [Figure 1]. On ultrasonography, bowel loops were dilated and no sign of intussusception was seen. After fluid and electrolyte correction the patient was taken for emergency exploratory laparotomy. Externalization of the intestinal loops was done and bowel loops were explored from duodeno-jejunal flexure till ileo-caecal junction. Whole of the small bowel was dilated and distended with multiple inter loop adhesion. Adhesive bands were noted from distal part of jejunum and whole of the ileum [Figure 2, 3]. After careful and meticulous adhesiolysis, terminal ileum was reached where Meckel's diverticulum 20 cm proximal to ileo-caecal junction was found with an adhesive band formation on the adjacent ileum segment leading to obstruction. The Meckel's diverticulum had about 3 cm base with inflammatory changes visible on the ileal segment. The adhesive bands were carefully incised using bipolar cautery and checked for any bleeding. After achieving haemostasis abdomen was closed in layers. The child recovered well and was discharged on post operative day 5.

DISCUSSION

Meckel's Diverticulum is an embryonic derivative of the vitelline duct (omphalomesenteric duct). It is present on anti-mesenteric border of ileum. It is a true diverticulum as it contains all three layers. The first known description of Meckel's diverticulum was in 1598 by Hildanus.^[1] Meckel's diverticulum has

been reported in association with many other congenital anomalies, including esophageal atresia, duodenal atresia, imperforate anus, omphalocele, malrotation, Hirschsprung's disease, Down syndrome, congenital diaphragmatic hernia, and various congenital neurologic and cardiovascular malformations.^[2,3]

Table 1: Rule of 2 for Meckel's diverticulum.

2% of population
2 feet from ileocaecal valve
2 inches in length
2% are symptomatic
2 types of common ectopic tissue (gastric and pancreatic)
2 years of age – Most common age of clinical presentation
2 times more likely in males.

Although Meckel's diverticulum is usually asymptomatic, it may present with abdominal pain in many ways. The three most common presentations are bleeding, obstruction and inflammation. [Table 1] The tip of Meckel's diverticulum may still be connected to umbilicus by a fibrous band over which the bowel may rotate or which may compress the bowel leading to closed loop small bowel obstruction. It may also become inflamed secondary to presence of gastric type of epithelium.

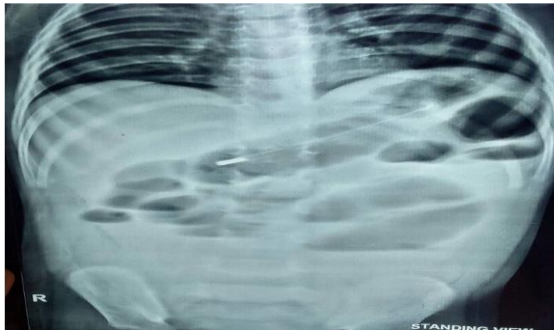

Figure 1: X-ray abdomen erect showing multiple air fluid levels.

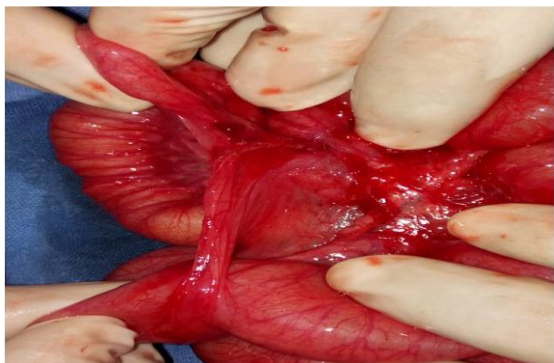

Figure 2: Clinical picture showing dense adhesion around the diverticulum.

Inflammation leads to formation of adhesions with the adjacent bowel segments, the active gastric mucosa may cause ulceration and intraluminal bleeding causing dark-red stools or extra luminal bleeding causing peritonitis. In such cases the child looks pale secondary to anaemia. In such cases it masquerades as acute appendicitis.

Complications of Meckel's diverticulum are bleeding, intussusception, fibrous band causing a small bowel obstruction, diverticulitis, peptic ulceration with perforation, strangulation of diverticulum by its own band and strangulation of diverticulum in an inguinal hernia (Littre's hernia).

Technetium-99m (99mTc) pertechnetate scintigraphy of the abdomen is commonly used to help detect ectopic gastric tissue in a Meckel's diverticulum. In symptomatic patients the diverticulum is removed with a segment of ileum or simple diverticulectomy is performed.

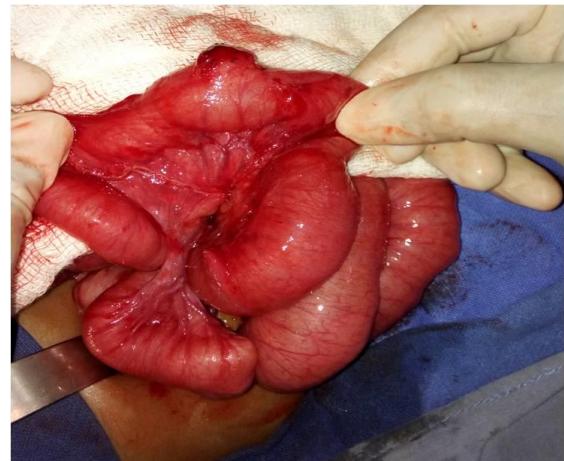


Figure 3: Clinical picture showing inflamed Meckel's diverticulum.

REFERENCES

1. Hildanus F: Opera observationum et curationum medico-chirurgicarum, quae extant omnia, etc. Francof, Beyeri, 1646.
2. Nicol JW, MacKinlay GA: Meckel's diverticulum in exomphalos minor. R Coli Surg J Edinb 1994;39:6.
3. Simms MH, Corkery I J: Meckel's diverticulum: Its association with congenital malformation and the significance of atypical morphology. Br J Surg 1980;67:216.

How to cite this article: Ahuja R, Verma A. Adhesive Meckel's Diverticulitis Causing Intestinal Obstruction in a Nine Months Old Child. Ann. Int. Med. Den. Res. 2016; 2(6):SG03-SG04.

Source of Support: Nil, **Conflict of Interest:** None declared