

# Split Cord Syndrome (Type 1 Diastematomyelia): A Case Report.

B. B. Sharma<sup>1</sup>, Shashi Sharma<sup>2</sup>, Shweta Sharma<sup>3</sup>, Sandeep Sharma<sup>4</sup>, Priya Ramachandran<sup>4</sup>

<sup>1</sup>Professor & H.O.D., Department of Radiodiagnosis, SGT Medical College, Gurgaon.

<sup>2</sup>Associate Professor, Department of Paediatrics, SGT Medical College, Gurgaon.

<sup>3</sup>Senior Resident, Department of ENT & Head & Neck Surgery, SGT Medical College, Gurgaon.

<sup>4</sup>Speciality Doctor, Department of Anaesthesia, Heartlands Hospital, Birmingham, West Midlands B9 555, UK.

Received: July 2016

Accepted: August 2016

**Copyright:** © the author(s), publisher. It is an open-access article distributed under the terms of the Creative Commons Attribution Non-Commercial License, which permits unrestricted non-commercial use, distribution, and reproduction in any medium, provided the original work is properly cited.

## ABSTRACT

Spinal dysraphism can present in various ways in the form of severity. Split cord is one of the presentations where two hemi cords are separated either by a fibrous septum or calcific spur. This may be accompanied with different other vertebral anomalies like block vertebra, hemi vertebra or spina bifida. We present a 8-years old girl who presented with weakness and gait disturbances since she started walking. She also had a tuft of hair on the back in the lumbar region. She underwent computerized tomography (CT) and magnetic resonance imaging (MRI) and was diagnosed as diastematomyelia with other associated anomalies.

**Keywords:** Spinal dysraphism, Calcific spur, CT, MRI.

## INTRODUCTION

Diastematomyelia is the type of spinal dysraphism. It was described first by French researcher C. P. Ollivier in 1837. There is a vertical split of the spinal cord. This term is different from diplomyelia where there is duplication of the cord. The term can be used when there is description of spinal dysraphism. Females are affected more than males. This group forms 5% of all spinal anomalies.

### Name & Address of Corresponding Author

Dr. B. B. Sharma

Professor & H.O.D.,

Dept of Radiodiagnosis,

SGT Medical College,

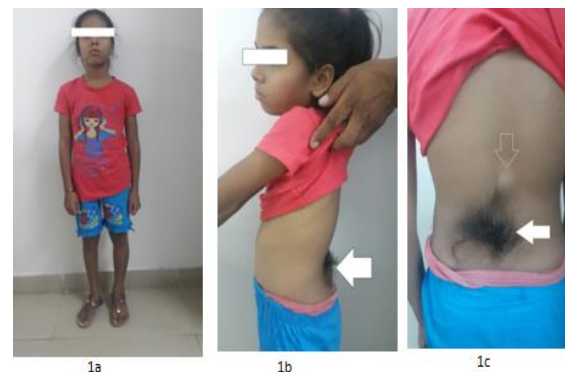Gurgaon, India.

E mail: bbhushan986@gmail.com

## CASE REPORT

8-years old female child reported with a history of hairy patch on the back since birth with progressive increase in lower backache over the years [Figure 1a, b and c]. She complains of weakness of both the legs for the last two years. She complains of some difficulty in walking with postural problems. She could not take on any heavy work because of pain and weakness. On examination, she was of average built without any mental retardation. A physical examination shows a bony protuberance over lumbar region and a hairy patch just below that. Neurological examination and other biochemical

markers were unremarkable.



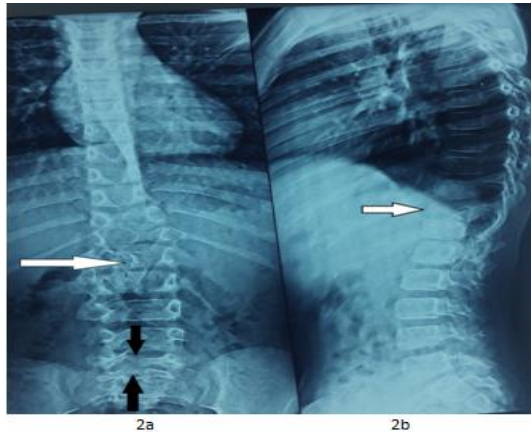
**Figure 1: Photograph of 8-years old girl.(a) Frontal view with normal physique.(b) side view with a tuft of hair on the back (white arrow).(c) tuft of hair seen in back (solid arrow) with bony protuberance just superior to that (white hollow arrow).**

Plain X-ray spine has shown scoliosis with multiple vertebral anomalies with widening of the interpedicle distance at lumbar region. There was bony spur seen at this region [Figure 2a and b].

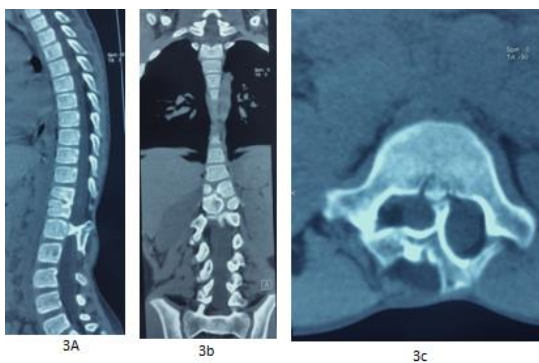
NCCT of the spine has revealed the vertebral anomalies and the osseous spur delineation [Figure 3 a,b and c].

MRI was performed with 1.5 T Philips Multiva whole body scanner. MRI of the spine has highlighted the cord anatomy with its proper extension. There was division of cord and both hemi cords were having different dural sacs, which unite

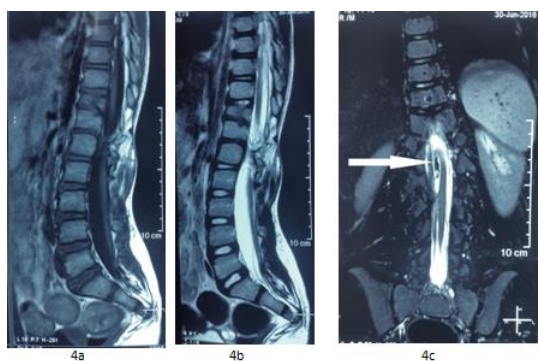
again at some distal end. The cord was tethered finishing at S2 vertebral level. [Figure 4a, b, c] and [Figure 5a, b .c].



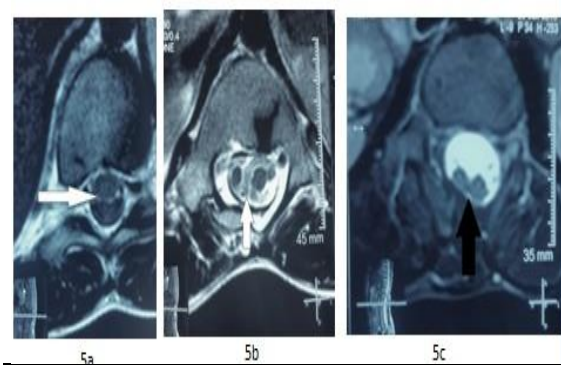
**Figure 2: Plain X-ray spinal column. (a) AP view with widening of spinal canal with bony spur (white horizontal marrow) (b) lateral view shows vertebral anomaly (white arrow).**



**Figure 3: NCCT Spine. (a) Sagittal reformatted image shows the bony spur traversing through the spinal canal. (b) AP view shows widening and vertebral anomalies. (c) transverse section shows two hemi cords are separated .**



**Figure 4: MRI spine. (a) T1W sagittal section shows vertebral anomaly at D11 level with associated inhomogeneous intensity of the cord. (b) T2W image shows the same findings with dural sac abnormalities and spur delineation. (c) T2W coronal section shows hypo intense region of osseous spur.**



**Figure 5: MRI spine axial sections (a) T1W image at D11 level of beginning of splitting of the cord (white arrow). (b) T2W image at the level of split cord (vertical white arrow) (c) T2W image at the level where the cord is reuniting again (black upward arrow).**

The diagnosis of Type I diastematomyelia was made on these entire radiological spectrum. The patient has been kept under observation with conservative treatment at the moment as there was no bladder and bowel involvement

### DISCUSSION

This type of neural defect takes place in 15<sup>th</sup> and 18<sup>th</sup> week of pregnancy when the notochord fails to unite.<sup>[1]</sup> Split cord anomalies can be divided into two types for the purpose of description and symptomatology.<sup>[2]</sup> D Pang et al in 1992 introduced this classification for better understanding<sup>[3]</sup>.

#### Type I

With duplicate dural sac with osseous or fibrous spur .The patients are usually symptomatic

#### Type II

With single dural sac, which contains both the hemi cords, which are without any noticeable symptomatology. These types of hemi cords had their own anterior spinal arteries. These are usually without any bony spur and other defects.

Type I has got other associated anomalies of vertebrae in the form of hemi vertebra, spinabifida or butterfly vertebra. There is hypertrichosis on the back and pigmentation may be present. There is always kypho-scoliosis and tethered cord. These anomalies are noticed between the level of D9 and S1 vertebral column. 50% anomalies occur at L1-L3 level and 25% between D7-D12 level and slightly less at higher level.

Type II may have partially split cord within the single dural sac. This may be associated with hydromelia.

33% cases only show the fibrous or osseous septation on radiological investigations. The entity can be diagnosed in antenatal ultrasonography.<sup>[4]</sup> Plain radiography can pick up the findings like scoliosis, vertebral anomalies, widening of interpedicular distances and osseous septation. NCCT

can further delineate the findings in reconstruction formatted. MRI is the gold standard to exactly outline the cord anomalies associated with hydromelia if any<sup>[5]</sup>. The conus medullaris is usually seen below L2 level. The hemi cords unite in distal part and filum terminale is thickened along with tethered cord. The presentation of these patients is very rarely acute in onset.

## CONCLUSION

Diastematomyelia can easily be diagnosed with the various radiological modalities as it was in our case. Various clinical features can be correlated with the underlying anomalies. The management map becomes quite clear after knowing the exact type and grading by plain radiography, NCCT and MRI of spine.

## REFERENCES

1. Karasahin KE, Gezginc K, AlanbayI, Ulubay M, Baser I. Ultrasonographic diagnosis of Diastematomyelia during 14th week of gestation. Taiwan J Obstet Gynecol. 2009 Jun; 48(2);163-6.
2. Netto JMB, Bastos AN, Figueiredo AA, et al. Spinal dysraphism neurological review for the neurologist. Rev Urol. 2009 ;11(2):71-81.
3. Pang D, Dias MS, Ahab-BarmadaM. Split cord malformation. Part I: A unified theory of embryogenesis for double spinal; cord malformations. Neurosurgery. 1992;31:451-80.
4. Anderson NG, Jordan S, MacFarlane MR, et al. Diastematomyelia: diagnosis by prenatal sonography. AJR. 1994;163(4):911-4.
5. Rossi A, Biancheri R, Cama A, et al. Imaging in spine and spinal cord malformations. EJR.2004;50:177-200.

**How to cite this article:** Sharma BB, Sharma S, Sharma S, Sharma S, Ramachandran P. Split Cord Syndrome (Type 1 Diastematomyelia): A Case Report. Ann. Int. Med. Den. Res. 2016; 2(5):RD01-RD03.

**Source of Support:** Nil, **Conflict of Interest:** None declared