

## Macrodystrophia Lipomatosa- A Rare Congenital Anomaly: A Case Report and Review of Literature.

Sanjay Kumar Tripathi<sup>1</sup>, Saurav Narayan Nanda<sup>2</sup>, Shalesh kumar<sup>1</sup>, Nitin kumar Agrawal<sup>3</sup>, Shaikh Muzammil Shiraz<sup>2</sup>, Kumar Keshav<sup>3</sup>

<sup>1</sup>Senior resident, Department of Orthopaedics and Trauma, Teerthanker Mahaveer Medical College and Research Centre, Moradabad, Uttar Pradesh.

<sup>2</sup>Resident, Department of Orthopaedics & Trauma, Lilavati Hospital and Research Centre Mumbai, India.

<sup>3</sup>Assistant professor, Department of Orthopaedics and Trauma, Teerthanker Mahaveer Medical College and Research Centre, Moradabad, Uttar Pradesh.

Received: June 2016

Accepted: July 2016

**Copyright:** © the author(s), publisher. It is an open-access article distributed under the terms of the Creative Commons Attribution Non-Commercial License, which permits unrestricted non-commercial use, distribution, and reproduction in any medium, provided the original work is properly cited.

### ABSTRACT

Macrodystrophia lipomatosa is a rare presentation and only few cases are reported in scientific literature. We report a case of Macrodystrophia lipomatosa in a 7 year young girl from a tertiary care hospital Mumbai. Case presentation: A 7 year old female was presented to outpatient department with progressive enlargement of right lower limb with increase in size of right great toe since birth. On clinical examination there was non tender fluctuant soft tissue swelling with good functional limb. Scannogram showed reduction of the medial compartment of right knee joint and the right lower limb length was slightly longer compared to the left side with presence of soft tissue swelling on medial distal thigh and knee region. MRI showed un-encapsulated subcutaneous fatty tissue involving the entire right lower limb along its medial aspect up to the great toe with fatty infiltration of the vastus medialis muscle suggestive of macrodystrophia lipomatosa. Arterial and venous colour Doppler study of right lower limb was normal. Conclusion: Macrodystrophia lipomatosa is a rare congenital, non hereditary condition with localized macrodactyly and proliferation of mesenchymal element and marked increase in fibroadipose tissue. X-ray and MRI are investigation of choice. Doppler study shows normal vascularity.

**Keywords:** Macrodystrophia lipomatosa, Mesenchymal element, Fatty infiltration.

### INTRODUCTION

Macrodystrophia lipomatosa (MDL) is a rare congenital, non hereditary condition with localized macrodactyly and proliferation of mesenchymal element and marked increase in fibroadipose tissue. X-ray and MRI are investigation of choice. Only few cases are reported in scientific literature. We report a case of Macrodystrophia lipomatosa (MDL) in a 7 year young girl from our tertiary care hospital, Mumbai.

#### Name & Address of Corresponding Author

Dr. Sanjay Kumar Tripathi  
Senior resident,  
Department of Orthopaedics and Trauma,  
Teerthanker Mahaveer Medical College and Research  
Centre,  
Moradabad, Uttar Pradesh, India.  
E mail: drsanjaytrip@gmail.com

### CASE REPORT

A 7 year old female presented to Out Patient Department with progressive enlargement of right lower limb with increase in size of right great toe

since birth. On clinical examination there was non tender fluctuant soft tissue swelling involving a right mid thigh, medial aspect of knee to the great toe. [Figure 1, 2] There was an enlargement and Hyperextension of the great toe with slight Hallux valgus. [Figure 3] Good function of the limb was maintained and child was otherwise normal. There was no history of any injury, difficulty in walking or bleeding. The patient consulted many places in the past, but were not satisfied. Scannogram of right lower limb noted reduction of the medial compartment of right knee joint and the right lower extremity limb length was slightly longer compared to the left side with presence of soft tissue swelling in the medial distal thigh and knee region. [Figure 4] MRI showed un-encapsulated subcutaneous fatty tissue involving the entire right lower limb along its medial aspect up to the great toe with fatty infiltration of the vastus medialis muscle suggestive of macrodystrophia lipomatosa (MDL). Also right femur, tibia and fibula were larger in length as compared to the left side. Arterial and venous colour Doppler study of right lower limb was normal and do not show any evidence of deep vein thrombosis, incompetent perforators, sapheno-

femoral reflux or any stenosis. Histological examination showed proliferation of adipose tissue. The patient was explained about the procedures involving soft tissue and bony correction. But patient was lost in follow up, most probably due to his bad financial status.

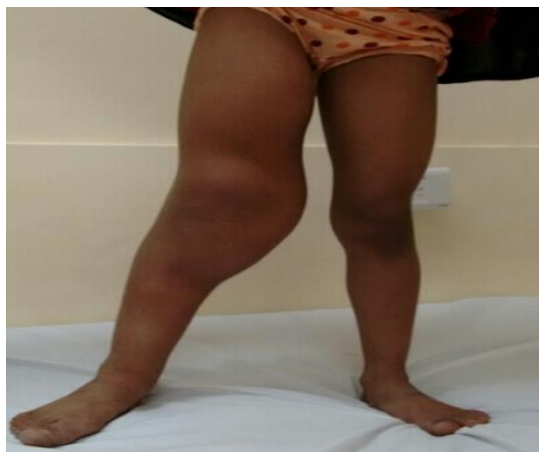

Figure 1: Clinical Photo (1).

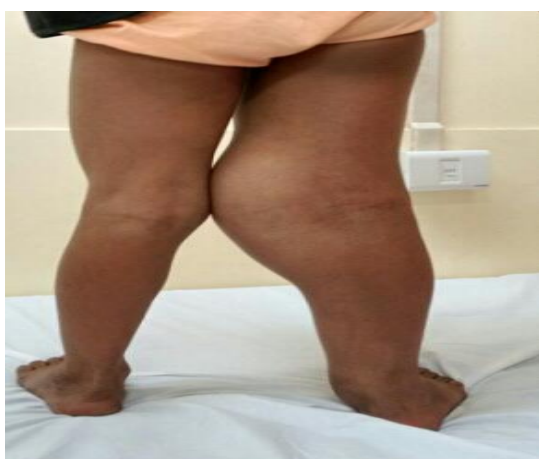


Figure 2: Clinical Photo (2).

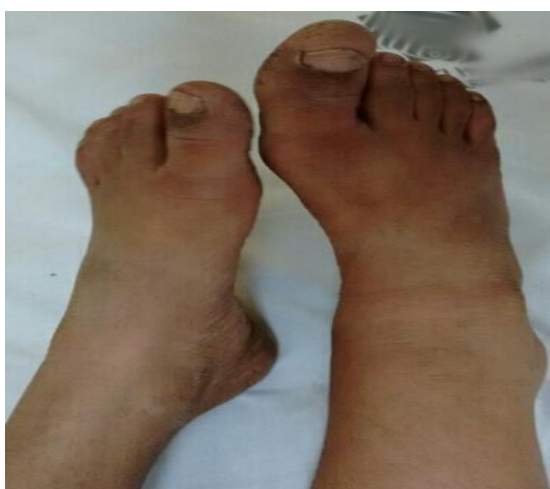

Figure 3: Clinical Photo (3).

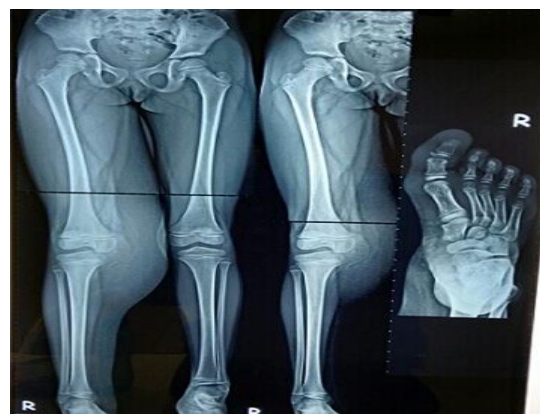

Figure 4: Scannogram of lower limb with X-ray right foot AP view.

## DISCUSSION

Macrodystrophia lipomatosa (MDL) is a rare non hereditary, congenital disorder of focal gigantism, with localized macrodactyly and the proliferation of mesenchymal element in the distribution of a sclerotome and marked increase in fibroadipose tissue affecting the extremities unknown etiology. It can affect both upper and lower limb. It occurs in the distribution of the median nerve in the upper extremity most commonly index and middle finger and in the distribution of medial plantar nerve in the lower extremity.<sup>[1]</sup> The most common presentation is unilateral lower limb involvement.

MDL term was first used by Feritz in 1925<sup>[2]</sup> which was further classified as static form and progressive form by Barsky. In former, size of the enlarged digit increase proportionally in relation to the rest of the body and in latter, growth of enlarged digit is disproportionate.<sup>[3]</sup> MDL can occur in association with polydactyly, syndactyly, brachydactyly or clinodactyly.

The histopathologic finding is infiltration and hypertrophy of adipose tissue in subcutaneous tissue, nerve sheath and periosteum. The proposed mechanism includes lipomatous degeneration, disturbance of growth inhibiting factors, disturbed fetal circulation, an error in segmentation and trophic influence of tumefied nerve. The pathogenesis of bony enlargement is thought to be because of endosteal and periosteal deposition of bone.<sup>[4]</sup>

Radiological investigations include X-ray, USG, Doppler, and MRI.

X-ray show lucent soft tissue overgrowth as well as hypertrophy of bony structures in the distribution of median and plantar nerve.

USG reveals large amounts of subcutaneous tissue, infiltration of the muscle, thickening of affected nerves.

Doppler studies show no sign of any increased vascularity.

Blackskin *et al.* were the first to describe the MR findings of this entity.<sup>[5]</sup> MRI, owing to its inherently excellent soft-tissue contrast, is of great value in demonstrating excess fibro-fatty tissue, which has signal characteristics similar to subcutaneous fat, MRI shows high signal intensity on T1-weighted, intermediate signal on T2-weighted, and low signal on fat-suppressed. This fat is not encapsulated, as opposed to a lipoma. MRI can also well demonstrate fatty infiltration of the muscles, bony overgrowth and cortical thickening. Linear hypointense bands within the excess fatty tissue, representing fibrous strands, are well visualized.<sup>[1]</sup> MRI can be useful to rule out other differential diagnoses like fibrolipomatous hamartoma of a nerve, neurofibromatosis type 1, haemangiomas, lymphangiomas, Proteus syndrome, Beckwith-Wiedemann syndrome and Klippel-Trenaunay-Weber syndrome that includes macrodactyly with haemangiomas. Treatment goals are for cosmetic purpose and maintaining nerve and joint function by minimizing local tissue trauma. Surgical management includes debulking, epiphysiodesis and osteotomy.

## CONCLUSION

Macro dystrophia lipomatosa is a rare congenital, non-hereditary condition with localized macrodactyly and proliferation of mesenchymal element and marked increase in fibroadipose tissue. X-ray and MRI are investigation of choice. In cases where the hypertrophy of involved tissue is not marked, the condition may be missed or diagnosed incorrectly. In such case MRI is the investigation of choice. Patient may need surgical correction for cosmetic reasons.

### Clinical Message:

X-ray and MRI are investigation of choice in case of MDL. In cases where the hypertrophy of involved tissue is not marked, the condition may be missed or diagnosed incorrectly. In such case MRI is the investigation of choice. Patient usually seeks surgical correction for cosmetic reasons involving soft tissue and bone in staged procedure.

## REFERENCES

1. Sone M, Ehara S, Tamakawa Y, Nishida J, Honjoh S. Macro dystrophia lipomatosa: CT and MR findings. *Radiat Med.* 2000; 18:129-32.
2. Feriz H. Macro dystrophia lipomatosa progressiva. *Virchow's Arch.* 1925; 260: 308-368.
3. Boren WL, Henry REC, Wintch K. MR diagnosis of fibrolipomatous hamartoma of nerve: association with nerve territory-oriented macrodactyly (Macro dystrophia lipomatosa). *Skeletal Radiol.* 1995; 24:296-297.
4. Gupta SK, Sharma OP, Sharma SV, Sood B, Gupta S. Macro dystrophia lipomatosa: radiographic observations. *BJR.* 1992; 65:769-773.

5. Blackskin M, Barnes FJ, Lyons MM: MR diagnosis of macro dystrophia lipomatosa. *Am J Roentgenol.* 1992; 158: 1295-1297.

**How to cite this article:** Tripathi SK, Nanda SN, Kumar S, Agrawal NK, Shiraz SM, Keshav K. Macro dystrophia Lipomatosa- A Rare Congenital Anomaly: A Case Report and Review of Literature *Ann. Int. Med. Den. Res.* 2016; 2(5):OR01-OR03.

**Source of Support:** Nil, **Conflict of Interest:** None declared