

# A Rare Case of Retropharyngeal Abscess by *Salmonella* Typhimurium in Central India.

Chavan Sonal P<sup>1</sup>, Meshram Rupali B<sup>2</sup>, Raut Sharmila S<sup>3</sup>, Vedi Jeevan N<sup>4</sup>

<sup>1</sup>Assistant Professor, Dept of Microbiology, Indira Gandhi Govt. Med. College, Nagpur.

<sup>2</sup>JR-3, Dept of Microbiology, Indira Gandhi Govt. Med. College, Nagpur.

<sup>3</sup>Professor & Head, Dept of Microbiology, Indira Gandhi Govt. Med. College, Nagpur.

<sup>4</sup>Professor & Head, Dept of ENT, Indira Gandhi Govt. Med. College, Nagpur.

Received: August 2016

Accepted: August 2016

**Copyright:** © the author(s), publisher. It is an open-access article distributed under the terms of the Creative Commons Attribution Non-Commercial License, which permits unrestricted non-commercial use, distribution, and reproduction in any medium, provided the original work is properly cited.

## ABSTRACT

Retropharyngeal abscess (RPA) is an infection in the retropharyngeal space of neck. It is rare in adults and can occur as a result of local trauma, foreign body ingestion, or instrumental procedures. Abscesses in this space can be caused by aerobic, anaerobic, or Gram-negative organisms. *Salmonella* neck infections represent an uncommon cause of focal salmonellosis. It may develop in uncontrolled diabetic or immunocompromised, patients without any preceding intestinal manifestation of the disease. While the incidence of non-typhoidal salmonellosis (NTS) is estimated at over two million cases annually, extra intestinal manifestation account in less than 1 % of these cases. Here, we report a case of RPA due to *Salmonella enterica* subsp. *enterica* serovar Typhimurium in a 50-year-old female from Central India. IV antibiotics should be considered along with surgical drainage and treatment of the comorbidity. Early diagnosis and intervention are imperative to avoid mortality.

**Keywords:** Adult, Diabetes, Retropharyngeal abscess, *Salmonella* Typhimurium.

## INTRODUCTION

A Retropharyngeal abscess (RPA) is an infection in the retropharyngeal space of the neck. RPA are rare in adults and can occur as a result of local trauma, such as foreign body ingestion (fishbone), or instrumental procedures (laryngoscopy, endotracheal intubation, feeding tube placement, etc.), or in the particular context of an associated disease.<sup>[1]</sup> *Salmonella* neck infections represent an uncommon cause of focal salmonellosis.<sup>[2]</sup> While the incidence of non typhoidal salmonellosis (NTS) is estimated at over 2 million cases annually, extra-intestinal manifestation account in less than 1 % of these cases.<sup>[3]</sup>

Pastalgia et al reported a sternocleidomastoid abscess and a parapharyngeal abscess by NTS.<sup>[3]</sup> Anwar et al reported a case of neck abscess due to *Salmonella* with septicemia and death as a complication.<sup>[2]</sup> Overall, RPA due to NTS in adults has not been reported from Central India till date. We report a rarest case of RPA due to *Salmonella* Typhimurium in an adult female patient.

### Name & Address of Corresponding Author

Dr. Meshram Rupali B  
JR-3,  
Department of Microbiology,  
Indira Gandhi Govt. Med. College, Nagpur.

## CASE REPORT

A 50 years old female was admitted with the chief complaints of difficulty in swallowing, painful neck swelling and fever since 6–8 days. Difficulty in swallowing was initially for solids, but then gradually progressed to liquids. The swelling was gradually enlarging in size with a frequent local throbbing type of pain radiating to the right ear. Fever was high grade and intermittent. She had no history of abdominal pain, diarrhoea, weight loss or loss of appetite. No history of raw milk consumption, intravenous drug use and no pets at home. No history of diabetes mellitus, tuberculosis, hypertension. She denied any dental trauma or insect bite. She was laborer by occupation and the bowel habits were unhygienic.

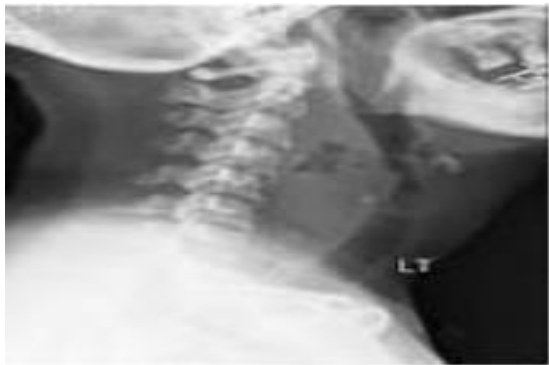
On general examination, she was mildly anemic; body temperature was 101<sup>0</sup> F, pulse rate - 102/min and blood pressure within normal limits. No other systemic findings. Local examination revealed a tender, non fluctuant mass in the right side of the neck. Oral cavity revealed good dentition. A bulge was seen in the posterior pharyngeal wall with inclination towards the right.

Laboratory findings revealed a white blood cell count of 12,600/dl, with 82% neutrophils, and serum glucose of 215 mg/dl. HbA1C level was elevated at 9.6%. USG of neck and physical examination revealed a retropharyngeal abscess. HIV and HBsAg status was negative.

Incision and drainage of the abscess was done under general anesthesia. Purulent discharge of 30 cc was evacuated and sent for culture. The patient was started with Metronidazole, Amikacin twelve hourly and insulin for blood glucose control.

Gram stain of the abscess revealed Gram-negative bacilli. The sample was inoculated on blood agar and MacConkey agar and incubated at 37°C for 24 hours. The pure growth of non-haemolytic and non-lactose fermenting colonies were observed. The TSI slant result was alkaline/acid with the production of hydrogen sulphide gas. The colonies were identified as those of *Salmonella enterica* subsp. *Enteric* serovar Typhimurium based on standard biochemical tests<sup>[4]</sup> and confirmed with *Salmonella* polyvalent O antiserum and *Salmonella* O4 and Hi antiserum (Central Research Institute, Kasauli) agglutination. Antibiotic susceptibility testing (AST) was performed on Mueller Hinton agar by Kirby-Bauer disc diffusion method.<sup>[5]</sup> The isolate was found to be sensitive to ampicillin, ceftriaxone, ciprofloxacin, chloramphenicol, nalidixic acid and cotrimoxazole as per CLSI Guidelines.<sup>[6]</sup>

However, the organism was not grown in blood culture, stool or urine cultures. A repeat pus sample in the second attempt of complete aspiration showed the growth of the same organism. The patient was started with IV Ceftriaxone 1 gram twice a day as per AST. The patient was discharged after 5 days with shift on oral quinolone and metformin for glucose control. The patient was alright in the follow up without any complications.



**Figure 1: Lateral view of Xray neck-showing increase in retropharyngeal space.**

## DISCUSSION

RPA are deep neck space infections that can pose an immediate life-threatening emergency, with potential for airway compromise and other catastrophic complications.<sup>[7]</sup> The high mortality rate associated with RPA is due to its association with airway obstruction, mediastinitis, aspiration pneumonia, epidural abscess, jugular venous thrombosis, necrotizing fasciitis, sepsis, and erosion into the carotid artery.<sup>[1]</sup> Abscesses in this space can be caused by many organisms such as aerobic

organisms (beta-hemolytic *Streptococci* and *Staphylococcus aureus*), anaerobic organisms (species of *Bacteroides* and *Veillonella*), or Gram-negative organisms (*Haemophilus parainfluenzae* and *Bartonellahenselae*).<sup>[1]</sup> *Salmonella* can very rarely cause focal infection like neck abscess, lung abscess, bone infection etc. In neck infection, *Salmonella* may act as an oxygen consumer in the infected tissue facilitating the growth of anaerobic cocci, hence the development of a devastating soft tissue.<sup>[2]</sup> Remote abscesses are the result of hematogenous or lymphatic dissemination of primary gastrointestinal tract infections.<sup>[8]</sup>

The clinical diagnosis of RPA can be difficult; the clinical symptoms are variable and nonspecific. The signs of infection may be lacking in certain situations of immune suppression such as diabetes.<sup>[11]</sup> However, in our study, the patient with diabetes was febrile and had difficulty in swallowing with bulging of the pharyngeal wall.

In the present case, the patient was immunosuppressed as she was diagnosed as diabetic. She developed a RPA due to *S. Typhimurium*. Pastalgia et al reported a sternocleidomastoid abscess due to *S. Enteritidis* and parapharyngeal abscess due to *S. Typhimurium* in diabetic.<sup>[3]</sup> Other types of neck abscesses involving *Salmonella* spp. have been described in the literature. Luo and Liu demonstrated two cases of neck abscess and necrotizing fasciitis caused by *S. enteritidis* in diabetic patients respectively.<sup>[9]</sup> Anwar et al reported a case of neck abscess due to *Salmonella* with septicaemia as complication.<sup>[2]</sup> Gudipati and Westblom reported a thyroid abscess due to *S. Typhimurium*.<sup>[10]</sup>

This particular case highlights the fact that NTS can be etiologic agents of focal infections, more so in patients with underlying immunosuppression. To our Knowledge this is the 1<sup>st</sup> case of RPA due to *S. Typhimurium* in adults, reported from Central India. Diagnosis of RPA is based on the clinical, radiological findings and comorbidities. Limited drugs choices are left as Aminoglycosides, 1<sup>st</sup> & 2<sup>nd</sup> generation Cephalosporins and Cephamycins may appear active in vitro but not effective clinically against *Salmonella* as per CLSI guidelines.<sup>[6]</sup> IV antibiotics should be considered along with surgical drainage and treatment of the comorbidity.

## CONCLUSION

Early diagnosis and intervention are imperative to avoid mortality.

### Acknowledgement

Staff of Department of Microbiology, Department of E.N.T.

## REFERENCES

1. Harkani A, Hassani R, Zaid T, Aderdour L, Nouri H, Rochdi Y, and Raji A. Retropharyngeal abscess in adults: five case reports and review of the Literature. *The Scientific World Journal*. 2011;11: 1623-29.
2. Anwar MM, Ahmed TU. Salmonella neck abscess: A case report. *Journal of Chittagong Medical College Teacher's Association*. 2009;20:61-3.
3. Pastagia M, Jenkins S. Salmonella neck abscess as an opportunistic infection in diabetes mellitus. *Case reports in Infectious Diseases*. 2013;1-5.
4. Collee JG, Duguid JP, Fraser AG, Marmion BP, Simmons A. Laboratory strategy in the diagnosis of infective syndromes. In: Collee JG, Fraser AG, Marmion BP, Simmons A eds. *Mackie and McCartney practical medical microbiology*. 14<sup>th</sup> ed, Churchill Livingstone. 2014; 53-94.
5. Bauer AW, Kirby WMM, Sherris JC, Turck M. Antibiotic susceptibility testing by standardised single disk method. *Am J Clin Pathol*. 1966; 45: 49-56.
6. CLSI 2015: Performance standard for Antimicrobial Susceptibility Testing; Twenty-fourth informational supplement; M100-S24. Vol.34 No.1 Clinical and laboratory standard institute, Wayne, PA, USA.
7. Acevedo JL and Shah RK. Retropharyngeal Abscess. *eMedicine Specialties, Pediatrics: Surgery, Otolaryngology*. 2009.
8. Patrick ME, Adcock PM, Gomez TM et al., Salmonella enteritidis infections, United States, 1985–1999. *Emerging Infectious Diseases*. 2004; 10:1,1–7.
9. Luo CW, Liu CJ. Neck abscess and necrotizing fasciitis caused by Salmonella infection: a report of 2 cases. *Journal of Oral and Maxillofacial Surgery*. 2007;65:1032-4
10. Gudipati S and Westblom TU, Salmonellosis initially seen as a thyroid abscess. *Head and Neck*. 1991;13:153–5.

**How to cite this article:** Sonal CP, Rupali MB, Sharmila RS, Jeevan VN. A Rare Case of Retropharyngeal Abscess by *Salmonella* Typhimurium in Central India. *Ann. Int. Med. Den. Res.* 2016; 2(6):MB01-MB03.

**Source of Support:** Nil, **Conflict of Interest:** None declared