

Neurovascular Relation and Origin of Medial Calcaneal Nerve in the Tarsal Tunnel in Embalmed Cadavers of Eastern India.

Binod Kumar Tamang¹, Pranoti Sinha¹, Karma Lakhi Bhutia¹, Rohit Kumar Sarma¹

¹Department of Anatomy, Sikkim Manipal Institute of Medical Sciences, 5th Mile, Tadong, Gangtok, Sikkim.

Received: October 2016

Accepted: October 2016

Copyright: © the author(s), publisher. It is an open-access article distributed under the terms of the Creative Commons Attribution Non-Commercial License, which permits unrestricted non-commercial use, distribution, and reproduction in any medium, provided the original work is properly cited.

ABSTRACT

Background: The tarsal tunnel is situated medial to the ankle between the posterior border of medial malleolus and the medial tubercle of calcaneum underlying deep to the flexor retinaculum. Compression of neurovascular bundle in the tarsal tunnel leads to various clinical condition like chronic heel pain, tarsal tunnel syndrome and other diseases related to podiatric medicine. **Aims and Objectives:** To study the relationship and the bifurcation level of Tibial nerve and the Posterior tibial artery and the branching pattern of tibial nerve in the tarsal tunnel of the embalmed cadavers from eastern India. **Methods:** Routine dissection was carried out in 30 adult lower limbs. The relationship and the point of bifurcation of posterior tibial artery and the tibial nerve were recorded. The number and the source of origin of medial calcaneal nerve was observed. For the classification of the bifurcation point of the artery and the nerve a 1cm broad reference line called Medio-malleolar calcaneal axis (MMC axis) was used as a grid and was grouped as type I, II and III. **Results:** In majority of the cases the tibial nerve and the posterior tibial artery bifurcated within the tarsal tunnel. Tibial nerve bifurcation was always proximal to the tibial artery within a distance ranged from 0.5 to 3.5cm. With reference to the Medio-malleolar- calcaneal axis the commonest type of bifurcation observed was type II in posterior tibial artery and type I in tibial nerve. The number of medial calcaneal nerve was ranged from 1 to 3 and was taking origin either from tibial nerve, lateral planter nerve or both. Except in one case all the medial calcaneal branches arose within the tarsal tunnel. **Conclusion:** Posterior tibial artery is always superficial to the tibial nerve with a varying level of bifurcation in the tarsal tunnel. The medial calcaneal nerve are variable in number and arises from lateral planter nerve, tibial nerve or both. It has the clinical implication in the management of surgical condition like tarsal tunnel syndrome, fractures in the ankle region as well as for carrying out procedure like nerve block.

Keywords: Tarsal tunnel, Tibial nerve, Posterior tibial artery.

INTRODUCTION

The neurovascular bundle along with the tendons of extrinsic muscles of the sole passes through the tunnel which is present in between the posterior aspects of medial malleolus and medial aspect of calcaneum. The tunnel is known as tarsal tunnel and is situated medial to the ankle, lying deep to the flexor retinaculum. It transmits the tendon of tibialis posterior, flexor digitorum longus, posterior tibial vessels, tibial nerve (TN) and their termination and tendon of flexor hallucis longus.^[1]

The posterior tibial artery (PTA) is accompanied by two veins and Tibial nerve. Terminally it is deep to flexor retinaculum and abductor hallucis. Further deep to the flexor retinaculum the nerve vessels and tendons lies in separate compartments.^[2] The medial calcaneal nerve is a branch of the posterior tibial nerve or lateral planter nerve with a wide range of branching point.^[3]

In podiatric medicine knowledge about the anatomical location, bifurcation and the branching pattern of TN and its relationship with the bifurcation of PTA and any variation in the tarsal tunnel is necessary for the management of various clinical conditions like chronic heel pain, tarsal tunnel syndrome, fractures in the tarsal regions, nerve block etc. With the available cadavers used for teaching MBBS students the present study was undertaken to observe the branching pattern and the bifurcation of TN and its relationship with the bifurcation of PTA.

Name & Address of Corresponding Author

Dr. Binod Kumar Tamang
Professor,
Department of Anatomy,
Sikkim Manipal Institute of Medical Sciences,
5th Mile, Tadong,
Gangtok, Sikkim.

MATERIALS AND METHODS

The study was carried out in 30 lower limbs of adult cadavers irrespective of gender and anatomical side. The lower limbs with any gross injuries or deformities of the foot were excluded from the study. The dissection was carried out by giving longitudinal incision of the posterior crural region extending up to the heel followed by the removal of skin and the superficial fascia over the region of tarsal tunnel well below up to the medial margin of the sole. The deep fascia was identified and traced below to identify the formation of flexor retinaculum. The vertical incision was given over the flexor retinaculum to expose the fibrous compartment which was underlying deep to it.^[2] Keeping the foot placed perpendicular to tibia in anatomical position the neurovascular bundle was identified and slowly separated from its surrounding fascia from distal leg till the sole. The relationship and the point of bifurcation of posterior tibial artery and the tibial nerve were recorded. The number and the source of origin of medial calcaneal nerve was observed. For the classification of the bifurcation point of the artery and the nerve a 1cm broad reference line called Medio-malleolar calcaneal axis (MMC axis) was used as a grid and was grouped as type I, II and III as described by Bilge et al^[4] MMC axis was drawn by using two cotton thread tied in sharp needle and fixed at 1cm apart extending from the tip of the medial malleolus to the medial tubercle of the calcaneum [Figure 1]. Type I, II and III represented proximal to, deep to, and distal to this axis respectively. In order to define the extent of tarsal tunnel and to define the bifurcation level of nerve and the vessels the present study also referred the technique used by Torres et al. where they included the area of 2cm proximal and distal to the MMC axis as the extent of tarsal tunnel.^[5]

RESULTS

Although the flexor retinaculum over the tarsal tunnel was identified by their thick fibre arrangements but their extent was difficult to define as they blend unnoticeably with the surrounding deep fascia. This finding is in agreement with various previous workers.^[1,2,6] On exposure of the flexor retinaculum the nerve and the vessels were wrapped in a separate fibrous sheath and were also separate from the neighbouring tendons running in their own fibrous tunnel. On dissection of the neurovascular bundle in the tarsal tunnel the PTA was running superficial to the TN and the bifurcation point of tibial artery was overlapping the bifurcation of tibial nerve in most of the cases [Figure 2]. In the present study the TN and the PTA were bifurcating with in the tarsal tunnel in all the cases except in one case where the tibial nerve was bifurcated at higher level just outside the tunnel as defined by Torres et al. but the tibial artery was bifurcating within the tunnel. With reference to the MMC axis and according to the Bilges classification the PTA bifurcation was of Type II in 28 cases (93.3%), Type III in 2(6.6%) cases and TN bifurcation was of type I in 27(90%) and type II in 3 (10%) of the cases. Type I in PTA and Type III in TN was not seen in any of the 30 cases. [Table1] The bifurcation of TN was proximal to the bifurcation of PTA and the distance between the point of bifurcation between PTA and TN were ranged from 0.5cm to 3.5cm. Medial calcaneal nerves (MCN) was originating from variable position and their number ranged from 1 to 3 branches [Figure 3]. In 17(56.6%) cases the MCN was given by Lateral planter nerve and in 13(43.33%) cases it was given by both tibial and lateral planter nerve. Single MCN was seen in 7(23.33%), two MCN in 16(53.33%) and three MCN in 7(23%). Most of the MCN originated within the tarsal tunnel at a distance of 0.5cm to 2cm proximal to the MMC axis except in one case where single MCN arose 3.5cm proximal to the MMC axis.

Table 1: Showing bifurcation of posterior tibial artery and tibial nerve in relation to the MMC axis.

Authors	Posterior tibial artery			Tibial nerve		
	Type I	Type II	Type III	Type I	Type II	Type III
Bilge et al.2003	10%	44%	46%	85.2%	14.7%	0.89%
Joshi et al.2006	16.17%	72.04%	11.76%	84%	12%	4%
D Malar 2016	-	-	-	85%	10%	5%
Present study	3.33%	86.66%	10%	90%	10 %	Nil

MMC-Medio-malleolar- Calcaneal axis.

Table 2: Studies showing different findings in the number of branches of medial calcaneal nerve.

Authors	1MCN	2MCN	3MCN	4MCN
Dellon et al.2002	37%	41%	19%	3%
Nidye et al. 2003	80%	20%	-	-
Joshi et al.2006	41.96%	41.96%	15.1%	0.89%
D Malar 2016	50%	30%	20%	Nil
Present study	23%	53%	23.33%	Nil

MCN- Medial calcaneal nerve.

DISCUSSION

Various authors have studied about the tarsal tunnel, its neurovascular relationship, branching pattern and the termination of Tibial nerve.^[2,4,6,7] The present study was carried out to study the same in embalmed cadavers from eastern India and to compare the findings with previous studies. The branching pattern of tibial nerve in the tarsal tunnel are useful for explaining the pathologies associated with chronic heel pain caused by the nerve compression.^[8]

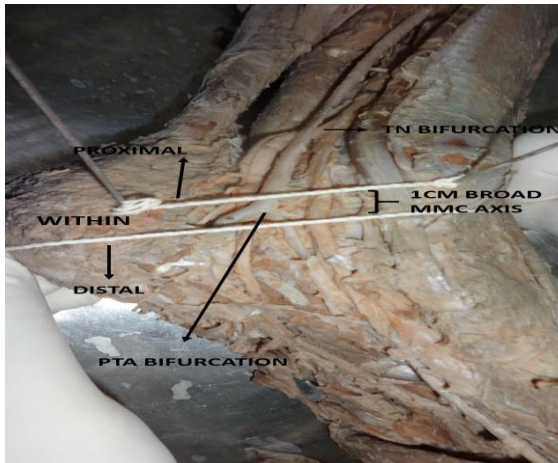


Figure 1: Showing the MMC axis (Medio-Malleolar Calcaneal axis) and higher bifurcation of Tibial nerve.

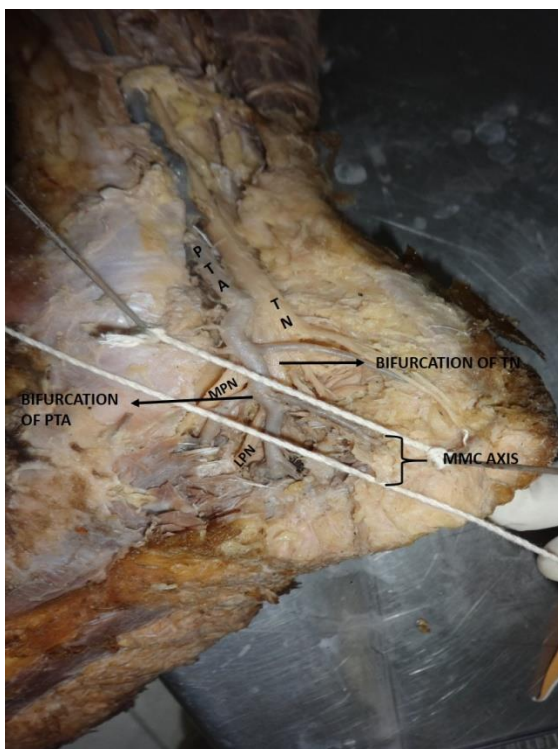


Figure 2: Showing the bifurcations of posterior tibial artery and tibial nerve within and above the axis. (PTA- Posterior tibial artery, TN- Tibial nerve, MPN – Medial Planter nerve, LPN- Lateral Planter nerve)

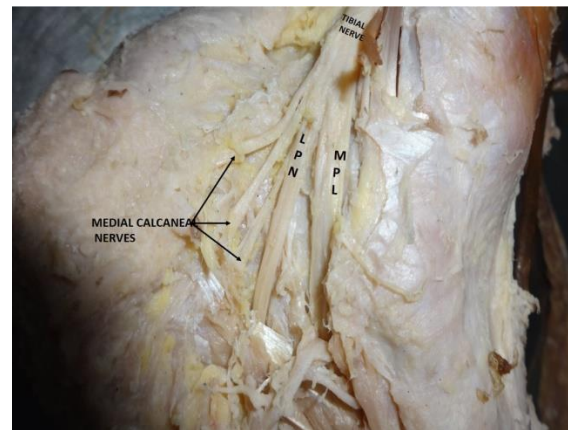


Figure 3: Showing the origin of medial calcaneal nerve. (LP- Lateral planter nerve, MP-Medial Planter nerve).

PTA with its venaecomitantes were superficial to TN in all the cases as described by the previous author.^[2] In the present study the TN and the PTA were bifurcating within the tarsal tunnel except in one case where the tibial nerve bifurcated at a higher level just outside the tunnel as defined by Torres et. al but the tibial artery was bifurcating within the tunnel. The bifurcation of TN was proximal to the bifurcation of PTA in all the cases and the distance between them were ranged from 0.5cm to 3.5cm. This finding matched with the findings of Bilge et al. and Joshi but in disagreement with the statements given by the authors McMinn and Dutta as quoted by Joshi et al.^[2] With reference to the MMC axis and according to the Bilges classification in the present study PTA bifurcation was of Type II in 28 cases (93.3%), Type III in 2(6.6%) cases and type I was not seen in any of the cases but Bilge et el in their study they have recorded maximum of type III (46%) followed by type II (44%) and Type I (10%). Similarly in another study by Joshi et. al it was recorded as 72.04% of Type II followed by 16.17% of type I and 11.76% of type III. The present finding did not matched with the finding of Bilge et al. but somewhat matched with the finding of Joshi et al. where the maximum percentage of PTA bifurcation were of Type II. Similarly TN bifurcation was of type I in 27(90%) and type II in 3 (10%) of the cases and Type III were not seen in any of the 30 cases. Various authors have recorded the bifurcation of TN within 1 to 2 cm of the MMC axis in 90% of the cases.^[9-11] Since the methodology adopted in the present study was referred from the work done by Bilge et al. the comparative table shows the finding of Posterior tibial artery and tibial nerve bifurcation with respect to MMC axis by certain authors [Table 2]. The present findings almost corresponds to the findings of the previous authors except Type III

tibial nerve bifurcation that was not seen in any of the cases whereas they have recorded in minimal percentages.^[2,4,6] Various workers have described about the variable numbers and its branching pattern of Medial Calcaneal nerve (MCN). In the present study Medial calcaneal nerve were either originating from tibial nerve, lateral planter nerve or both. In the majority of the cases 53% had three medial calcaneal nerve and 23.33% each had one and two MCN .Single MCN was the branch of lateral planter nerve in all the 23.33% cases. Figure 3 shows the comparative finding of number of MCN by various author. Dellon et al. has reported in his study the origin of MCL in 46% cases but it was not seen in the present study.^[7]

CONCLUSION

Posterior tibial artery is always superficial to the tibial nerve with a varying level of bifurcation in the tarsal tunnel. The medial calcaneal nerve are variable in number and arises from lateral planter nerve, tibial nerve or both .Knowledge about the neurovascular relation and the branching pattern of tibial nerve in the tarsal tunnel is very important for various procedure like nerve block, surgery for the treatment of tarsal tunnel syndrome and fractures in the tarsal region. Some of the findings in the present study were not fully resembling to the work done by a few authors which may further reinforce the variable nature in the branching pattern and the bifurcation of nerve and vessels in the tarsal tunnel.

REFERENCES

1. Standring S, Ellis H, Healy JC, Johnson D, Williams A et al. The Anatomical basis of clinical practice. Gray, s Anatomy, 39th edn London: Churchill Livingstone, 2005; 1508.
2. Joshi SS, Joshi SD, Athavale SA. Anatomy of Tarsal tunnel and its applied significance. J. Anat. Soc. India, 2006; 55(1):52-56.
3. Beom Suk Kim, Phil Woo Choung, Soon Wook Kwon, Im Joo Rhyu, Dong Hwee Kim . Branching pattern of medial and inferior calcaneal nerves around the Tarsal tunnel. Ann. Rehabil Med. 2015 Feb; 39(1):52-55
4. Bilge O, Ozer M A, Govsa F. Neurovascular branching in the tarsal tunnel. Neuroanatomy, 2003, Volume 2, page 39-41 .
5. Torres ALG, Ferreira MC. Study of anatomy of tibial nerve and its branches in the distal medial leg. Acta orthopedica Brasileria. 2012; 20(3):157-164.
6. D malar. A study of tibial nerve bifurcation and branching pattern of calcaneal nerve in the tarsal tunnel. Int J Anat Res 2016; 4(1):2034-2036.
7. Dellon A L, Kim J, Spaulding CM. Variation in the origin of medial calcaneal nerve. J Am Podiatr med Assoc. 2002 Feb; 92(2):97-101
8. S Louisia, A. c Masquelet. The medial and inferior calcaneal nerve: an anatomic study. May 1999, vol 21, issue 3, pp 169-173.

9. Dellon A L, Mackinnon S E. Tibial nerve branching in the tarsal tunnel. Tibial nerve branching in the tarsal tunnel. Arch Neurol 1984 Jun; 41(6):645-46.
10. Ndiaye A, Dia A, Konate I, Diop M, Sow ML. Topographic anatomy of the tibial nerve in the medial malleolus: application to the effect of nerve block anesthesia. Morphologie, 2003; 87(277):25-27.
11. Davis TJ, Schon LC. Branches of the tibial nerve: anatomic variation. Foot Ankle Int. 1995; 41(6):645-646.

How to cite this article: Tamang BK, Sinha P, Bhutia KL, Sarda RK. Neurovascular Relation and Origin of Medial Calcaneal Nerve in the Tarsal Tunnel in Embalmed Cadavers of Eastern India. Ann. Int. Med. Den. Res. 2016; 2(6):AT19-AT22.

Source of Support: Nil. **Conflict of Interest:** None declared