

# Effect of Crude Extract of *Moringa Oleifera* Lam on Skin and Muscle Tissues of Abino Rats and on *Pseudofolliculitis Barbae* in Human.

Omorodion, Nosa Terry<sup>1</sup>, Achukwu, Peter Uwadiegwu<sup>2</sup>, Ibeh, Isaiah Nnanna<sup>3</sup>

<sup>1</sup>Lecturer, Department of Medical Laboratory Science, School of Basic Medical Sciences, University of Benin, Benin City, Nigeria.

<sup>2</sup>Associate Professor, Department of Medical Laboratory Science, Faculty of Health Sciences and Technology, University of Nigeria, Enugu Campus, (UNEC) Nigeria.

<sup>3</sup>Principal Medical Laboratory scientist, National Veterinary Research Institute, Diagnostic Laboratory, Ibadan, Nigeria.

Received: October 2016

Accepted: October 2016

**Copyright:** © the author(s), publisher. It is an open-access article distributed under the terms of the Creative Commons Attribution Non-Commercial License, which permits unrestricted non-commercial use, distribution, and reproduction in any medium, provided the original work is properly cited.

## ABSTRACT

**Background:** *Moringa oleifera* Lam similar to *Moringa pterygosperma* Gaertner belongs to family of shrubs and tree, Moringaceae and is considered to have its origin in Agra and Oudh, in the northwest region of India. The Indians knew that the seeds contain edible oil and they used them for medicinal purposes. *Moringa* preparations have been cited in the scientific literature as having antibiotic, antitrypanosomal, hypotensive, antispasmodic, antiulcer, anti-inflammatory, hypocholesterolemic, and hypoglycemic activities, as well as having considerable efficacy in water purification. The scientific literature with respect to *moringa* continues to grow rapidly, particularly in the area of medicine, human and animal nutrition but no previous work has been done on the use on *Pseudofolliculitis barbae* (after shave rash). Hence, this herbal preparation will be of economic value to the Nigeria community in the removal of *Pseudofolliculitis barbae* (after shave rash). **Methods:** The general objective of this research work was carried out to investigate the safety of *moringa oleifera* on the skin and muscle tissues and to ascertain the medicinal effect on after shave rash. The specific objectives were to: (i) investigate the degree of safety of *Moringa oleifera* on skin and muscle tissues and (ii) investigate the curative effect of crude extract of *Moringa Oleifera* on *Pseudofolliculitis barbae* (after shave rash). The photomicrograph from the skin biopsies taken from the albino rats reveals that there were no histological changes to the tissues when compared with the control slide. **Results:** The slides reveals no histological changes to the epithelia lining, inflammation or any form of histological changes or cellular infiltration to the skin of the rats. The photomicrograph of skeletal, smooth and cardiac muscle tissues reveals that there was no cellular infiltration, toxic effect or histological changes to the various muscular tissues when compare with the photomicrograph from the control slides. Microscopically, both the aqueous extract and boiled decoction did not cause any histological changes to both skin and muscular tissues as revealed by the photomicrograph. The formed paste was able to effect total removal of the rash when used on the consented individual within day 2 and day 3 of usage. **Conclusion:** *Moringa oleifera* extract has the ability of removing after shave rash (*Pseudofolliculitis barbae*).

**Keywords:** *Moringa Oleifera* Lam. *Pseudofolliculitis Barbae*.

## INTRODUCTION

*Moringa oleifera* Lam similar to *Moringa pterygosperma* Gaertner belongs to family of shrubs and tree, Moringaceae and is considered to have its origin in Agra and Oudh, in the northwest region of India<sup>[2]</sup>.

### Name & Address of Corresponding Author

Omorodion, Nosa Terry  
Lecturer,  
Department of Medical Laboratory Science,  
School of Basic Medical Sciences, University of Benin,  
Benin City, Nigeria.

The Indians knew that the seeds contain edible oil and they used them for medicinal purposes<sup>[1]</sup>. *Moringa* preparations have been cited in the scientific literature as having antibiotic, antitrypanosoma<sup>[1]</sup>, hypotensive, antispasmodic, antiulcer, anti-inflammatory, hypocholesterolemic, and hypoglycemic activities, as well as having considerable efficacy in water purification<sup>[1,2]</sup>. The scientific literature with respect to *moringa* continues to grow rapidly, particularly in the area of medicine, human and animal nutrition but no previous work has been done on the use on *Pseudofolliculitis barbae* (after shave rash). Hence, this herbal preparation will be of economic value to the Nigeria community in the removal of

*Pseudofolliculitis barbae* (after shave rash). The general objective of this research work was carried out to investigate the safety of *moringa oleifera* on the skin and muscle tissues and to ascertain the medicinal effect on after shave rash. The specific objectives were to: (i) investigate the degree of safety of *Moringa oleifera* on skin and muscle tissues and (ii) investigate the curative effect of crude extract of *Moringa Oleifera* on *Pseudofolliculitis barbae* (after shave rash).

## MATERIALS AND METHODS

Standard method of extraction was used in the course of this investigation. The leaves were collected, washed and cleaned properly and placed in a flat bottom flask before application of heat. To obtain the boiled decoction 1 litre of distilled water was added to 500g of freshly collected leaves of *Moringa* species and allowed to heat for 20 minutes, using a gas cooker. After the extraction is done by heat, the decoction was left to cool and filtered using Whatman No 1 filter paper and was kept in a refrigerator at 4 degree centigrade for the period of the research. The leaves of the moringa plant were collected and dried under shade and ground into powder. The powder (200g) was collected and macerated in 70% ethanol at room temperature in 24 hours. It was then filtered using Whatman No 1 filter paper. The extract was kept in an airtight bottle and refrigerated at 4°C until used. 50g of moringa powder was taken for phytochemical analysis. Twenty albino rats were used for this investigation and they were grouped into four with five rats per cage. *Moringa* plant was applied to the skin of the albino rats for 20 days and the skin and muscle biopsies were taken and processed and stained histologically. The tissues were stained with Haematoxylin and Eosin and photomicrography of the skin and different muscle tissue of the albino rat were taken. 500g was macerated in 200ml of the crude extract to constitute a paste. Hundred persons with *Pseudofolliculitis barbae* (after shave rash) who consented to participate were recruited for this investigation after obtaining ethical clearance. The *Moringa* paste was used on consented persons with after shave rash leaving around Uselu metropolis in Egor local government Area of Edo state. The extract was used on after shave rash on their skin for the period of 2-3 days and observations were recorded. Photographs of the consented persons with after shave rash before and after use of the *moringa* paste were taken.

## RESULTS

The phytochemical analysis of *Moringa oleifera* lam reveals the following: Niazimicin, Benzyl, isothiocyanate, Pterygosperm, Benzyl

glucosinolate, vitamin A,  $\beta$ carotene, sucrose, D-glucose, flavonoid pigments such as alkaloids, kaempferol, rhamnetin, isoquercitrin, kaempferitrin, wax; calcium and potassium both of which are essential nutrients in the body. The photomicrograph from the skin biopsies taken from the albino rats reveals that there were no histological changes to the tissues when compared with the control slide. The slide reveals no histological changes to the epithelia lining, inflammation or any form of histological changes or cellular infiltration to the skin of the rats. The photomicrograph of skeletal, smooth and cardiac muscle tissues reveals that there was no cellular infiltration, toxic effect or histological changes to the various muscular tissues when compared with the photomicrograph from the control slides. Microscopically, both the aqueous extract and boiled decoction did not cause any histological changes to both skin and muscular tissues as revealed by the photomicrograph. The formed paste was able to effect total removal of the rash when used on the consented individual within day 2 and day 3 of usage.

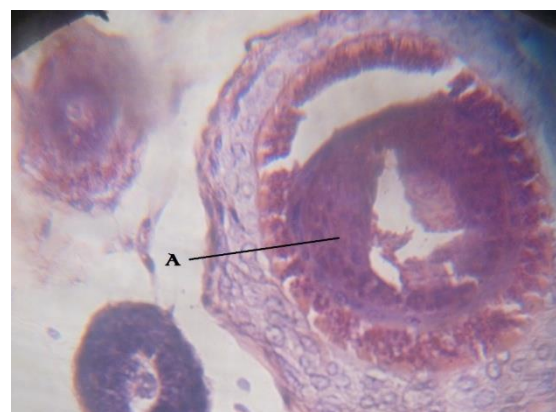


Figure 1: showing Hair follicle (A) of skin tissue before use of crude extract of *Moringa* plant stain with H&E X400

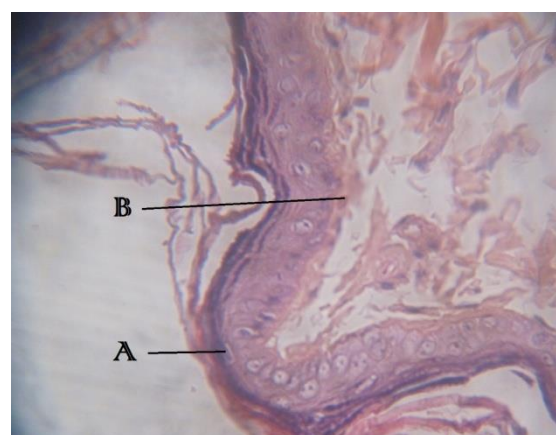


Figure 2: showing Dermis and Epidermis (A and B) respectively of skin tissue before use of crude extract of *moringa* plant stain with H&E X400

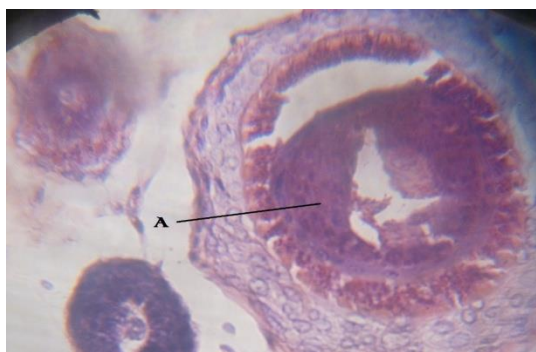


Figure 3: showing Hair follicle (A) of skin tissue after use of crude extract of moringa Plant stain with H&E X400

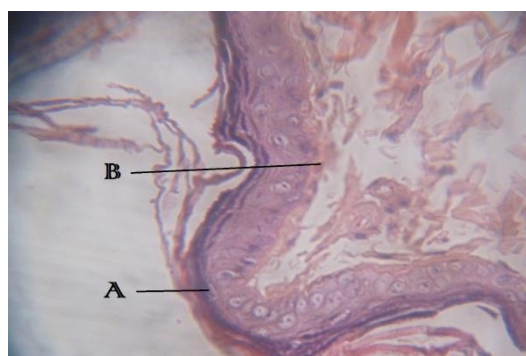


Figure 4: showing Dermis and Epidermis (A and B) respectively of skin tissue. After use of crude extract of moringa plant stain with H&E X400

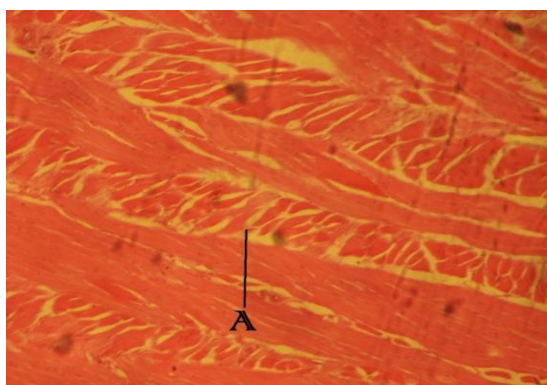


Figure 5: showing intercalated disc of normal muscle tissue after the use of Moringa plant extract stain with H&E X400

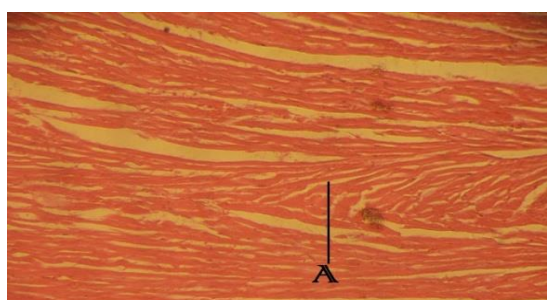


Figure 6: showing striation (A) of normal muscle tissue after the use of Moringa plant extract stain with H&E X400

## RECOMMENDATION

*Moringa* preparations have been cited in the scientific literature as having antibiotic, antitrypanosomal, hypotensive, antispasmodic, antiulcer, anti-inflammatory, hypocholesterolemic, and hypoglycemic activities, as well as having considerable efficacy in water purification. The scientific literature with respect to *moringa* continues to grow rapidly, particularly in the area of medicine, human and animal nutrition. Spraying the leaves of plants with the *Moringa* extract prepared in 80 % ethanol and then diluted with water produced some notable effects such as a longer, more vigorous life-span, heavier roots stems and leaves, bigger fruits and higher sugar levels etc. The extract produces an overall increase in yield of between 20-35 % based on data such as the stem diameter, number of nodules, number of axels, number of flower buds, and number of fruits per flower bud. *Moringa* plants extract dissolve readily in the solvents used in this work. The solubility in water was much higher than in alcohol. The alcohol extract of *moringa* plant extract worked faster than the boiled decoction. The plant extract was also used on after shave rash and it removed the rash within one to three days of usage. The skin of an albino rats stained with Haematoxylin and eosin before and after usage of *Moringa* plant extract show no traces of histological changes or infiltration or inflammation of any sort. The *moringa oleifera* lam extract worked well on *pseudofolliculitis barbae*, changes were noticed within the day two and three of usage. The use of the extract was on the skin and muscle tissues was actually carried out to ascertain its safety on the skin and muscle tissues.

## CONCLUSION

In conclusion, *Moringa oleifera* extract has the ability of removing after shave rash (*Pseudofolliculitis barbae*). The photomicrograph taken from various slides reveals that the tissue appears normal.

## REFERENCES

1. Anwar F. Latif, Ashaf M, Gilani A. *Moringa Oleifera*: a food plant with multiple medicinal uses. *Phytother. Res.* 2007; 21:17-25
2. Foidl N, Makkar HPS, Becker K. The potential of *Moringa Oleifera* for agricultural and industrial uses. What development potential for *Moringa* products? *Dar Es Salaam.* 2001.
3. Odee. Forest biotechnology research in drylands of Kenya: the development of *moringa* species. *Dryland Biodiversity.* 1998; 2:7-8
4. Palada, M.C., Chang, L.C., Yang, R. Y, Engle L.M. Introduction and Varietal screening of drumstick tree

(Moringa spp.) for horticultural traits and adaptation in Taiwan. Acta Hort. 2007; 752:249-253

5. Proyecto Biomasa. Internal Report , UNI Managa. 1996.

**How to cite this article:** Omorodion NT, Achukwu PU, Ibeh IN. Effect of Crude Extract of *Moringa Oleifera* Lam on Skin and Muscle Tissues of Abino Rats and on *Pseudofolliculitis Barbae* in Human. Ann. Int. Med. Den. Res. 2016; 2(6):AT15-AT18.

**Source of Support:** Nil, **Conflict of Interest:** None declared