

# A Case of Ectopic Liver Attached to the Gallbladder Wall.

Leena A B

Assistant professor, Department of Anatomy, Govt medical college, GH campus, Trivandrum.

## ABSTRACT

The liver lies mainly in the right upper quadrant of the abdomen where it is protected by the thoracic cage and diaphragm. Externally, the liver is divided into two anatomical lobes and two accessory lobes. During autopsy of a 25-year old male, an ectopic liver tissue was found attached to the serosa of gallbladder. Morphological variations of liver are irregularities in form, occurrence of one or more accessory lobe. The exact reason for the origin of ectopic liver in man is still unknown. It may also simulate tumor.

**Keywords:** Ectopic liver, Developmental anomaly, Gallbladder.

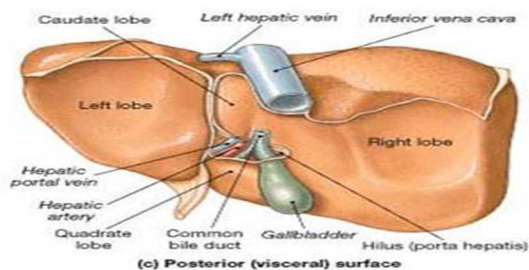
## INTRODUCTION

The liver is the most massive of the viscera, occupying a substantial portion of the abdominal cavity, that is, right hypochondrium and epigastrium, and extending into the left hypochondrium as far as left lateral line. It is a wedge shaped organ with its narrow end pointing towards the left. Even though the surface is smoothly continuous, the liver is customarily apportioned by anatomists into a larger right and a much smaller left lobe by the line of attachment of the falciform ligament anteriorly and the fissure for ligamentum teres and ligamentum venosum on the inferior surface. In addition to the right and left lobes, there are two additional lobes, a quadrate lobe in the front and the caudate lobe behind, separated from each other by the porta hepatis.

### Name & Address of Corresponding Author

Dr. Leena A B,  
Assistant professor, Dept of Anatomy,  
Govt medical college GH campus, Trivandrum, India  
E-mail: ableena@gmail.com

Quadrate lobe visible on the inferior surface appears somewhat rectangular and is bounded in front by the inferior border, on the left by fissure for ligamentum teres, behind by porta hepatis, and on the right by the fossa for the gall bladder [Figure 1].



**Figure 1:** shows normal anatomy of liver

The caudate lobe is visible on the posterior surface, bounded on the left by fissure for ligamentum

venosum, below by porta hepatis, and on the right by the groove for inferior vena cava.

Gross abnormalities of liver are rare despite its complex development. The most common gross abnormalities are irregularities in form, number of lobules, and in the presence of cysts. A less common abnormality is occurrence of one or more accessory lobes.

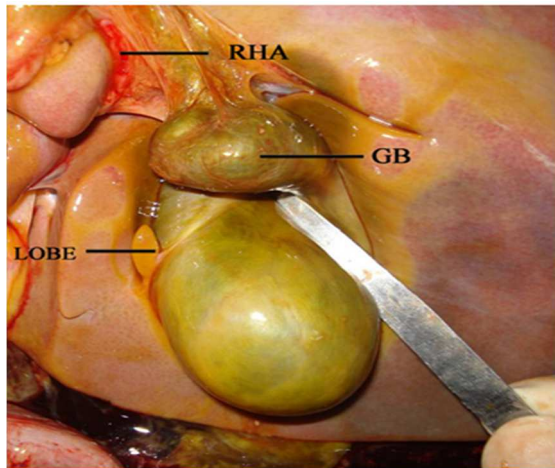
Ectopic liver is a rare developmental anomaly in which liver tissue is situated outside the liver and has no hepatic connection.<sup>[1]</sup> Ectopic liver tissue can occur in several different organs such as the diaphragm, hepatic ligaments, omentum, stomach, retroperitoneum and thorax<sup>[2,3]</sup>, but the gallbladder is the commonest site of origin. The incidence of ectopic liver (EL) has been reported to be anywhere from 0.24% to 0.47% as diagnosed at laparotomy or laparoscopy.

## CASE REPORT

During autopsy of a 25 year old male who died of hanging, a smooth tongue of brown tissue measuring 15 mm×5 mm×2 mm was seen to be attached to the serosa of the gallbladder by a thin mesentery. It was an ectopic liver tissue in inferior surface of liver close to gallbladder. Duct drained into gallbladder. [Figure 2]

Diaphragm, hepatic ligaments, omentum, stomach, retroperitoneum and thorax were examined for any ectopic liver tissue. But ectopic liver tissue was not seen in these sites.

Each lobe of the liver was studied in detail for the accessory fissures, and accessory lobes, which were absent in this case.



**Figure 2:** Shows ectopic liver present attached to serosa of body of gallbladder on inferior surface of liver

## DISCUSSION

Aberrant, supernumary or ectopic lobes are pedunculated projections usually from the ventral surface of liver near gall bladder that contain hepatic tissue with normal structure but variable function.

According to Collan<sup>[3]</sup> the liver tissue in communication with the main liver is termed as an accessory lobe while the liver tissue in the vicinity of the liver with no communication is termed ectopic liver.

### Classification of lobes based on drainage of bile and on presence of common capsule

Type 1-Separate accessory lobe whose duct drain into an intrahepatic bile duct of normal liver.

Type 2-separate accessory lobe whose duct drains into an extrahepatic duct of normal liver.

Type 3-accessory lobe that is incorporated in a common capsule with normal liver and bile drains into an extra hepatic duct.<sup>[4]</sup>

Ectopic liver is sometimes associated with other congenital anomalies such as biliary atresia, agenesis of the caudate lobe, omphalocele, bile duct cyst or cardiac and conotruncal anomalies. Although the ectopic tissue is usually attached to the serosa of the gallbladder or lies within its wall, it can also occur in the gall bladder lumen. As in the present case, it may have its own mesentery. Depending on its location, ectopic liver tissue can drain into the biliary tract<sup>[5]</sup>, into another organ or have no drainage system.

The incidence of ectopic liver tissue attached to the gallbladder has been reported as low, but is likely to increase with the new diagnostic methods. Eiserth<sup>[6]</sup> found only 3 cases in 5500 autopsies (0.05%), but in the laparoscopic era Watanabe and colleagues<sup>[7]</sup> have reported 3 cases in 1060 laparoscopies (0.28%).

Ectopic liver tissue has been found in the abdominal cavity, in the thorax, in omphaloceles or in the gallbladder. In several cases, pathologic changes were observed in ectopic liver tissue. In a 1989 review, Foghetal<sup>[8]</sup> found fewer than 40 reported cases of accessory liver lobes found incidentally at autopsy and 11 cases diagnosed in living patients.

Accessory, pedunculated lobes seem to be found almost exclusively in adult women and are usually associated with absence or hypoplasia of left lobe of liver. Abnormal lobation of liver has been observed occasionally in patients with trisomy 13 and trisomy 18. Sato et al<sup>[9]</sup> in a series of 1800 laproscopies found congenital anomalies of the liver in 19% cases with the incidence of ectopic liver lobe and accessory liver lobe being 0.7%. Embryologically the lungs and liver are derived from endodermal diverticuli of the foregut and are in close proximity. Accessory lobes are most commonly found on the undersurface of the liver, but have also been seen on the gall bladder surface, hepato-gastric ligament, near the umbilicus, adrenal gland, pancreas and the thoracic cavity. Accessory intrathoracic liver lobe was first reported by Hansborough and Lipin<sup>[5]</sup> in 1975. An intrathoracic accessory lobe is even rarer and when detected incidentally presents a diagnostic dilemma.

Ectopic location of liver tissue that is unattached to main organ may represent an accessory lobe that appears detached as a result of atrophy of original pedicle.

## CONCLUSION

Of all the digestive organs, the liver is the one, which starts its organogenesis early during 3rd week of intrauterine life and develops most rapidly.<sup>[5]</sup> Several theories have been proposed to explain the development of ectopic liver at different sites: development of an accessory lobe of the liver with atrophy or regression of the original connection to the main liver, migration or displacement of a portion of the cranial part (pars hepatica) of the liver bud to other sites, dorsal budding of hepatic tissue before the closing of the pleuroperitoneal canals<sup>[10]</sup>, trapping of hepatocyte-destined mesenchyma in different areas and entrapment of nests of cells in the region of the far-right following closure of the diaphragm or umbilical ring.

Gross abnormalities of the liver are rare in spite of its complex development. The most common gross abnormalities are irregularities in form and less common abnormality is the occurrence of one or more accessory livers or lobes<sup>[3]</sup>. In the era of imaging and minimally-invasive approaches, it is imperative on the part of both the radiologists and operating surgeons to have a thorough knowledge

of the anatomy and the commonly-occurring variations of this organ.

Because patients with ectopic liver may suffer complications such as torsion, peritoneal bleeding, fatty change, and evolution to cirrhosis or malignant degeneration to hepato-cellular carcinoma, any ectopic liver tissue needs to be correctly identified and removed.

Preoperative diagnosis of this anomaly is difficult because of lack of symptoms and difficulties in imaging. It is usually an incidental finding during a laparoscopy, laparotomy or autopsy performed for unrelated reasons. The diagnosis should be considered when a soft-tissue mass is seen to arise from the gallbladder wall on abdominal ultrasound or CT scan<sup>[10]</sup>. The combination of intravenous injection of indocyanine green with laparoscopy<sup>[3]</sup> may increase the diagnostic accuracy of this type of developmental anomaly.

There are too few case reports for definitive treatment to be clear-cut. It would be sensible to resect the ectopic tissue if encountered during cholecystectomy for gallstones, but to leave it alone if seen incidentally during other procedures. Further study of ectopic liver is recommended.

## REFERENCES

1. Champetier J, Yver R, Letoublon C. A general review of anomalies of hepatic morphology and their clinical implications. *Anat Clin.* 1985;7:285-299.
2. Cullen TS. Accessory lobes of the liver: an accessory hepatic lobe springing from the surface of the gall bladder. *Arch Surg.* 1925; 11: 718-764.
3. Collan Y, Hakkiluoto A, Hastbacka J. Ectopic Liver. *Ann Chir. Gynaecol* 1978; 67: 27-29.
4. Elmasalme F, Aljudaibi A, Matbouly S, Hejazi N, Zuberi MS. Torsion of an Accessory Lobe of the Liver in an Infant. *J Pediatr Surg.* 1995;30:1348-50.
5. Hansborough ET, Lipin RJ. Intrathoracic accessory lobe of the liver. *Ann Surg.* 1975;145: 564-567.
6. Eiserth P. Beitrage zur Kenntnis der nebenlebern. *Virchows Arch Pathol Anat.* 1940;207:307-13.
7. Watanabe M, Matsura T, Takatori Y, et al. Five cases of ectopic liver and a case of accessory lobe of the liver. *Endoscopy.* 1989;21:39-42.
8. Fogh J, Tromholt N, Jorgensen F. Persistent impairment of liver function caused by a pedunculated accessory liver lobe. *Eur J Nucl Med.* 1989;15:326.
9. Sato S, Watanabe M, Nagasawa S, Niigaki M, Sakai S, Akagi S. Laproscopic observations of congenital anomalies of the liver. *Gastro intest Endosc.* 1998;47:136-140.
10. Riedel BMKL. Uber den zungenformigen Fortsatz des rechten Leberlappens und seine pathognostische Bedeutung fur die Erkrankung der Gallenblasen bei Bemerkungen uber Gallensteinoperationen. *Berlin Klin Wschr.* 1888; 25:577.

**How to cite this article:** Leena AB. A Case of Ectopic Liver Attached to the Gallbladder Wall. *Ann. Int. Med. Den. Res.* 2016;2(2):23-5.

**Source of Support:** Nil, **Conflict of Interest:** None declared