

# A Study Of Clinical Outcome Of Double Folded Rectosigmoid Bladder With Extramural Subserous Tunneled Ureterocolonic Anastomosis (Abol-Enein and Ghoneim) for Urinary Diversion.

N. Anil Kumar<sup>1</sup>, C. Subba Rao<sup>2</sup>, S.R. Sree Gouri<sup>3</sup>

<sup>1</sup>Associate Professor, Department of Urology, Sri Venkateswara Institute of Medical Sciences, Tirupati, Andhra Pradesh, India.

<sup>2</sup>Professor and HOD, Department of Urology, Andhra Medical College, Vishakapatnam, Andhra Pradesh, India.

<sup>3</sup>Assistant Professor, Department of Obstetrics and Gynaecology, SPMC(W)-Sri Venkateswara Institute of Medical Sciences, Tirupati, Andhra Pradesh, India.

## ABSTRACT

**Background:** To study and analyze the clinical outcome of double folded rectosigmoid bladder with extramural subserous tunnels done in various cases for urinary diversion after cystectomy. **Method:** Analysis and follow up of 18 cases of double - folded rectosigmoid urinary diversions done in various patients following cystectomy for various indications in Department of urology, King George Hospital, Vishakapatnam during the period between 2008 - 2009. **Results:** There was no deaths or deterioration of the upper tracts recorded in the study group. In early post-operative period wound infection developed in 4 cases, prolonged ileus was seen in 3 cases, Electrolyte imbalance was seen in 4 cases. Late complications noted, were pyelonephritis in 3 cases, acidosis in 2 cases and hypokalemia in 3 cases. All the early and late postoperative complications were successfully treated conservatively. **Conclusion:** Our study has shown that the double folded rectosigmoid bladder reconstruction is an easier procedure with an easier technique of re-implantation suited even for dilated ureters with a short operating time and has shown better continence rate with post-operative complications less in number and severity.

**Keywords:** Double folded, Rectosigmoid bladder, Urinary diversion.

## INTRODUCTION

Intestinal segments have been used to improve or replace lower urinary tract function for more than a century.<sup>[1]</sup> Common indications of the urinary diversion are carcinoma bladder undergoing radical cystectomy, cystectomy done for exstrophy bladder. Other indications are neurogenic bladder, severe urinary incontinence, severe urethral trauma, large vesical fistula, cyclophosphamide cystitis, radiation cystitis. Uretrosigmoidostomy is the oldest technique of continent urinary diversion since 19th century<sup>[2]</sup>. Uretrosigmoidostomy remains popular with urological surgeons fueled by its simplicity of creation.<sup>[3-6]</sup> Double folded rectosigmoid bladder is a modified Uretrosigmoidostomy of main z II type in which ureteral reimplantation into an S-shaped sigmoid reservoir is done in an extramural & subserosal fashion for anti reflux (Abol-Enein and Ghoneim, Egypt, 1993).<sup>[7-9]</sup> The earliest attempt to divert urine was done in 1851 by John Simon.<sup>[10]</sup>

### Name & Address of Corresponding Author

Dr. N. Anil Kumar  
Associate Professor,  
Department of Urology,  
Sri Venkateswara Institute of Medical Sciences,  
Tirupati, Andhra Pradesh, India,  
E mail: drak\_94@yahoo.co.in

In the absence of antibiotics Uretrosigmoidostomy and its modifications during 19th & early 20th centuries have been associated with high rate of surgical & metabolic complications. In late 1980's

orthotropic bladder diversions were described.<sup>[11]</sup> In 1988 augmented valved rectum was described by Kock and associates. In 1989 Skinner and colleagues described Hemikock procedure with valved rectum.<sup>[12]</sup> In 1993 folded rectosigmoid bladder with serous lined extramural tunnels was described by Abol-Enein and Ghoneim from Egypt. Up to date, various continent cutaneous reservoirs rectosigmoid pouches and orthotropic bladder substitutes and possible complications have been described.<sup>[13-15]</sup> Regarding encouraging improvements in biocompatible materials, alloplastic bladder replacement could be the next step for the future in bladder replacement surgery.

To study and analyze the clinical outcome of double folded rectosigmoid bladder with extramural subserous tunnels done in various cases for urinary diversion after cystectomy.

## MATERIALS AND METHODS

Double - folded rectosigmoid urinary diversions done in eighteen patients following cystectomy for various indications in Department of urology, King George Hospital, Visakhapatnam during the period between 2008 - 2009. Age group of the patients ranged from 12 to 70 years. Sex distribution in the patients in the study was male:female = 14:4 (3.5:1).

Indications for which the cystectomy was performed were [Table 1]:

- Carcinoma bladder
- Exstrophy bladder

- Exstrophy with malignancy

**Table 1:** Causes of cystectomy

Causes of cystectomy	No of patients
Carcinoma of bladder	14
Exstrophy bladder	03
Exstrophy with malignancy	01

Study group included 3 cases of exstrophy bladder, 1 case of exstrophy with malignancy and 14 cases of carcinoma bladder.

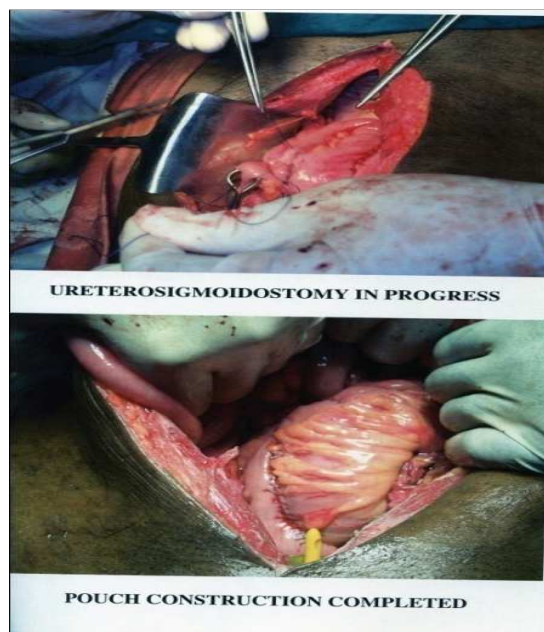
Exclusion criteria followed are:

- Serum creatinine more than 1.5 mg%
- Incompetent anal sphincter
- Irradiation of pelvis
- Diverticulosis of sigmoid colon
- Colonic polyposis

**Operative Technique** [Figure 1]

Anaesthesia used - spina or epidural or general depending on case. After anesthesia Nasogastric tube and rectal tube were placed. Lower and midline laparotomy incision is given. Peritoneum incised lateral to ascending and descending colon, right and left ureters mobilized transacted as distal as possible and strong sutures placed at 6'O clock position. Stumps are ligated. Simple or radical cystectomy is performed in regular manner. An 'S' shaped sigmoid segment outlined with 10 -12 cm each limb length (total 30-36 cm). The Antimesenteric area along anterior taenia opened, side-to-side adaptation of the limbs done by single layer of non-absorbable running suture. Thus, two serosa-lined tunnels are created. An entrance for the right ureter is left at cranial aspect of running suture. Left ureter is brought through the small opening created in the mesentery created at the cranial end of the left running suture. Ureters

placed un-respective channels and bowel edges sutured over ureters, incorporating all layers converting the channels into tunnels. The length of the tunnel fashioned four times the diameter of the ureter. The ureters are spatulated. Four anchor sutures are placed at 11'o clock, 1'o clock, 5'o clock, 7'o clock positions through all layers of bowel wall with 4.0 PGA. Uretero mucosal sutures anastomosis with 5.0 PGA. Stents are placed in both ureters and pulled out through rectal tube after fixing it to the bowel mucosa with 4.0 PGA. The anterior pouch wall is closed by seromucosal sutures.



**Figure 1:** Procedure for Urinary Diversion.

**RESULTS**

**Table 2:** Post-operative complications

Early complications	No of cases	Percentage
Wound infection	4	22%
Prolonged ileus	3	16%
Electrolyte imbalance	4	22%
Wound dehiscence	1	5.5%
Late complications	No of cases	Percentage
Pyelonephritis	3	16%
Acidosis	2	11%
Hypokalemia	3	16%

Double folded rectosigmoid bladder reconstruction with extramural sub-serous tunneled ureterocolonic anastomosis was done in 18 patients during 2008 - 2009. The age of the patients ranged from 12 to 70 years. The operative time ranged from 1.5 to 2 hours (mean time 105 min). Follow up of the patients ranged from 2 months to 26 months. There were no deaths or deterioration of upper tracts recorded in the study group.

In early post-operative period wound infection developed in 4 cases, prolonged ileus was seen in 3 cases, electrolyte imbalance (hypokalemia, acidosis) was seen in 4 cases. Late complications noted were pyelonephritis in 3 cases (4 renal units), acidosis in 2 cases and hypokalemia in 3 cases [Table 2]. All the early and late post-operative complications were successfully treated conservatively with hospital admission, antibiotics, intravenous fluids and

electrolyte imbalance. No surgical intervention was needed for the complications. Two patients complained mild night time faecaluria. But all the patients were continent during day for 3 - 4 hours. We advocate long-term antibiotic prophylaxis and oral alkylating agents with calcium supplementation and nightly rectal tube insertion in all the patients.

### DISCUSSION

Double folded rectosigmoid bladder with extramural subserous tunnels done in properly selected cases undergoing cystectomy for various indications like exstrophy bladder, exstrophy with malignancy and carcinoma bladder excluding those with raised renal parameters, colonic diverticulosis and previously irradiated pelvis show favorable clinical outcomes as shown in the present study. Proper pre-operative evaluation with adequate bowel preparation and close post-operative monitoring help improving clinical outcomes. In the present study early complications ranged from 5.5% to 22% and late complications ranged from 11% to 16%. All the complications were mild and could be managed easily.

**Table 3:** Causes of cystectomy

Complications	El-Mekresh group (1993)	Present study (2009)
Deaths	7	0
Incontinence (day)	0	0
Incontinence (night)	4	2
Pyelonephritis	6	3
Metabolic acidosis	0	4

A similar study was done by El-Mekresh group in 1993<sup>[7]</sup> on 64 cases, who were followed for 6 to 36 months. They have reported 7 deaths out of which 1 was due to massive pulmonary embolism and 6 were due to the disease itself. All the patients were continent except for 4 cases who had mild night faecaluria. Four cases (6 renal units) developed pyelonephritis. The present study done at our Institute with 18 cases who were followed for 2 to 26 months showed night time incontinence, pyelonephritis and metabolic acidosis in 2, 3 and 4 cases respectively.

### CONCLUSION

Our study has shown that the double folded rectosigmoid bladder reconstruction is an easier procedure with an easier technique of re-implantation suited even for dilated ureters with a short operative time and has shown better continence rate with post-operative complication less in number and severity (short term follow-up).

Further improvement in case selection, improvement in learning curve, patient evaluation and post-operative care will help in getting better results. Double folded rectosigmoid bladder reconstruction with extramural subserous-tunneled ureterocolonic anastomosis is a safe and reproducible urinary diversion and serves as an alternative to other forms of urinary diversion in all the age groups. The long-term results remain to be evaluated.

### REFERENCES

1. W Scott, McDougal. Use of intestinal segments and urinary diversion: Campbell's Urology - Eighth edition; 106:p.3745-3788.
2. Douglas M MD, W Scott McDougal MD. Use of intestinal segments in urinary diversion: Campbells Urology- Ninth edition; 80:p.2534-2578.
3. Magit Fisch, GD Elia, Rudolf Hohenfeller, Joachem W Thuroff. Ureterosigmoidostomy: Glenn's Urological Surgery - sixth edition; p 689-697.
4. Ambrose SS. Ureterosigmoidostomy. In Glenn. (ed): urological surgery. Philadelphia. JB Lippincott; 1983. p 511-520.
5. Bissada NK, Morkos RR, Morgan WM. Ureterosigmoidostomy: is it a viable procedure in the age of continent urinary diversion and bladder substitution? Just urol. 1995;153:1429-1431.
6. Spirnak JP, Caldamone AA. Ureterosigmoidostomy, Urol clin. North America. 1986;13:285-294.
7. El-Mekresh MM, Hafez AT, Abol Enein H, Ghoneim MA. Double folded rectosigmoid bladder with a new ureterocolic anti reflux technique. J urol. 1997;157:2085-2089.
8. Woodhouse CRJ, Christofides M. Modified ureterosigmoidostomy (Mainz II): Technique and early results. Br J Urol. 1998;81:247-252.s.
9. Venn SN, Mundy AR. Continent urinary diversion using the Mainz-type ureterosigmoidostomy - A valuable salvage procedure. Europe Urol. 1999; 36:247-251.
10. Simon J. Ectopic vesicae (absence of the anterior walls of bladder and pubic abnormal parietes); Operation for directing the orifices of the ureters into rectum; temporary success; subsequent death; autopsy. Lancet. 1852;2:568-571.
11. John P Stein MD, Donald G, Skinner MD. Orthotropic Urinary Diversion: Campbell's Urology- Eighth edition; 108: p 3835-3867.
12. John P Stein MD, Donald G, Skinner MD. Orthotropic Urinary Diversion: Campbell's Urology -Ninth edition; 82: p 2613-2648.
13. Mitchell C Benson MD, James M Mc, Kiernan MD, Carl A Ollson MD. Cutaneous Continent Diversion: Campbell's Urology-Ninth edition; 81, p2579-2612.
14. Duckett JW, Garak JM. Complications of ureterosigmoidostomy. Urol clinical North America. 1983; 10:473-481.
15. Kable.T. Tricker AR, Friedl P, Waldherr R et al. Ureterosigmoidostomy: Long-term results, risk of carcinoma & etiological factors for carcinogenesis. J Urol. 1990; 144:1110-1114.

**How to cite this article:** Kumar NA, Rao CS, Gouri SRS. A Study Of Clinical Outcome Of Double Folded Rectosigmoid Bladder With Extramural Subserous Tunneled Ureterocolonic Anastomosis (Abol-Enein and Ghoneim) for Urinary Diversion. Ann. Int. Med. Den. Res. 2016;2(1):319-21.

**Source of Support:** Nil, **Conflict of Interest:** None declared.