

# Gillie's Temporal Approach in the Management of Zygomatic Arch Fracture under Local Anaesthesia- A Case Report.

Abhishek Handa<sup>1</sup>, Sharma Shrikant Surendra<sup>2</sup>, Sandeep Singh Rana<sup>3</sup>, Rajkumar Mantri<sup>4</sup>, Manish Sharma<sup>5</sup>, Rushi Virani<sup>6</sup>

<sup>1</sup>Reader, Department of Oral and Maxillofacial Surgery, Darshan Dental College and Hospital, Udaipur.

<sup>2</sup>Post Graduate, Department of Oral and Maxillofacial Surgery, Darshan Dental College and Hospital, Udaipur.

## ABSTRACT

The authors have studied and presented their experience in the management of ZMC fractures with Gillie's temporal approach and its extreme versatility. The study included a patient with Zygomatic arch fracture under local anesthesia. The study supports the use of Gillie's temporal approach in Zygomatic arch fracture due to its versatility in fracture reduction and aesthetic restoration of form and function.

**Keywords:** Zygomatico- maxillary, fractures, Rowe's zygomatic elevator, Gillie's, incision.

## INTRODUCTION

Face being the most important part of aesthetic concern in the human body is prone to fractures due to road traffic accidents, physical assaults, sports injuries, industrial accidents and so on. The facial prominence is given by the sturdy malar bones. Approaches to Zygomatic arches still remains to be debatable. Zygomatico-maxillary complex fractures are the most commonly encountered facial injuries next to nasal bone fractures.<sup>[1]</sup> Zygomatic fractures have been traced down in history since 1650 B.C. to restore the facial contours and its anatomic form, function, these fractures have to be diagnosed precisely with the help of proper clinical examination and advanced imaging techniques.<sup>[2]</sup>

Zygomatic fracture management was revolutionized with the advent of internal fixation with wires in 1942. In 1978, Champy's et al proposed the adaptation osteosynthesis with plate and screw fixation. In the early part of the twentieth century, different approaches to the zygomatic bone were established and reduction of the fracture without fixation was described.<sup>[3]</sup>

Gillie's temporal approach was first reported in 1927 by Gillie's, Kilner Land stone was frequently used because of the short duration of general anaesthesia and minimal morbidity. The advantages of this closed approach are short duration of anaesthesia, decreased possibility of facial nerve damage, decreased indirect trauma to the globe, absence of visible scar.<sup>[4]</sup>

### Name & Address of Corresponding Author

Dr. Shrikant S. Sharma  
Room No-313, P.G Dental Hostel,  
Department of Oral And Maxillofacial Surgery  
Darshan Dental College and Hospital, Loyara, Udaipur,  
Rajasthan (India).  
E mail: drshrikant013@gmail.com

## CASE REPORT

A 35-year-old male patient reported to the department of Oral and Maxillofacial surgery with the chief complaint of pain and reduced mouth opening for 2 days. The history revealed that he had met with a road traffic accident 2 days back. He was unconscious for half an hour when he was admitted in the general hospital immediately. He was referred to the department when he regained consciousness fully and was well oriented after clearance from the neurosurgical point of view [Figure 1].

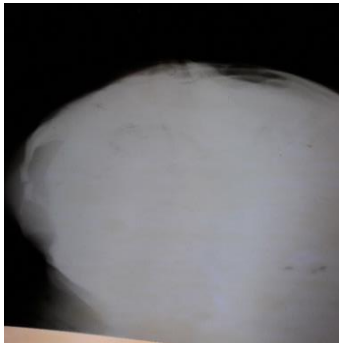
On local examination, there was depression on the right side in the zygomatic region and reduced mouth opening of 20 cm. On palpation, confirmation of the depression and tenderness on the zygomatic arch area was appreciated. Submentovertex radiograph and computed tomography were advised. Fracture of the zygomatic arch was confirmed [Figure 2 and 3]. Arch elevation was decided as the treatment modality. After all the preliminary blood investigation and anesthetic evaluation, the case was posted under local anesthesia.

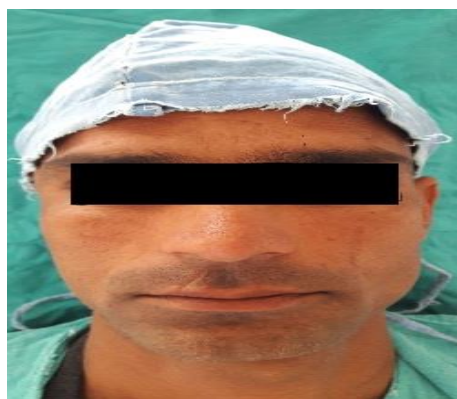
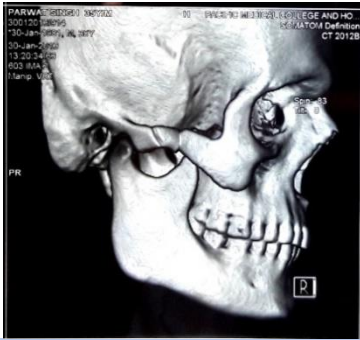
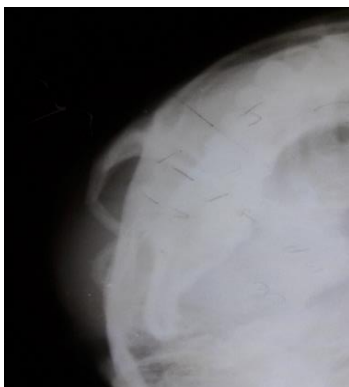
Figure 1: Frontal view.



**Figure 2:** 3D CT Scan.

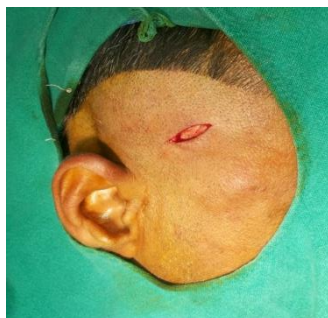

**Figure 3:** Submentovertex view radiograph.



**Figure 4:** Submentovertex View radiograph.

Under aseptic conditions, the superficial temporal artery was identified and marked. A modified temporal incision below the anterior branch of superficial temporal artery and 2 cm above the zygomatic arch was made.



**Figure 5:** Modified temporal Incision Placed.

Through the blunt dissection, the temporal fascia (has an appearance of shiny white glistening fascia)

and the temporalis muscle was identified [Figure 5]. The branches of the facial nerve run within the temporal fascia. In order to protect the nerves, the flap was elevated with the fascia inferiorly and the zygomatic arch was approached and the fragments elevated. With the help of the Rowe zygomatic elevator, reduction of the arch was done. With the help of periosteal elevator, accurate reduction of the fragments was carried out so as to restore the smooth curvature of the arch [Figure 4]. Three layered closure was done and the patient was advised not to sleep on that side for 7 days. The postoperative period was uneventful. He was prescribed with antibiotics, and analgesics postoperatively. Function as well as aesthetics was restored with satisfaction.

## DISCUSSION

Zygomatic arch is formed by the temporal process of zygoma and the zygomatic process of temporal bone. The masseter muscle consisting of three superimposed layers which blend anteriorly gains attachment from zygoma and the zygomatic arch. The superficial layer arises from the maxillary process of the zygomatic bone and from the anterior two-third of the lower border of the zygomatic arch. The middle layer arises from the deep surface of the anterior two-third of the zygomatic arch.<sup>[3,5]</sup> The deep layer arises from the deep surface of the arch. Contraction of this muscle is often implicated as the primary cause of post reduction displacement of the zygoma.<sup>[6-8]</sup> Due to the attachment of the temporalis fascia along the superior aspect of the arch, internal fixation is unnecessary, even in mildly displaced fractures as the fascia will immobilize the fragments effectively. However, multiple and depressed fractures need stabilization. The temporal fascia covers the temporalis muscle whose fibers passes through the gap between the zygomatic arch and the side of the skull to get inserted into the coronoid process. About 2 cm above the zygomatic arch the fascia splits into two layers, one of which is attached to the upper border and the other to the lateral border.<sup>[2,9,10]</sup> This division of the fascia has taken advantage of when approaching the arch through the temporal incision in order to protect the branches of the facial nerve, which are superficial to it. While approaching the zygomatic arch, the branches of the facial nerve have to be protected. The temporal branches emerge from the upper part of the parotid gland, cross the zygomatic arch obliquely and pass to supply the frontal belly of the occipitofrontalis, the orbicularis oculi and the anterior and the superior auricular muscles. The small zygomatic branches run across the zygomatic arch to supply the orbicularis oculi and the larger branches run below the arch to supply the muscles of the nose and those between the eye and mouth.<sup>[5]</sup>

Isolated zygomatic arch fractures occur as a result of direct trauma to the temporal region. This results in noticeable depression at the fracture site. There may be impingement of the fractured arch with the coronoid process resulting in limited mouth opening as seen in the case reported. The treatment for isolated zygomatic arch fractures depends on the degree of displacement. Usually fractures with significant displacement need reduction. A simple reduction of the arch can be accomplished by either by a percutaneous hook, Gillies temporal approach, or through intraoral approach. The need for stabilizing zygomatic arch varies with the location of injury, number of fragments and displacement of segments. Ellis et al. found that ten out of 126 cases required fixation<sup>[6]</sup>. Various materials like a metal eye shield, plastic oral airways, short pieces of endotracheal tubing and orthopedic finger splints have been used as the external device for fixation. The unstable fractured zygomatic arch can be stabilized by Kirschner wire. However, when there is a comminuted fracture of the arch, there is a need for open reduction and internal fixation.

Zygomatic arch can be approached directly either by bicoronal, pre-auricular, percutaneous or lateral eyebrow incision. The coronal incision is extremely useful for surgery of zygomatic complex including the arch. It appears as a radical approach to the zygomatic complex and it provides an excellent access to all the associated structures with virtually no complications.<sup>[7]</sup> This is useful when there is comminution of supra-orbital and lateral orbital rims and zygomatic body and arch. The scar produced is hidden within the hair and is therefore invisible. Zhang et al. while describing coronal incision for the open reduction and internal fixation for the zygomatic complex mentioned various complications associated with it. Hemorrhage, hematoma infection, swelling and temporary nerve injury are the early complications while alopecia, obvious scarring, permanent paralysis of the facial nerve and depression of temporal fascia are the long-term complications. Although coronal incision will facilitate accurate reduction and fixation of fragments, indication for the coronal incision should be strictly controlled and this incision should not be overuse.<sup>[2]</sup>

Mizuno et al. reported 16 cases where pre-auricular incision was used to expose the malar arch. The advantages include the ability to attain excellent stability of the broken arch, mobilization of the fracture fragments precisely and avoidance of excessive stretching of the nerve fibers. However, the operative time and the possibility of injury to the nerve are of greater concern in this approach. Thangavelu et al. suggested the use of frontotemporal approach to the management of zygomatic complex fractures. A frontotemporal incision was placed up to the depth of temporalis fascia. Dissection towards the arch and orbital rim

should be in a plane deep to the superficial layer of the deep temporal fascia so that frontal and orbital branches of the facial nerve are elevated with the flap. The periosteum is then incised along the orbital rim along the arch fragments deep to the attachment of the superficial layer of the fascia. The fracture fragments are directly visualized reduced and stabilized using semi-rigid internal fixation. This approach gives excellent visualization and allows fixation at three points of articulation and the incision is concealed within the hair bearing area.<sup>[7]</sup> The disadvantages of this approach are prolonged operative time and possible damage to the branches of the facial nerve.

When there is an isolated comminuted fracture of the zygomatic arch and needs the open reduction and internal fixation, an alternative incision is suggested as mentioned in the above case. A modified curved incision is placed just approximately 2 cm above the zygomatic arch. This incision is safe as it is placed just posterior to the temporal branch of the facial nerve and below the anterior branch of the superficial temporal artery. The temporal branch of the facial nerve crosses the zygomatic arch more anteriorly. Through blunt dissection, the deep fascia is reached and the flap with the superficial fascia is elevated so that the branches of the facial nerve are preserved as it goes along the flap.<sup>[10-12]</sup> Dissection continues inferiorly until the periosteum of the zygomatic arch is encountered. The periosteum is incised and the fragments exposed. We did not come across any complications either early or late. Following the reduction of the zygomatic arch fracture, one must protect the side of the head from further injury. The force of the weight of the head resting on a pillow is sufficient to displace even a properly reduced fracture.

## **CONCLUSION**

Although the isolated fracture of the zygomatic arch is rare and even rarer is the need for the open reduction and internal fixation, this alternative approach to the arch is useful. The operative time is reduced and the complications are minimized through this approach. However, many more cases have to be carried out in order to establish the efficiency and the efficacy of this particular approach.

## **REFERENCES**

1. Banks P. Killey's Fracture of the middle third of the facial skeleton. Bombay: Varghese Publishing House; 1992.
2. Cammiller AC, Gilhooly M, Cooke ME. Stabilization of the unstable fractured zygomatic arch with a Kirschner wire. Br J Oral Maxillofac Surg. 2005; 43(2):183-184.
3. Drake LR, Vogl W, Mitchell AWM. Gray's anatomy for students. Philadelphia: Elsevier Churchill Livingstone; 2005.

4. Ellis E, 3rd, el-Attar A, Moos KF. An analysis of 2067 cases of zygomatico-orbital fractures. *J Oral Maxillofac Surg.* 1985;43(6):417–428.
5. Fonseca JR. *Oral and maxillofacial trauma.* Philadelphia: Elsevier; 2005. pp. 569–642.
6. Indirbir Singh, editor. *BD Chaurasia's human anatomy regional and applied.* New Delhi: CBS Publisher; 1996.
7. G R Odgen in., The Gillie's method for fractured zygomas – An analysis of 105 cases- *Journal of oral and maxillofacial surgery.* 1991; 23-25.
8. Markus Zing et al in. Classification and treatment of zygomatic fractures : A review of 1025 cases. *Journal of oral and maxillofacial surgery.* 1992; 50: 778-790.
9. S Taicher, L Ardekian, N Samet, N Shoshan and I Kaffe in., Recovery of the Infra orbital nerve after Zygomatic complex fractures: A preliminary study of different treatment methods. *International journal of oral and maxillofacial surgery.* 1993; 22: 339- 341.
10. P M Cloghlin, M. Gilhooly, G. Wood in The management of zygomatic complex fractures – Results of a survey. *British journal of oral and maxillofacial surgery.* 1994;32: 284-288.
11. Dae Hyun Lew et al., Simple fixation method for unstable zygomatic arch fracture using double kirschner's wires. *Plastic reconstruction surgery.* 1997; 101: 13 -51.
12. Adebayo. Analysis of the pattern of maxillofacial fractures in Kaduna. *Nigeria British journal of oral and maxillofacial surgery.* 2001; 41(6):396–400.

**How to cite this article:** Handa A, Surendra SS, Rana SS, Mantri R, Sharma M, Virani R. Gillie's Temporal Approach in the Management of Zygomatic Arch Fracture under Local Anaesthesia- A Case Report . *Ann. Int. Med. Den. Res.* 2016; 2(3):16-9.

**Source of Support:** Nil, **Conflict of Interest:** None declared