

Maxillary Canine Impactions: Orthodontic and Surgical Management.

Pradeep Vishnoi¹, Kakadiya Jignesh Keshubhai¹, Sharma Shrikant Surendra², Neha Bandi¹, Jyoti Jingar¹, Trivedi Rutvik¹

¹Post Graduate, Department of orthodontics and Dentofacial Orthopedics, Darshan Dental College and Hospital, Udaipur.

²Post Graduate, Department of Oral and Maxillofacial Surgery, Darshan Dental College and Hospital, Udaipur.

ABSTRACT

Canines are important teeth in terms of esthetic and function. The Maxillary Canines are also known as 'Corner stone of smiles' or 'Eye teeth'. Impaction of canines is a common occurrence and clinicians must have a sound knowledge to manage such cases. Dachi and Howell reported that the incidence of maxillary canine impaction is 0.92%, and mandibular canine impaction is 0.35% among which 8% patients bilateral impactions. No prosthesis can match the originality of contour, shape and color of original canine. So every attempt should be made to retrieve the impacted canine. With early detection, timely interception and well managed surgical and orthodontic treatment; impacted canines can be erupted and guided to an appropriate location in the dental arch. This paper presents a literature review regarding etiology, clinical and radiographic diagnosis, as well as surgical and orthodontic management of impacted canine along with case presentations.

Keywords: Impacted canines, surgical techniques, orthodontic techniques.

INTRODUCTION

According to Shafer, Hine and Levy, impacted teeth are those, which are prevented from erupting by some physical barrier in the eruption path.

An impacted or unerupted canine tooth is usually easy to diagnose, but skill and expertise along with a multidisciplinary approach are needed, to bring it, to its proper position.

An overview of the incidence and sequelae as well as the surgical, periodontal and orthodontic considerations in the management of impacted canines is presented here.

Name & Address of Corresponding Author

Dr. Pradeep Vishnoi
Department of Orthodontic And Dentofacial Orthopedics,
Darshan Dental College and Hospital, Loyara, Udaipur,
Rajasthan, India.
E.mail: dr.pradeepvishnoi@gmail.com

INCIDENCE OF CANINE IMPACTION

1. Cumulative prevalence of canine impaction in 7-13 yr old children: 2.2% (Thilander & Myrberg, 1943)
2. Incidence of maxillary, canine impaction: 0.92% (Dachi and Howell, 1961) & 1.7% (Ericson & Kurol, 1986).
3. Incidence of mandibular canine impaction 0.35% (Dachi and Howell).
4. Impactions twice as common in females (1.11%) than in males (0.51%)
5. A rate of twelve palatally impacted canines for one labially impacted canine (Jacoby).
6. Of all patients with maxillary impacted canines, 8% have bilateral impactions.^[5]

ETIOLOGY OF MAXILLARY CANINE IMPACTION (MULTIFACTORIAL)

Bishara and associates summarized Moyer's theory that impacted canine is caused by

- i. Primary (Localized)^[7]
 - a) Tooth size -arch length discrepancies.
 - b) Prolonged retention or early loss of deciduous canine.
 - c) Abnormal position of the tooth bud (rotation of tooth buds).
 - d) Trauma of the deciduous tooth bud.
 - e) Disturbances in the tooth eruption sequence.
 - f) Presence of an alveolar cleft.
 - g) Ankylosis.
 - h) Cystic or neoplastic formation
 - i) Dilaceration of the root
 - j) Premature root closure
 - k) Iatrogenic
- ii. Secondary (Generalised)
 - a) Abnormal muscle pressure
 - b) Febrile diseases
 - c) Endocrine disturbances
 - d) Vitamin D deficiency
 - e) Irradiation

SEQUELAE OF IMPACTION (SHAFFER et al.)

- a) Labial or lingual malpositioning of the impacted tooth
- b) Migration of the neighbouring teeth and loss of arch length.
- c) Internal resorption.
- d) Dentigerous cyst formation

- e) External root resorption of the impacted as well as neighbouring teeth
- f) Infection, particularly with partial eruption
- g) Referred pain
- h) Combinations of the above (or) no untoward effects.^[5]

DIAGNOSIS OF IMPACTION

The proper localization of the impacted tooth plays a crucial role in determining the feasibility of as well as the proper access for the surgical approach and the proper direction for the application of orthodontic force.

Clinical Evaluation:

The following signs might be indicative of canine impaction.

1. Delayed eruption of the permanent canine or prolonged retention of the deciduous canine beyond 14 to 15 years of age.
2. Absence of a normal labial canine bulge.
3. Presence of a palatal bulge.
4. Delayed eruption, distal tipping or migration (splaying) of the lateral incisor.

Radiographic Evaluation:

Various radiographic exposures like occlusal films, panoramic, lateral cephalograms help in evaluating the position of the canines.

Periapical films are sometimes uniquely reliable for the same purpose.

i) Periapical films:

There is only a two dimensional representation of the dentition in a single periapical film i.e. only mesiodistal and superoinferior relationships are seen [Figure 1]. For buccolingual relation of the canine position a second periapical film is obtained by one of the following methods:

- a. Tube shift technique or Clark's rule
- b. Buccal object rule

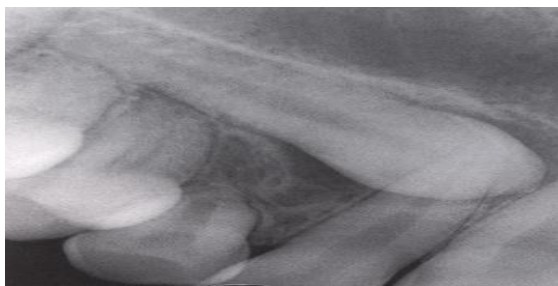

Figure 1: Periapical radiograph show position of impacted canine.

a) Tube Shift Technique

Two periapical films are taken of the same area with the horizontal, angulation of the cone changed when the second film is taken. If the object in

question moves in the same direction as the cone, it is lingually positioned. If the object moves in the opposite direction it is situated close to the source of radiation and is therefore buccally located.

b) Buccal Object rule

If the vertical angulation of the cone is changed by approximately 20° in two successive periapical films, the buccal object will move in the direction opposite to the source of radiation. On the other hand, the lingual object will move in the same direction as the source of radiation. The basic principle of this technique deals with the foreshortening and elongation of the images of the films.

ii) Occlusal films

To determine the buccolingual position of the impacted canine (provided the image of the impacted canine is not superimposed on the other teeth) [Figure 2].

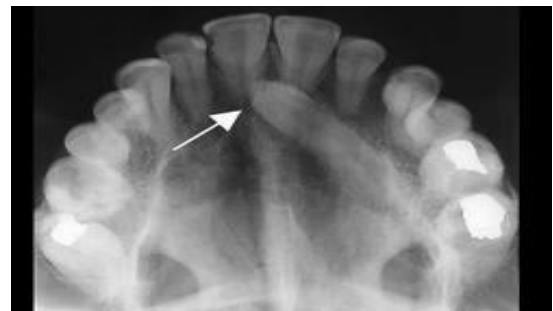

Figure 2: Occlusal radiograph showing position of impacted canine.

iii) Extra Oral films:

- a. Frontal and lateral cephalograms for determining the position of the impacted canine, particularly its relationship to other facial structures (eg. Maxillary sinus and the floor of the nose)
- b. Panoramic films to localize impacted teeth in all 3 planes of space (much the same as with 2 periapical films in the tube shift method, with the understanding that the source of radiation come from behind the patient, thus the movements are reversed for position) [Figure 3 (a & b)].

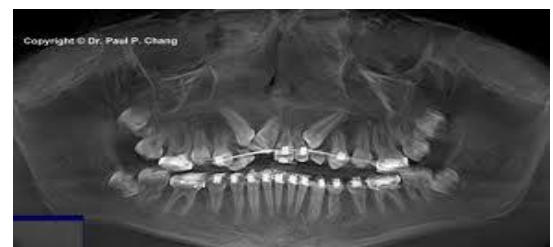

Figure 3 (a): Panoramic films and lateral cephalograms to show position of impacted teeth.

Advanced imaging:

Cone-beam computed tomography (CBCT):

Cone-beam computed tomography (CBCT) can identify and locate the position of impacted canines accurately [Figure 4]. By using this imaging technique, dentists also can assess any damage to the roots of adjacent teeth and the amount of bone surrounding each tooth.

In a study, Liu and colleagues [7] used CBCT to evaluate variations in the location of impacted maxillary canines. They found that the position of impacted maxillary canines varies greatly. Reports of maxillary canine impactions vary considerably in orientation, and CBCT provides information to dentists so that they can properly manage impacted canines surgically and orthodontically.

However, increased cost, time, radiation exposure and medico-legal issues associated with using CBCT, limit its routine use.

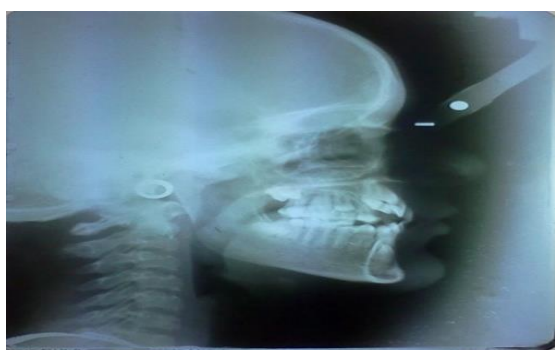

Figure 3 (b): Panoramic films and lateral cephalograms to show position of impacted teeth.

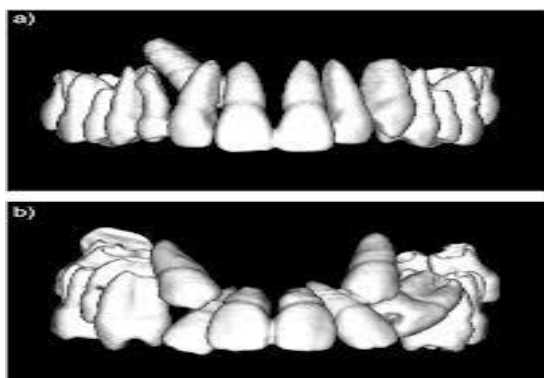


Figure 4: CBCT for determining the position of the impacted canine.

PROGNOSIS

Deep intraosseous location of the impacted canine can be assessed on the panoramic image by using the modified version of the criterion proposed by **Ericson & Kurol**.

The criteria used to define deep intraosseous impaction. The tracing made on panoramic radiographs.

The following lines are drawn and measurements made

- a) The midline.
- b) The occlusal plane (from the first molar to the incisal edge of the central incisor)
- c) The long axes of the central incisor, of the lateral incisor, of the first bicuspid and of the impacted canine.
- d) The angle between the long axis of the impacted canine and the midline (α).
- e) The distance between the cusp of the impacted canine and the occlusal plane.^[3]

The criteria to evaluate the position of the impacted canine.

- a. The most medial position of the crown is identified and the severity of the overlap assessed. Canines placed mesial to lateral incisor, distal to premolar, the success rate is less.
- b. The inclination or angulation of the long axis of the canine is measured in relation to the midline (angulation greater than 40° shows poor prognosis)
- c. The vertical height measured in millimeters from the canine tip to the occlusal plane (d >15mm again reveals poor prognosis).

PREVENTION OF MAXILLARY CANINE IMPACTION

When the clinician detects early signs of ectopic eruption of the canines, an attempt should be made to prevent their impaction and its potential sequelae.

Selective extraction of the deciduous canines as early as 8 or 9 years of age has been suggested by Williams as an interceptive approach to canine impaction in Class I uncrowded cases. **Ericson and Kurol** suggested that removal of the deciduous canine before the age of 11 years will normalize the position of the ectopically erupting permanent canines in 91 % of the cases if the canine crown is distal to the midline of the lateral incisor. On the other hand, the success rate is only 64% if the canine crown is mesial to the midline of the lateral incisors.

TREATMENT ALTERNATIVES

Each patient with an impacted canine must undergo a comprehensive evaluation of the malocclusion. The clinician should then consider the various treatment options available for the patient, including the following:

- a. No treatment if the patient does not desire it. In such a case, the clinician should follow 'Wait & Watch' policy.
- b. Auto transplantation of the canine.

- c. Extraction of the impacted canine and movement of a first premolar in its position. But both require meticulous handling.
- d. Prosthetic replacement of the canine, not amenable for juvenile patients.
- e. Transalveolar transplantation of maxillary canines.
- f. Surgical exposure of the canine and orthodontic treatment to bring the tooth into the line of occlusion. This is obviously the most desirable approach.

WHEN TO EXTRACT AN IMPACTED CANINE

The extraction of canine, although seldom considered might be a suitable option in the following situations

- a. If it is ankylosed and cannot be transplanted.
- b. If it is undergoing external or internal root resorption
- c. If its root is severely dilacerated,
- d. If the impaction is severe on central and lateral incisors and orthodontic movement will jeopardize these teeth.
- e. If the occlusion is acceptable, with the first premolar in the position of the canine and with an otherwise functional occlusion with well-aligned teeth
- f. If there are pathological changes (e.g. cystic formation, infection), and the patient does not desire orthodontic treatment.

PALATAL VERSUS LABIAL IMPACTIONS

It is estimated that the incidence of palatal impaction exceeds that of labial impaction by a ratio of at least 2:1 or 3: 1.

Ectopic labially positioned canines may erupt on their own without surgical exposure and orthodontic treatment, frequently high in the sulcus or alveolar ridge. On the other hand, palatally impacted canines seldom erupt without intervention. It is believed that this impeded eruption is due to the thickness of the palatal cortical bone, as well as the dense, thick and resistant palatal mucosa.^[2]

Palatally impacted canines are more often inclined in a horizontal / oblique direction, where as labial impactions offer more favorable vertical angulations. Yet they are still considered difficult because of the needed delicacy in managing the associated hard and soft tissues.

MANAGEMENT OF THE PALATALLY IMPACTED CANINE

These are numerous surgical methods for exposing the impacted canine and bringing it to the line of occlusion. Two of the most commonly used methods are

- a) Surgical exposure, allowing natural eruption, and
- b) Surgical exposure with placement of an auxiliary attachment. Orthodontic forces are subsequently applied to the attachment to move the impacted tooth.
- c) Surgical exposure to allow natural eruption to occur: This method is most useful when the canine has a correct axial inclination and does not need to be uprighted during its eruption. The progress of canine eruption, should be monitored with roentgenograms with the use of reference points such as adjacent tooth or the arch wire. Clark recommended that a polycarbonate, crown be placed over the impacted tooth after its surgical exposure. The crown should be made long enough to extend through a window cut in the palatal tissue. The crown is then cemented with a surgical paste or regular cement. Often 6 months to 1 year may elapse before the impacted tooth has erupted sufficiently to permit removal of the polycarbonate crown and its replacement with an orthodontic attachment. If the tooth fails to erupt. Clark recommends the removal of any cicatricial tissue surrounding the crown
- d) Surgical exposure with the placement of an auxiliary: After the surgical exposure of the impacted tooth, an auxiliary is attached to the crown. Such an auxiliary can be either directly bonded to enamel or indirectly attached to a cemented band or crown

Two approaches are generally recommended with regard to the timing of lacing the attachment.

- a. Lewis preferred a two-step approach. First, the canine is surgically uncovered and the area is packed with a surgical dressing to avoid the filling in of tissues around the tooth. After wound healing, within 3 to 8 weeks, the pack is removed, and an attachment is placed on the impacted tooth.
- b. The second method is a one-step approach: i.e. the attachment is placed on the tooth at the time of surgical exposure. The tissues over the attachment should be excised, and a periodontal pack should be placed. The pack will minimize patient discomfort and prevent the granulation tissues from covering the attachment before the clinician is ready to apply traction forces to the impacted tooth. This approach is particularly recommended for palatally impacted teeth. One of the important advantages of such an approach is that when the force is applied to the impacted tooth, the clinician is able to visualize the crown of the tooth and to have better control over the

direction of tooth movement. This will avoid moving the impacted tooth into the roots of the neighbouring teeth.

MANAGEMENT OF LABIALLY IMPACTED CANINE

Management of labially impacted canines involves a stepwise procedure as follows.

- a. Surgical exposure
- b. Placement of orthodontic attachment
- c. Traction force application

Surgical Exposure

The absence of an adequate band of attached gingival around the erupting canine may cause inflammation of the periodontium, **Vanarsdall and Corn** emphasized the danger to move teeth in the presence of inflammation. Tissue resistance to the stress of mastication and the function is less than optimal and loss of periodontal support is possible if precautions are not taken to alleviate such potential problems.

Therefore, it is recommended that surgical procedures, designed to expose impacted canine's eruption through the alveolar mucosa should simultaneously provide a band of attached gingival to the exposed tooth. Otherwise, improper soft-tissue management may lead to muco-gingival recession and loss of alveolar bone.

Various techniques are practiced to uncover labially impacted canine, The most common methods are:

- a. Excisional gingivectomy
- b. Apically positioned flap
- c. Closed eruption technique.

The aesthetic and functional outcomes of these procedures, such as gingival height, clinical crown length, width of attached gingiva, gingival scarring, relapse potential and attachment levels need to be critically assessed in order to identify the optional method of uncovering labial impactions.

Excisional Gingivectomy

Pioneer method of uncovering impacted canines, advocated radical bone removal to expose the crown of the impacted tooth so as to remove all bony obstacles and to provide an easier path for tooth movement. McDonald and Yap evaluated the relationship between the amount of bone removed during surgical exposure and the subsequent bone loss around the impacted tooth. They found that the more bone removed initially, greater the bone loss after orthodontic treatment.

Apically Positioned Flap

As said earlier, sufficient space is created to allow for the canine to be Positioned in the arch. The created space will provide an adequate zone of

attached gingival that can act as a donor site for the partial thickness apically or laterally repositioned flap.

Vanarsdall and Corn emphasized that the flap containing the keratinized tissue should be placed to cover the CEJ and 2 to 3 mm of the crown.

The apically positioned flap is a split thickness pedicle reflected from the edentulous area. The incisions extend vertically into the vestibule and split thickness flap is reflected. Bone covering the enamel is removed. Two thirds of the crown exposed, and the connective tissue follicle, curetted from the periphery of the exposed portion of the crown. The flap is then sutured to the periosteum, leaving one half to two thirds of the crown uncovered. A surgical dressing is placed on the enamel to prevent overgrowth of the adjacent tissue. The dressing is removed 1 week, post operatively and the attachment placed on the uncovered tooth.

Closed Eruption Technique

This is the best method of uncovering labially impacted teeth. It involves elevating a flap, placing an attachment on the impacted tooth returning the flap to its original location. If the tooth is displaced near the nasal spine pedicle flap is reflected. Orthodontic attachment placed and the flap is returned to its original position for complete closure. The orthodontic traction force is applied 1 week after creating a normal direction of tooth eruption.

Further, the excision gingivectomy and apical positioned flap have more unaesthetic sequelae than those uncovered with closed eruption technique. Negative aesthetic effects, such as increased clinical crown length, decreased width of attached gingiva, gingival scarring and intrusive relapse is evident.^[1]

Methods of Orthodontic Attachment

Different methods of attachment to the impacted tooth have been suggested. Earlier polycarbonate or gold crowns were cemented into the exposed crowns of impacted teeth.

- a. Wire lasso: The use of circumferential dead soft, ligature wire (Lasso) as an attachment has been fairly common. This method is not recommended, as too much of the bone has to be removed so that the wire can be placed around the tooth circumference. Further, increased incidence of ankylosis, external root resorption has been noted.
- b. Some other technique like drilling holes at canine tip and passing a ligature through the hole and with the help of this traction force is applied.
- c. The best method of orthodontic attachment is bondable mesh, bracket or lingual button with ligature chain or gold chain to the bonded

attachment. Furthermore, this has a conservative approach on the surgical exposure.

- d. Multiple eyelet chain.
- e. Recently, magnets (in attractive mode)

Methods of Applying Traction

Various methods have been used for moving the canine into proper alignment, these include the use of light wire springs soldered to a heavy labial or palatal base wire, mousetrap loops bent in the arch wire, and rubber bands. But with the introduction of new orthodontic materials such as elastic threads and elastomeric chains, the orthodontist has greater control of force magnitude and direction.

Regardless of the material used, the direction of the applied force should initially move the impacted tooth away from the roots of the neighbouring teeth. In addition, the following considerations are recommended.

- a. The use of light forces to move impacted tooth, no more than 2 ounces (60 grams) of force.
- b. Either availability or creation of sufficient space in the arch for the impacted tooth.
- c. Maintenance of the space by either continuous tying of the teeth mesial and distal of the canine or placement of a passive open coiled spring on the arch wire.
- d. Provision by the arch wire of sufficient stiffness (e.g. 0.018 x 0.022 inch) to resist deformation by the forces applied to its as the canine is extruded.

The added stiffness will minimize the undesirable roller-coaster effect caused by the intrusion of the anchor teeth as a reaction to the deflection of a lighter and hence more flexible arch wire.^[4]

1. Extrusion of Palatally Impacted Cuspids

To extrude palatally impacted cuspids into a more favourable position before moving them labially for incorporation into the arch.

Materials

- Kobayashi Hook
- Split rectangular extra oral hook
- Specially bent 0.018" wire.

The wire should have 2 helices, perpendicular to each other and about 1/8" apart; mesial and distal legs should extend about 1" past the helices.

Ligate the Kobayashi hook to the cuspid bracket before bonding the bracket and the exposed cuspid. Place a rectangular stabilizing wire in the arch. Crimp the extra oral hook, angulated labially and gingivally onto the rectangular stabilising arch wire opposite to the cuspid to be extruded.

Place the distal helix of the 0.018" wire, rotated towards the occlusal surface over the extra oral hook. Ligate the distal leg of the wire to the brackets over the stabilizing arch wire. Adjust the

mesial leg to produce the desired Jaunt and direction of extrusion force. Ligate the mesial leg to the K hook with round elastic.

2. Multiple Eyelet Chain for Impacted Teeth

After surgical exposure of an impacted tooth, the surrounding soft tissue, then covers the tooth and bracket of the extent that a second surgical procedure required to re-expose the tooth.

The following simple techniques can eliminate the need for these repeated exposures:

- Using an explorer and a Hemostat, bend multiple eyelets into a length of 0.012" ligature wire. For 3 mm spacing of the eyelets, manually twist the ligature wire around the explorer, twice, then tighten the twist with the Hemostat.
- After the tooth is exposed and a bracket is bonded to it, thread another ligature wire through the terminal eyelet and secure the eyelet chain to the bracket.
- Thread power chain through an available eyelet and tie it to the arch wire.

Reactivate the power chain at the next appointment by threading it through and appropriate eyelet, depending on tooth eruption and soft tissue coverage. Repeat until the tooth is fully erupted. (This multiple eyelet chain avoids a second surgical exposure or the replacement of elastic traction to a subgingival bracket under local anaesthesia).

- e. **Begg and Kesling proposed** a method wherein the distal end of the archwire is doubled-back and ligated to ligature extending from the impacted canine (attachment).

3. The Ballista Spring System For Impacted Teeth

Ballista spring -designed by **Harry Jacoby (1979)**

It is a 0.014, 0.016 or 0.018 inch round wire which accumulates its energy by being twisted on its long axis. Distally it passes through both headgear and edgewise vestibular tubes of the first or second maxillary molar and it is ligated to this tube so that it cannot rotate in the tubes.

The horizontal part of the wire accumulates the energy and is ligated on the first premolar allowing it to rotate in the slot of the bracket as a hinge axis. The last part of the spring (mesially) is bent down vertically and ends in a loop shape to which a ligature elastomeric thread can be attached. When the vertical portion of the spring is raised toward the impacted tooth, the horizontal part accumulates the energy into the twisted metal. When the vertical section is released, it bumps down like a "Ballista" (Roman missile).

The anchorage for molar is through a transpalatal 0.045 inch wire Since premolars (upper 4's) were intruded or shifted labially they were also included in the TPA

The force of the spring is proportional to the diameter of the wire and to the length of the horizontal and vertical parts of the spring. A 0.016 inch spring of average size provides a force of 60-100 gms; a 0.018 inch spring of average size provides a force of 120-150 gms. For a normal case, it is advised to start with a 0.016 inch wire and to change it to a 0.018 inch after a month. If, after 2 months of treatment, no progress is registered, because of severely impacted canines or tissue resistance, one can add a second spring in the same tube to increase the force operating on the impacted tooth.^[3]

4. Tunnel-Traction of Intraosseous Impacted Maxillary Canines

Deep intraosseous canines associated with persistent deciduous teeth may be successfully and safely treated by repositioned flap and tunnel traction toward the center of the alveolar ridge. This consists of raising a full thickness flap to expose the cortical plate. The deciduous canine is then removed. Cortical bone is removed to provide access to the crown and the follicular socket is eliminated. A low speed bur is inserted into the seat of the deciduous tooth's root to drill a perforation into the bone under careful cooling to reach the crown of the impacted tooth (canine). The perforation and the deciduous socket forms a tunnel that is used for traction. A handmade wire (ligature) chain of rings approximately 1.5 mm in diameter is prepared with 0.011" ligature wire which is passed through the osseous tunnel and fixed as closely as possible to the cusp of the impacted canine by means of an attaching device (bonded button/bonded bracket base / anatomically continued fine mesh/). The flap is then repositioned and sutured in its original seat. The chain passes through the bone tunnel and emerges from the socket of the deciduous tooth. The traction phase is started after one week when sutures are removed and directed to the center of the alveolar ridge.

5. Rare Earth Magnets and Impaction

Early work with magnets involved the use of cobalt, platinum alloy magnets. Since they costed several thousand per kg it prevented frequent experimentation.

An alloy of Al, Ni & Co., was then used owing to its favourable length diameter ratio (compared with samarium-cobalt). Due its larger flux leakage the adjacent tissue were exposed to larger fields and the tissue effects could be studied. Human experiments were then carried out using samarium-cobalt alloys, as the stored energy and forces were far superior to the Aluminium Nickel Cobalt Magnets.

Recently, an alloy, Neodymium-Iron-Boron has become available in various shapes and sizes for attachment to teeth. Produced by a powder

metallurgy process, they provide the highest energy per unit volume of any commercially available magnetic material. They are 70% more powerful than the same size samarium cobalt magnet. They are supplied in a magnetized condition with an electroplated tin protective finish, but they are brittle and need to be handled with care.

The unique characteristics of permanent rare earth magnets are suitable to counter side effects adjunct to impaction. The cardinal problem of impaction is the premature exposure of the impacted tooth to the oral environment.

A direct consequence of this measure is a non self-cleansing area that invites the vicious cycle of infection pathway, inflamed gingival tissue, apical migration of epithelial attachment, bony recession and exposed CEJ.^[4]

6. Two Arch Wire Technique for Alignment of Impacted Teeth

Surgical procedure involves apically positioned flap for superficial impaction and full thickness mucoperiosteal flap with a crestal incision for deeper impactions.

Traction attachment consists of an eyelet pad ligated to a gold chain, which is bounded to the impacted tooth near the tip of its crown. Flap is closed with the chain passing through the crestal incision. Orthodontic procedure consisting of placement of pre-adjusted O.022xO.028 brackets. An O/O14 "NiTi arch wire is cut, so that it passes through 2 or 3 brackets on either side of impacted tooth is used for attachment to the gold chain and a main arch wire is placed in the same bracket slots over the traction arch wire for anchorage and control of the arch form. Traction to the gold chain is reactivated every 4-6 weeks by removing links of chain and retying the chain to the traction arch wire.^[3]

Retention Considerations

Backer et al. evaluated the post treatment results of the impacted canines in patients whose orthodontic treatment had been completed. They observed an increased incidence of rotations and spacings on the impacted side in 17.4% of the cases, whereas on the control side the incidence was only 8.7%. The control side had an ideal alignment twice as often as the impacted side.

To minimize or prevent rotational relapse, a fiberotomy or a bonded fixed retainer may need to be considered by the clinician after completion of the desired movements and sometimes before the appliances are removed. Clark suggested that after the alignment of palatally impacted canines, lingual drift can be prevented by removal of a half-moon shaped wedge of tissue from the lingual aspect of the canine.

Case Presentation

Pre Treatment:

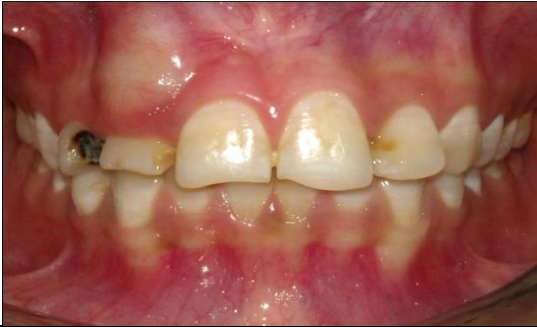

Figure 5: Visible bulge seen on the labial surface.

Post Exposure Bonding:

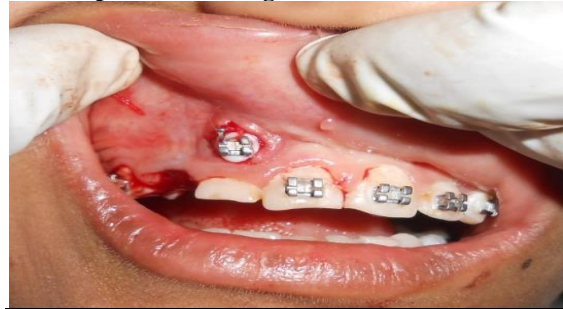

Figure 9: Post expose bonding with MBT 0.22 slot.

Radiographs

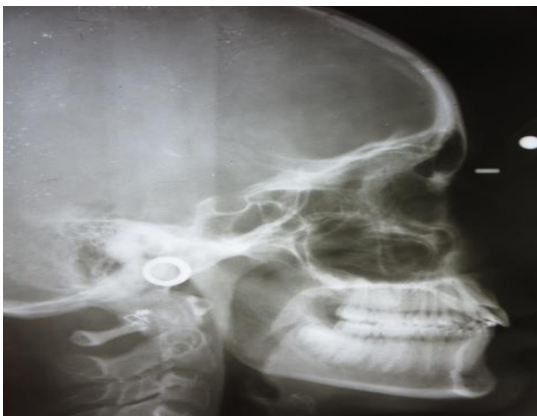

Figure 6: Lateral Cephalogram

Retraction:

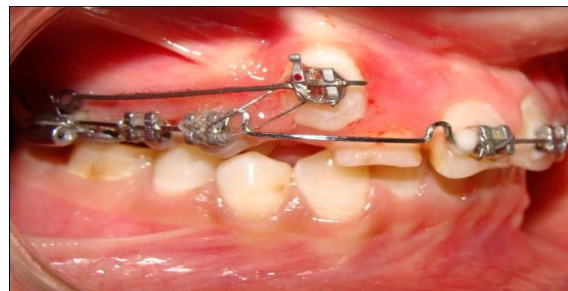

Figure 10: Retraction by using cantilever spring.

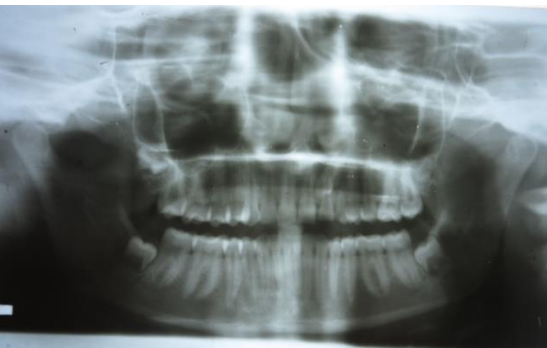

Figure 7: OPG

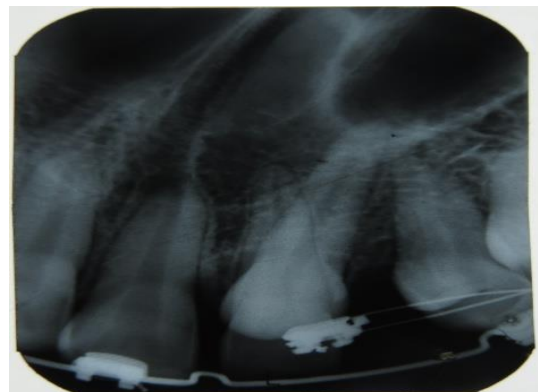


Figure 11: IOPA

Surgical Exposure:

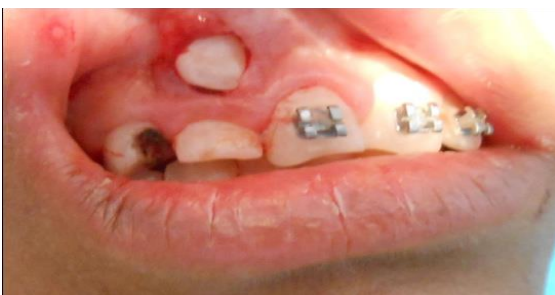

Figure 8: Surgically exposed canine.

Retraction using Cantilever, which is freely suspended over the canine bracket while the other end is fixed in auxiliary buccal tube

Alignment with initial NiTi wire:

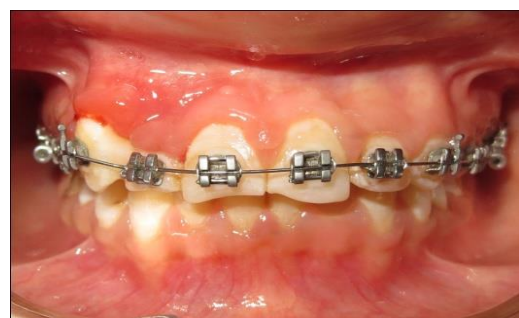

Figure 12 (a): Leveling and alignment with NiTi wire (Frontal View).

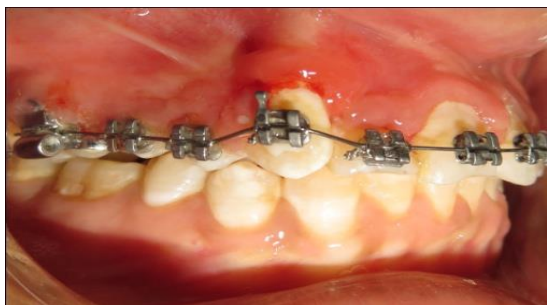


Figure 12 (b): Leveling and alignment with NiTi wire (Frontal View).

CONCLUSION

The management of the severely impacted canine is often a complex undertaking and enquires the joint expertise of a number of clinicians. It is important that these clinicians communicate with each other to provide the patient with an optimal treatment plan based on scientific rationale.

REFERENCES

1. Becker A, Chaushu S. Long-term follow-up of severely resorbed maxillary incisors after resolution of an etiologically associated impacted canine. *Am J Orthod Dentofac Orthop.* 2005; 127:650-4, quiz 754.
2. Becker A, Chaushu S. Impacted incisors and cuspids. *Bullet Pacific Coast SocOrthod.* 2004;76:27.
3. Chaushu S, Becker A, Zeltser R, Branski S, Vasker N, Chaushu G. Patients perception of recovery after exposure of impacted teeth: A comparison of closed-versus open-eruption techniques. *J Oral Maxillofacial Surg.* 2005; 63: 323-9.
4. Chaushu S, Becker A. The treatment of impacted teeth and the anatomy of failure. *Bulletin of the Pacific Coast Society of Orthodontists.* 2004;76:28-9.
5. Ziskind D, Sharon E, Hirschfeld Z, Becker A. Analysis of lateral tooth movement during forced orthodontic eruption. *J Prosthet Dent.* 2000;84:462-6.
6. Vanarsdall RL, Corn H. Soft-tissue management of labially positioned unerupted teeth. *Am J Orthod* 1977; 72:53-64.
7. Kalra V. The K-9 spring for alignment of impacted canines. *J Clin Orthod.* 2000;34:606-10.
8. Ericson S, Kurol J. Early treatment of palatally erupting maxillary canines by extraction of the primary canines. *Eur J Orthod.* 1988; 10:283-95.
9. Mitchell L, editor. *An Introduction to Orthodontics.* 3rd ed. New York: Oxford University Press; 2007. pp. 147-56.

How to cite this article: Vishnoi P, Keshubhai KJ, Surendra SS, Bandi N, Jingar J, Rutvik T. Maxillary Canine Impactions: Orthodontic and Surgical Management. *Ann. Int. Med. Den. Res.* 2016;2(3):2-10.

Source of Support: Nil, **Conflict of Interest:** None declared