

Variations and Anomalies of Coronary Artery System in Cadaveric Human Hearts.

Niha Aggarwal¹, Renu Mishra², A K Garg², Rajni Patel³, Ashish Goel⁴, Arsalan Moinuddin⁵

¹Resident, Department of Anatomy, Saraswati Institute of Medical Sciences, Hapur, UP, India

²Professor, Department of Anatomy, Saraswati Institute of Medical Sciences, Hapur, UP, India

³Assistant Professor, Department of Anatomy, Saraswati Institute of Medical Sciences, Hapur, UP, India

⁴Associate Professor, Department of Physiology, Shridev Suman Subharti Medical College, Dehradun, Uttarakhand, India

⁵Assistant Professor, Department of Physiology, Shridev Suman Subharti Medical College, Dehradun, Uttarakhand, India

ABSTRACT

Background: Knowledge of the normal and variant anatomy and anomalies of coronary circulation is an increasingly vital component in the management of congenital and acquired heart disease. Anatomical variations in relation to coronary artery and its branches will help cardiac surgeons for refining imaging techniques and coronary artery bypass grafting. The current study is aimed at understanding the normal patterns of coronary arteries with reference to its predominance, branching pattern, variations and anomalies. **Methods:** Heart specimen for this study were obtained from Department of Anatomy, SIMS Hapur and GFIMS Ballabgarh. The cadaveric human hearts were dissected to observe the coronary arteries and its branches. **Results:** The diameter of right and left coronary orifices were measured. The distance of the orifices from the supra-auricular ridge was also measured. The length and the diameter of the coronary arteries and its branches were measured and statistical significance was determined. **Conclusion:** The present study revealed that, ostium diameter of left coronary artery is larger than the right coronary artery. The outer diameter of the left coronary artery is larger than the right coronary artery. The mean lumen circumference of left coronary artery, anterior interventricular artery, right coronary artery and circumflex artery is more in males as compared to female. This knowledge is important for interpretation of the coronary angiography and surgical myocardial revascularization and paramount to cardiac surgeons for proper diagnosis and treatment of cardiac ailments and radiologists to refine image interpretation.

Keywords: Variations of coronary arteries, branching pattern.

INTRODUCTION

Wide variations exist in the size, position and shape of various body organs, finger prints and different individuals. Thousands of variations have been observed in the distribution of blood vessels in origin, length, branches, distribution and dominance of a coronary artery by investigators across the world.^[1] Variations of coronary arteries can cause important clinical manifestations, including sudden death of the individuals.^[2] According to the literature, coronary anomalies are observed in 1 percent of the general population.^[3] The increasing use of diagnostic and therapeutic interventional procedures necessitates that a sound, basic knowledge of the coronary artery pattern is essential. Knowledge of the normal and variant anatomy and anomalies of coronary circulation is an increasingly vital component in the management of congenital and acquired heart disease.^[4]

Name & Address of Corresponding Author

Dr. Arsalan Moinuddin,
Assistant Professor, Dept of Physiology,
Shridev Suman Subharti Medical College, Dehradun,
Uttarakhand, India
E-mail: drarsalan.moinuddin@gmail.com

It is well known that blood flow through arteries is influenced by various mechanical and hydraulic factors, but gender differences in morphometric features of coronaries like diameter and wall

thickness do not seem to have attracted much attention.^[5] The present work is an attempt to study the origin, course, variation and anomalies of coronary arteries in cadaveric human hearts.

MATERIALS AND METHODS

The heart specimen for this study are obtained from the department of Anatomy, SIMS Medical College, Hapur and Gold Field Institute of Medical Sciences & Research, Ballabgarh, Faridabad (HR). Ethical clearance from the institutional ethical committees of the respective institutes was taken before the study. Normal heart specimen, age groups 20-60 years with 32 males and 18 females were included. Heart specimen weighing more than 370 gms in males and 280 gms in females were excluded. Also, heart specimens of more than 60 age group and less than 20 years age group along with the abnormal hearts were excluded. The instruments implied include; hypodermic syringe 5 ml and 10 ml, digital Vernier calipers, compass and scale, painting materials like enamel paint, acetone, quick fix etc. and photographic Outfit and India Ink. After opening the thorax, pericardial cavity was opened, great vessels were ligated and the specimen of heart along with great vessels were removed from the thoracic cage. The specimen was immersed in 10% formaldehyde to preserve the specimen. The ostium diameter of the right and left coronary arteries and outer diameter of the

coronary artery and its branches were measured using digital Vernier caliper. The length of the vascular segments was measured using a compass. The compass was then measured on a scale which gave the length of the vascular segment. The mean of the measurements and its significance was calculated. The variations and anomalies were observed. To give contrast in photograph red enamel paint was used to paint the main coronary artery and their branches. The site of origin and distance from the supra valvular ridge. The ostium diameter was measured with caliper, the distance of

ostium from the supra valvular ridge was measured using compass and the compass was measured on a scale. The length and diameter of the vascular segments were measured in right and left coronary arteries and their branches. The branching pattern along with the dominance of arteries was noted. Also, the course and variations of the arteries with respect to origin, course, dominance and anomalies were noted.

RESULTS

Table 1: Mean ostium diameter, length, diameter and distance from supra valvular ridge measurements in right coronary artery and left coronary artery

S. No	Parameter	Right Coronary Artery (Mean±SD)	Left Coronary Artery (Mean±SD)
1.	Ostium Diameter (mm)	2.38±1.33	3.17±0.34
2.	Outer Diameter (mms)	5.38±0.81	5.73±0.74
3.	Length (cm)	6.95±0.75	1.35±0.27
4.	Distance from supra valvular ridge (mm)	1.34±0.36	1.38±0.32

The right coronary ostium was present in all the specimens in the right anterior aortic sinus. In 84.00% of the specimens, the ostium is below the supra valvular ridge and in 16.30% of the cases, the ostium is at the supra valvular ridge. The ostium diameter of L.C.A. is larger than the right coronary artery. The outer diameter of left coronary artery is larger than the right coronary artery. The length of right coronary artery is longer than the left coronary artery. The orifice of right coronary artery is nearer to the supra valvular ridge than the left coronary artery.

of the cases it is a branch of left coronary artery and in 16.66% of the cases showed balanced circulation.

Table 2: Point of termination of the posterior interventricular artery

Termination	Numbers	Percentage
¼ Way down posterior interventricular sulcus	04	06.66%
½ Way Down posterior interventricular sulcus	20	33.33%
¾ Way Down posterior interventricular sulcus	30	50.00%
At Apex	06	10.00%

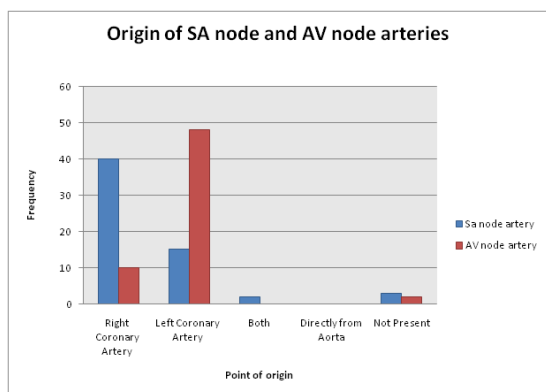


Figure 1: Origin of SA node and AV node arteries.

The dominance of the artery is determined by the posterior interventricular artery. It is termed right dominance if the posterior interventricular artery is a branch of Right coronary artery and, if the posterior interventricular artery is a branch of left coronary artery, it is termed left dominance. In 60% of the specimens, the posterior interventricular artery is a branch of right coronary artery in 23.3%

The mean length of posterior interventricular artery is 3.91 cm and the mean diameter of the vessel is 2 mm. In 3.3% of the specimens, the posterior interventricular artery runs 1/4th way down posterior interventricular sulcus. In 30% of the specimens, the vessels terminated half way down posterior inter ventricular sulcus. 33.33% of the specimens showed the artery terminating at 3/4th way down posterior interventricular sulcus and in 10% it terminated near the apex.

Table 3: Point of termination of right coronary artery

Point of termination	Numbers	Percentage
At Margo Acutus	01	01.66%
Between Margo Acutus and Crux	05	08.33%
At Crux	10	16.66%
Between Crux and Margo obtusus	35	58.33%
At Margo Obtusus	09	15.00%

The right coronary artery terminates near the crux at the crux and in some cases in front of crux. The mean outer diameter of right coronary artery is 5.38

with S.D. \pm 0.81 and the mean length of the right coronary artery is 6.95 with S.D. \pm 0.75.

Table 4: Contribution of right and left coronary arteries in the blood supply of posterior left ventricle, posterior right ventricle and anterior right ventricle.

	Left Coronary artery	Right Coronary artery	Number	Percentage
Posterior Left Ventricle	60	40	25	41.00%
	70	30	15	25.00%
	80	20	10	16.60%
	100	00	10	16.60%
Posterior Right Ventricle	90%	10%	040	66.60%
	100%	00	020	33.30%
Anterior Right Ventricle	80%	20%	38	63.31%
	90%	10%	10	16.60%
	100%	00%	08	13.30%
	70%	30%	02	03.33%
	60%	40%	02	03.33%

In 41% of the specimens, 60% of the posterior left ventricle is supplied by left coronary artery and 40% by right coronary artery. In 25% of the specimens, 70% of the blood supply of posterior left ventricle is supplied by left coronary artery and 30% by right coronary artery. In 16.6% of cases 80% blood supply is by left coronary artery and in 16.6% of cases the blood supply of the posterior left ventricle is 100% by left coronary artery.

DISCUSSION

A detailed normal study of coronary arteries would be of use to cardiologists and interventional radiologists to predefine the abnormalities by invasive studies and non-invasive studies. Knowledge of the normal and variant anatomy and anomalies of coronary circulation is an increasingly vital component in the management of congenital and acquired heart disease.^[4] Several studies have been conducted by various authors on origin of coronary artery and found many variations.

Our results showed that the right coronary artery arises from the anterior aortic sinus below the supra-avalvular ridge. In a study by Vlodayer et al. (1972) the author observed in most of the cases (56%) the orifice of the coronary arteries are situated in aortic sinus below the supra-avalvular ridge and in 8% of the cases the origin of right coronary artery occurred above the supra-avalvular ridge. He also observed that the left coronary artery originates normally.^[6] In another study, the author observed the right coronary ostium was present in the right anterior aortic sinus. The ostium was

below the sinotubular junction in 90%, at the sinotubular junction in 9% and above the sinotubular junction in 1% of the specimens.^[4] In the present study, the right coronary ostium was present in all the specimens in Right anterior aortic sinus. In 84% of the specimens, the ostium is below the supra-avalvular ridge and in 16.3% of the specimens, it is at the supra-avalvular ridge. The left coronary artery ostium is situated in the left posterior aortic sinus and in 93% of the specimens the ostium is present below the supra-avalvular ridge and in 6.66% of the cases it is situated at the supra-avalvular ridge. The location, level and size of the ostium is very important in the successful performance of coronary angiogram. MC Alpine (1975) determined the sizes of the coronary orifices in 100 hearts. The right coronary artery ranged in width from 0.5 to 7.0 mm (mean 3.7 ± 1.1 mm), the left coronary artery ranged in width from 1.8 + 8.5 mm (mean 4.7 ± 1.2 mm)^[7]

In the present study the right coronary artery ostium diameter mean is 2.38 with S.D. \pm 1.33 and the left coronary artery ostium diameter mean is 3.17 with S.D \pm 0.34 (P<0.001). In a study, the author observed the right coronary artery ostium was 38 mm above the supra-avalvular ridge. In the present study, the left coronary ostium was observed in 3.3% of the specimen 2 mm above the supra-avalvular ridge. Anomalous origins of the coronary arteries often cause heart disease in young patients and increase the risk of sudden death during physical exertion. Many workers have done a study on anomalous origin of the coronary artery. The author reported 33 autopsies. In that, 9 of them had a sudden death with an anomalous origin of the

left main coronary artery from the right sinus of valsalva.^[2] In another study by Liberthson et al 1974 reported a case of anomalous origin of left coronary artery from anterior aortic sinus.^[8] The first and highest branch of the proximal segment of right coronary artery, the conus artery arises in 36% of the cases from a separate ostium (third coronary artery), in the right aortic sinus of valsalva.^[9] In another study by Kalpana R. The author dissected 100 hearts and observed that the third coronary artery presents in 24% of the specimens.^[4] In the present study, the third coronary artery was present in 3.3% of the specimens studied. It originated from the right anterior aortic sinus. The diameter of the coronary ostium was 1 mm. In a study conducted by James, the author observed the diameter of the conus artery as 1 mm. In the present study, also the mean diameter of the conus artery is observed as 1.5 mm. The second branch of first segment of right coronary artery is the sinoatrial node artery, According to Uemura, (1999) the sinoatrial node artery arises from right coronary artery in more than 60% and from left coronary artery in less than 44% of the specimens. In other study, the author observed in 51% of the specimen sinoatrial node artery arose from right coronary artery and 41% from left coronary artery. In 8% of the specimens, the vessel arose from both right and left coronary artery.^[10] In another study conducted the author observed in 54% of the cases the sinoatrial artery is a branch of right coronary artery and in 42% of the specimens the artery arose from left coronary artery and in 4% of the cases the sinoatrial node artery was seen arising directly from aorta.^[11] In another study, the author observed in 58% of the specimens the sinoatrial node artery is a branch of right coronary artery and in 42% of the cases the vessel arose from left coronary artery and he has not noticed the origin of sinoatrial node artery directly from aorta.^[12] In the present study, in 66.66% of the specimens the sinoatrial node artery is a branch of right coronary artery and in 25% of the specimens the vessel is a branch of left coronary artery and in 3.3% of the specimens the sinoatrial node artery arose from both right and left coronary arteries.

James (1961) working on predominance of an artery noted in 90% cases posterior interventricular artery as a terminal branch of right coronary artery. In 10% of the cases the posterior interventricular artery arose from left circumflex artery.^[11] In another study by cavalcanti and loopes (1995), observed in 80% of the specimens showing right dominance and 11% of the cases showing left dominance.^[13] In another study conducted on predominance of coronary artery the author observed by angiographic method and found the highest incidence for right coronary type (53.3%), intermediate incidence for balanced circulation

(30.00%) and lowest incidence for left coronary type (16.7%).^[14] In another study by Varko T.S. et al. (1961) the author observed the predominance of the artery by angiographic method, observed the right dominance in 46.90% of the cases, and left dominance in 21.7% of the cases.^[15] In the present study, 60% of the specimens showed right dominance and 23.33% of the specimens showed left dominance and 16.6% of the specimens showing balanced circulation.

The left coronary artery bifurcates into left anterior descending and left circumflex artery. There are many variations in relation to branching pattern. In a study, the author noticed, in 60% of specimens the left coronary artery showed bifurcation pattern and in 38.18% of cases showed trifurcation branching pattern.^[14] In another study, the author noticed in 54.7% of the specimens showing bifurcation pattern and 38.7% cases showed trifurcation pattern. 6.7% of cases showing quadfurcation pattern. In a study by Kalpana R. the author observed that in 47% of the specimens the left coronary artery showed bifurcation pattern, 40% of the cases showed trifurcation pattern, 11% of the cases showed quadfurcation pattern 1% of the cases showed penta furcation pattern. In the present study 54% of the specimens showed bifurcation pattern, 25% of the cases showed trifurcation pattern and 1.5% of the specimens showed penta-furcation pattern.

The atrio ventricular node artery arises from the inverted loop is said to characterize right coronary artery at the crux where the PIV artery arises. In a study on coronary arteries, the author observed in 86% of the specimens the AV node artery arose from right coronary artery and in 12% of the specimens the vessel is a branch of left coronary artery and 2% of the cases the atrio ventricular node artery arose from both arteries.^[18] In the present study, 80% of the cases atrio ventricular node artery is a branch of right coronary artery and in 16.6% of the specimens the vessel is a branch of left coronary artery and in 3.3% of the specimens the atrio ventricular node artery is absent. In another study conducted by Donald N. Ronihilt et. al. 1968, observed in 84% of the specimens the atrio ventricular node artery is a branch of right coronary artery and in 15.3% of the specimens the vessel is a branch of the left coronary artery.^[19]

Baroldi and Scomazzoni (1967) gave means of 4 mm and 3.2 mm in case of coronary artery diameters at their origins, the left exceeds the right in about 60% of the hearts the right being larger in 17% and the vessels approximately equal in 23%.^[20] In another study by Kumar Keshav (2003), the author observed 10 mm circumference in case of both the coronary arteries 1 cm distal to their commencements. In the present study, the outer diameter is observed as 4.38 mm for right and 5.38

mm for left coronary artery, 1 cms distal from the origin.^[20]

To conclude, selective coronary arteriography that provides an accurate localization of the anatomical variants and underlying pathology, the advances made in coronary arterial bypass surgeries and modern methods of myocardial revascularization makes it imperative that a thorough, sound and complete knowledge of the normal and variant anatomy of coronary artery and circulation is required which led to this study.

CONCLUSION

The present study revealed that, ostium diameter of left coronary artery is larger than the right coronary artery. The outer diameter of the left coronary artery is larger than the right coronary artery. The mean lumen circumference of left coronary artery, anterior interventricular artery, right coronary artery and circumflex artery is more in males as compared to female. This knowledge is important for interpretation of the coronary angiography and surgical myocardial revascularization and paramount to cardiac surgeon for proper diagnosis and treatment of cardiac ailments and radiologists to refine image interpretation.

REFERENCES

1. Shubhangi Ramesh Mutyal, Nutan Dilipmandke, Medha Vijay Ambiyee. Study of Anatomical variation in origin of coronary arteries. *Int J Biol Med Res.* 2014; 5(1): 3802-3806
2. Cheitlin MD, Decastro CM, McAllister HA sudden death as a complication of anomalous left coronary origin from the anterior sinus of valsalva. *Circulation.* 1974; 50: 780.
3. Farzaneh Banki, Christopher T. Salerno, Gordon A. Cohen; Congenital anomalies of the coronary arteries. *MHBD054-CH74 (1329-1336).*
4. Kalpana RA. Study on principal branches of coronary arteries in Humans. *J. Anat. Soc. India.* 1962; 52(2):137-40.
5. Dhall U, Chaudhary S. Siorhiwal BL. Histomorphometric analysis of coronary arteries, sexual Dimorphism *J. Anat. Soc. India.* 2003.52(2):144-6.
6. Vloder Z, Newfeld HN, Edwards JE. Pathology of coronary disease seminars *Roentgenol.* 1972;7: 376-94.
7. McAlpine W. The heart and coronary arteries, Newyork: springer-Verlag: 1975.
8. Liberthson RR, Dinsmore RE, Bharati S. Rubenstein JJ, Caulfield J, Wheeler EU, Harthoren JW, Lew M. Aberrant coronary artery origin from the aorta, *circulation* 1974; 50: 774.
9. Grady L, Hallman MD, Denton A, Cooley MD, Don B, singer, MD. Congenital anomalies of the coronary artery; *Anatomy, Pathology and surgical treatment Surgery:* 1996;59(1):133.
10. Williams PL, banister LH, Berry MM Collins P, Dyson M, Dussek JE, Ferguson MWJ, *Grasy anatomy in : circulatory system* 38th Ed. Newyork; Churchill Livingstone: 1995.
11. Laurie W, Woods JD, anastomoses of the coronary circulation *lancet* 1958;2:812.
12. Thomas NJ. *Anatomy of coronary arteries,* New York: Harper and Rao publications inc; 1961.
13. Caetano AG and Lopes AC critical analysis of the clinical importance of the variations in the origin of sino-atrial node artery of the human heart *Rev. Assoc med Brass* 1995; 41(2):94-102.
14. Cavalcanti JS, anatomic variations of the coronary arteries *Arq. Bras cardiologia* 1995;65(6): 489-92.
15. Omar BK. Coronary artery Pre dominance. A new parameter for its study. *Journal of the anatomical society of India.* 1977;26(2):16.
16. Varko TS, Gutelius T, Sabistan Dc. A study of pre dominance of human coronary arteries determined by arteriographic and perfusion techniques. *American Journal of cardiology* 1961;8:379-84.
17. Baptista CA types of division of left coronary artery and the ramus diagonalis of the human heart. *Japanese Heart Journal* 1991;32(3):323-35.
18. Hollinshed WH. *Anatomy for surgeons vol. 2.* New York; Harper and Rao publications Inc; 1971.
19. Donald N, Ronihilt. Origin of blood supply to sino auricular and atrio ventricular Node: *American Heart Journal* 1968;75(2):279.
20. Baroldi G, scomazzoni *Grays Anatomy: Coronary circulation in the normal and pathologic heart* 38th Ed. Lond: Harcourt publishers: 2000.

How to cite this article: Aggarwal N, Mishra R, Garg AK, Patel R, Goel A, Moinuddin A. Variations and Anomalies of Coronary Artery System in Cadaveric Human Hearts. *Ann. Int. Med. Den. Res.* 2016;2(2):63-7.

Source of Support: Nil, **Conflict of Interest:** None declared