

Giant Cell Granuloma of the Maxilla: A Rare Case Report.

P.S Tripathi

Senior Lecturer, Department of Oral and Maxillofacial surgery, ABSMIDS, Mangalore, India

ABSTRACT

Giant cell granuloma (GCG) is an uncommon bony lesion in the head and neck region, most commonly affecting the maxilla and mandible and has a female predilection. The clinical behaviour of central GCG ranges from a slowly growing asymptomatic swelling to an aggressive lesion. The clinical, radiological, histological features and management of an aggressive GCG of maxilla in a five-month-old male child are described and discussed here. The emphasis lies that surgery is the traditional and still the most accepted treatment for GCG. Le Fort I osteotomy has been advocated as one of the access osteotomy for the surgical management of aggressive and extensive GCG involving the maxilla.

Keywords: Giant cell granuloma, Maxilla, Lefort I surgery, Cosmesis.

INTRODUCTION

The biologic behaviour of CGCGs ranges from a slowly growing asymptomatic swelling to an aggressive process associated with pain, cortical bone destruction, root resorption, displacement of teeth among other things. The pathogenesis of CGCG is not completely understood. The common treatment of CGCG is surgical removal. The case reported here is one such aggressive lesion treated with radical surgery.

Reported in this article is a rare case of sorts where CGCG of the maxilla (predilection more so for mandible) occurring in a five month old infant (usually presents in children or in young adults) male patient (twice as frequent in females) who was treated with surgery, bearing in mind the aesthetics to abolish any extra oral scar which would hamper his physiological and psychological development and the results hereby presented.

Name & Address of Corresponding Author

Dr P.S Tripathi
Senior Lecturer,
Department of Oral and Maxillofacial surgery,
ABSMIDS,
Mangalore, India.
E mail: tripathi12@gmail.com

CASE REPORT

Case Report

A five-month-old male infant was brought to our unit by his parents with a complaint of a slowly expanding, swelling of left maxilla that had started approximately two months earlier. The swelling considerably increased in size and extent over the span of one month [Figure 1a, 1b]. They also complained of nasal discharge and lachrymation on the left side. The child was irritable and was not feeding well. An extra-oral examination, there was an obvious swelling on the left side of the cheek and evident proptosis of the left eye. Vision and eye movements were tested to be satisfactory. Intra-oral examination revealed no obvious representation.

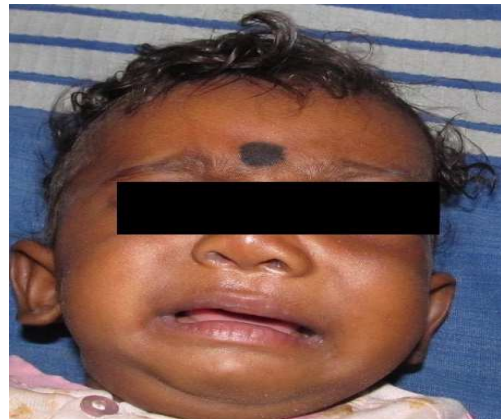

Figure 1a: Pre-operative pictures showing the extra oral presentation of lesion.

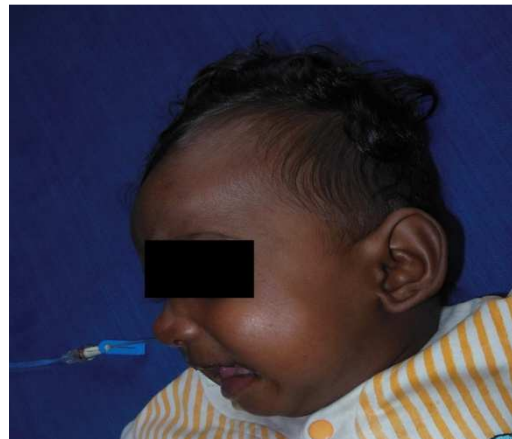

Figure 1b: Pre-operative pictures showing the extra oral presentation of lesion.

Radiographic Features

Computed tomography scan revealed a soft tissue mass completely obliterating the left maxillary sinus. The mass extended inferiorly into the body of the maxilla up to the alveolus and superiorly to the floor of the orbit. Medially it obliterated the nasal cavity and posteriorly, it reached the pterygoid plates. [Figure 2a] and [Figure 2b].

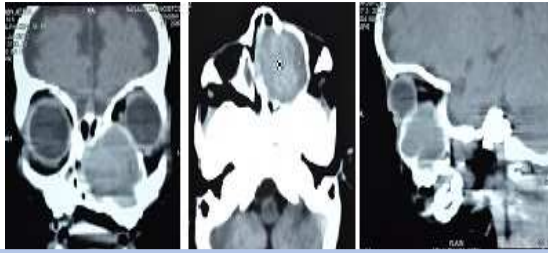


Figure 2a: CT Scans Revealing the extent of the lesion.

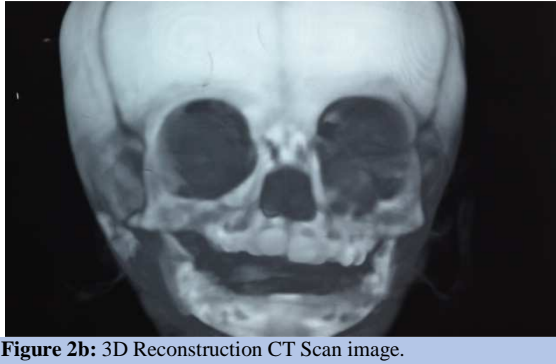

Figure 2b: 3D Reconstruction CT Scan image.

Histopathologic Features

An incisional biopsy was performed under local anesthesia through the nasal cavity. Tissue was removed from lesion located in maxillary sinus with a surgical curette and haemostasis was achieved and primary closure done. The specimen was submitted to the Oral and Maxillofacial pathology department. The histopathological examination showed the diffused distribution of giant cells and confirmed an aggressive GCG [Figure 3].

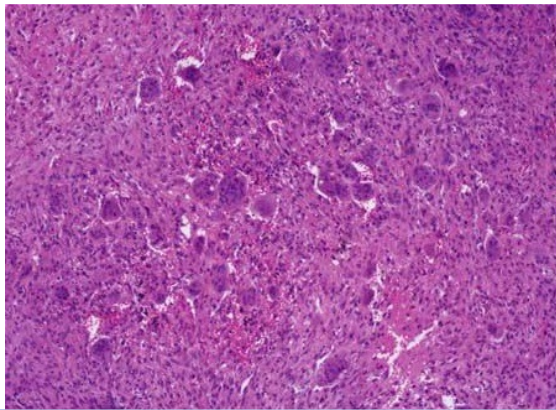


Figure 3: Photomicrograph of central giant cell granuloma.

Surgery

The patient was a young infant and aesthetics was a major concern to prevent untoward lifelong facial scar. Hence, an intra-oral approach was planned as opposed to the conventional extra-oral approach. Since the lesion was quite extensive involving the whole of maxillary antrum extending up to the left ethmoidal sinus, orbital floor and pterygoid plates, it was decided to perform a Le Fort I osteotomy to gain complete access to the entire lesion.

An intra-oral maxillary vestibular incision was made extending from the midline to the first molar region bilaterally. The underlying bone was exposed after sub-periosteal dissection and raising a full thickness flap. Le Fort I cuts were performed with rotary burs under copious irrigation extending bilaterally from the pyriform fossa to the pterygoid region followed by down fracture of the maxilla [Figure 4]. This provided excellent visibility and access to the entire lesion [Figure 4a].

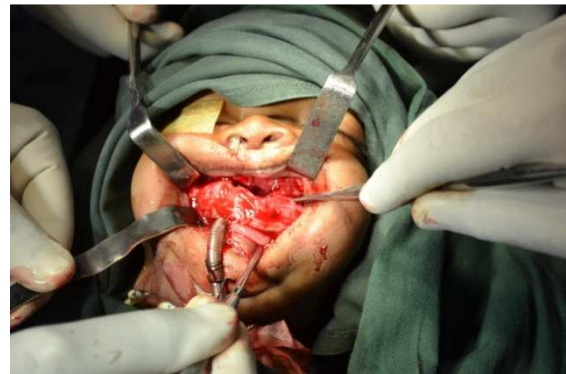

Figure 4: Le fort 1 access osteotomy and Maxillary down fracture.

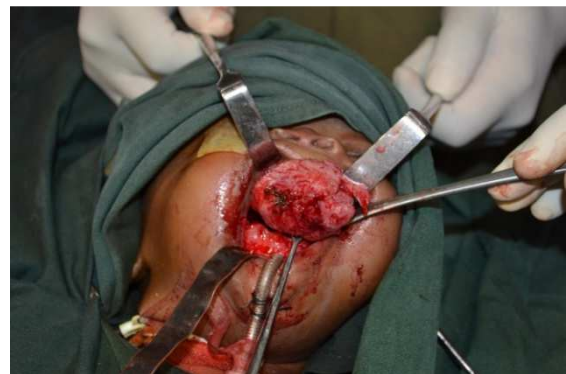

Figure 4a: Excellent access and visibility of the lesion.

The entire lesion was de-gloved from the adjacent tissues delineating from any vital tissues and was excised in toto [Figure 4b]. A fiber-optic endoscope was used to visualize the presence of any remnants [Figure 4c]. After thorough debridement and irrigation, haemostasis was achieved and then the osteotomised maxilla was reduced and secured into position [Figure 4d].

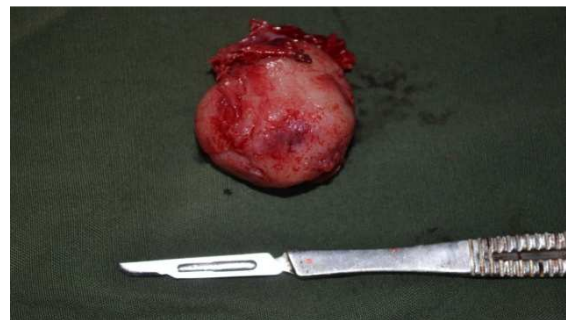

Figure 4b: Excellent access and visibility of the lesion.

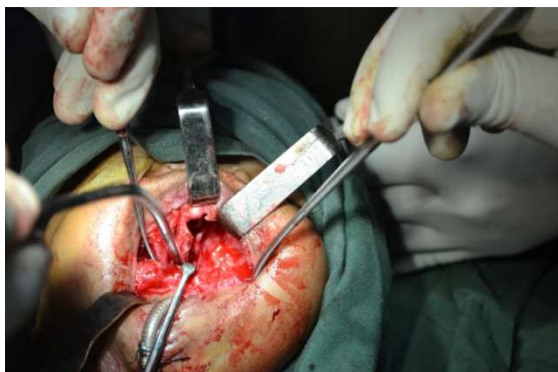

Figure 4c: Fibre optic endoscopic exploration to ensure complete excision.

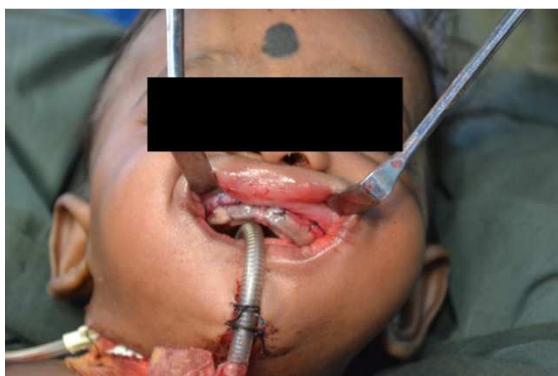

Figure 4d: Maxilla reduced and secured in position.

The incision was closed with resorbable sutures and intraoral pack was placed. Postoperative cosmesis was appreciable [Figure 5].

The patient was followed up at regular intervals for a period of six months after discharge.

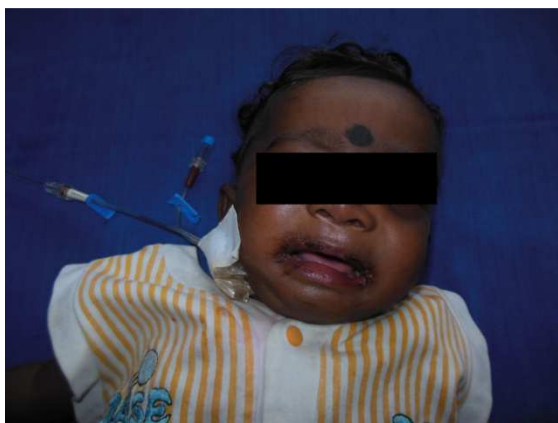

Figure 5: Immediate post operative cosmesis.

DISCUSSION

Giant cell granuloma (GCG) was first described by Jaffè in 1953 and the lesion is characterized by proliferation of fibroblasts and multinucleated giant cells, in a densely packed stroma.^[1] Central GCG (CGCG) (e.g., GCG of the mandible and maxilla bones) is less common than peripheral GCG of the

extremities^[2] and is usually a non-neoplastic bone lesion accounting for fewer than 7% of all benign tumors of the jaws.^[3-6]

They are defined by the World Health Organization as an intra-osseous lesion consisting of cellular fibrous tissue containing multiple foci of haemorrhage, aggregations of multinucleated giant cells and occasionally, trabeculae of woven bone.^[7] CGCG of the jaws mainly occurs in children or in young adults, almost twice as frequent in females than in males.^[5,8,9] It is more common in the mandible than in the maxilla (with a ratio of 2:1 to 3:1)^[4,9-11] and can be confined to the tooth-bearing areas of the jaws.^[4-6] CGCGs can also affect extra gnathic bones, mainly in the craniofacial region, and small long bones such as those of the hands and feet.^[12,13]

CGCG is a non-neoplastic proliferative lesion of unknown etiology and a recurrence rate between 13%^[14] and 49%.^[10,15] Chuong et al.,^[15] have classified CGCGs into aggressive and nonaggressive lesions based on biologic behaviour including the presence of pain, rapid growth, perforation of the cortex, and a tendency to recur. The etiology and pathogenesis of CGCG of jawbones has not been clearly established. The extent of the surgical intervention ranges from simple curettage to en bloc resection with resection for lesions of the maxilla or para-nasal sinuses has been advocated as the thin bony cortices and sinuses do not provide a good anatomic barrier. Corticosteroids and calcitonin are used for non-surgical management.

However, it has been suggested that the lesion results from an exacerbated reparative process to previous trauma and interosseous haemorrhage which triggers the reactive granulomatous process.^[16] Association of t(X;4)(q22;q31.3) with GCG has been reported.^[17,18]

Although CGCGs are benign osseous lesions, some authors separate CGCG into two types, referring to its clinical and radiographic features: (a) Nonaggressive lesion which are slow growing and asymptomatic, without cortical resorption or root perforation in affected teeth, which do not recur; and (b) Aggressive lesions, which are usually found in younger patients, are painful with rapid growth, often cause cortical perforation and root resorption and has a tendency to recurrence.^[19]

Predicting the behaviour of CGCGs that will exhibit a higher risk of recurrence after treatment has been problematic. The rate of recurrence varies between 13-49%.^[20] Whitaker and Waldron reported a mean interval between diagnosis and initial treatment and treatment of a recurrence of 21 months, with very few recurrences two years after initial treatment. The most reliable factors related to an increased risk of recurrence include clinical activity of lesions (72% of recurrence in the aggressive forms, 3% of recurrence in the

nonaggressive forms), younger patients, demonstrated perforation of cortical bone and tumour size.^[21] However, other studies have not been able to predict the clinical course of CGCGs from known histological or immuno-histochemical features.^[22]

The management of CGCG will depend on the clinical and radiographic findings. Generally, curettage of well-defined localized lesions is associated with a low rate of recurrence. In extensive lesions with radiographic evidence of perforation of cortex, a more radical excision is mandatory.

The Le Fort I osteotomy is now a commonly performed procedure, that has become the workhorse of maxillofacial surgery. These osteotomies should be used more frequently by surgeons trained in these techniques to obtain surgical access and removal of pathological lesions involving mid-face and inaccessible areas. Le Fort I osteotomy has also been explored as an adjunct to skull base tumor surgery. Advantages of Le Fort I osteotomy are many. This is an intraoral procedure, it gives excellent visibility and accessibility to the surgical area, it is easy to perform, with low complication rate and the absence of disfiguring facial incisions provides good cosmesis. [Figure 5] The complications of Le Fort I osteotomy include malocclusion, bleeding, perfusion deficiencies, devitalized teeth or periodontium. These can be avoided or minimized by careful manipulation of soft and hard tissues with good surgical skills. In this case a conservative management of an aggressive maxillary lesion was accomplished by intraoral curettage assisted by unilateral Le Fort I osteotomy. No postsurgical morbidity except for a transient infraorbital paresthesia was noticed. The patient did not have any disfigurement postoperatively. Incidence of recurrence after surgery is 4-20% and it usually occurs due to incomplete removal of the tumor. The patient was placed on a further follow up for a period of six months to note the recurrence of this aggressive lesion if any. Normal development of the facial skeleton (maxillary component) and no recurrence was noted.

CONCLUSION

Although extensive literature is available, clarity with respect to an entity of CGCG is not adequate. Giant cell granuloma is a rare disease of the head and neck region. It is a benign tumor, but in some cases, it is locally destructive. Surgery is the traditional and still most accepted treatment for GCGs, but it is important to bear in mind that, today, modern surgery can be performed in association with new approaches, in an attempt to avoid recurrence.

Our experience suggests that the Le Fort I osteotomy approach is an excellent surgical exposure for the removal of any extensive lesion invading into pterygopalatine, paranasal sinuses, infratemporal fossae and central skull base regions in the growing facial skeleton of paediatric patients. Although it significantly affects vertical but not horizontal growth, its cosmetic effect is negligible. Although it causes long-term dental denervation, which in most cases is undetected by patients it has distinct advantages over other traditional approaches by providing more direct vision, improved exposure, cosmesis and no complications.

REFERENCES

1. Jaffé HL. Giant cell reparative granuloma, traumatic bone cyst, and fibrous (fibro-osseous) dysplasia of the jawbones. *Oral Surg Oral Med Oral Pathol.* 1953;6:159-75.
2. Khafif A, Krempf G, Medina JE. Treatment of GCG of the maxilla with intralesional injection of steroids. *Head Neck.* 2000;22:822-5.
3. Dahlin D. Bone tumors. 4th ed. Springfield (IL): Charles C.Thomas; 1986. p. 119-40.
4. Kurtz M, Mesa M, Alberto P. Treatment of a giant cell lesion of the mandible with intralesional glucocorticosteroids. *Oral Surg Oral Med Oral Pathol Oral Radiol Endod.* 2001;91:636-7.
5. Regezi JA. Odontogenic cysts, odontogenic tumors, fibroosseous, and giant cell lesions of the jaws. *Mod Pathol.* 2002;15:331-41.
6. Stavropoulos F, Katz J. Central giant cell granulomas: a systematic review of the radiographic characteristics with the addition of 20 new cases. *Dentomaxillofac Radiol.* 2002;31:213-7.
7. Kramer IRH, Pindborg JJ, Shear M, editors. Histological typing of odontogenic tumours. 2nd ed. Berlin: Springer-Verlag; 1991. p. 31.
8. Waldron CA, Shafer WG. The central giant cell reparative granuloma of the jaws: an analysis of 38 cases. *Am J Clin Pathol.* 1966;45:437-47.
9. Auclair PL, Cuenin P, Kratochvil FJ, Slater LJ, Ellis GL. A clinical and histomorphologic comparison of the central giant cell granuloma and the giant cell tumor. *Oral Surg Oral Med Oral Pathol Oral Radiol Endod.* 1988;66:197-208.
10. Whitaker SB, Waldron CA. Central giant cell lesions of the jaws. A clinical, radiologic, and histopathologic study. *Oral Surg Oral Med Oral Pathol Oral Radiol Endod.* 1993;75:199-208.
11. Kaffe I, Ardekian L, Taicher S, Littner MM, Buchner A. Radiologic features of central giant cell granuloma of the jaws. *Oral Surg Oral Med Oral Pathol Oral Radiol Endod.* 1996;81:720-6.
12. Yamaguchi T, Dorfman HD. Giant cell reparative granuloma: a comparative clinicopathologic study of lesions in gnathic and extragnathic sites. *Int J Surg Pathol.* 2001;9:189-200.
13. Boedeker CC, Kayser G, Ridder GJ, Maier W, Schipper J. Giantcell reparative granuloma of the temporal bone: a case report and review of the literature. *Ear Nose Throat J.* 2003;82:926-9, 933-4,936-7.
14. Anderson L, Fejerskov O, Philipsen HP. Oral giant cell granulomas. A clinical and histological study of 129 new cases. *Acta Pathol Microbiol Scand.* 1973;81:606-16.

15. Chuong R, Kaban LB, Kozakewich H, Perez-Atayde A. Central giant cell lesions of the jaws: a clinicopathologic study. *J Oral Maxillofac Surg.* 1986;44:708-13
16. Ustundag E, Iseri M, Keskin G, Muezzinoglu B. Central giant cell granuloma. *Int J Pediatr Otorhinolaryngol.* 2002;65:143-146.
17. Donoff RB, Rosenberg AE. Case records of the Massachusetts General Hospital. Weekly clinicopathological exercises. Case 20-1993. A 23- year-old woman with a rapidly enlarging intraoral mass after a tooth extraction. *N Engl J Med.* 1993;328:1478-1483.
18. nal M, Karabacak T, Vayisoglu Y, Bagis HE, Pata YS, Akbas Y. Central giant cell reparative granuloma of the mandible caused by a molar tooth extraction: Special reference to the maneuver of drilling the surgical field. *Int J Pediatr Otorhinolaryngol.* 2006;70:745-748.
19. Cossio PI, Fuentes RM, Carranza AC, Lagares DT, Perez JL. Recurrent central giant cell granuloma in the mandible: Surgical treatment and dental implant restoration. *Med Oral Patol Oral Cir Buccal.* 2007;12:E229-232.
20. de Lange J, van den Akker HP, Klip H. Incidence and disease-free survival after surgical therapy of central giant cell granulomas of the jaw in the Netherlands. *Head Neck.* 2004;26:792-5.
21. Minic A, Stajcic Z. Prognostic significance of cortical perforation in the recurrence of central giant cell granulomas of the jaws. *J Craniomaxillofac Surg.* 1996;24:104-108.
22. Kauzman A, Li SQ, Bradley G, Bells RS, Wunder JS, Kandel R. Central giant cell granuloma of the jaws: assessment of cell cycle proteins. *J Oral Pathol Med.* 2004;33:170-176.
23. Ahuja P, Rathore AS, Chhina S, Manchanda A. Aggressive central giant cell granuloma mimicking giant cell tumor. *IJCRI.* 2011;2(2):5-10 .
24. Erol B, Ozer N. A case of central giant cell granuloma (CGCG) and its long-term follow-up. *Saudi Dent J* 1996;8(3):42-6.

How to cite this article: Tripti PS. Giant Cell Granuloma of the Maxilla: A Rare Case Report. *Ann. Int. Med. Den. Res.* 2016;2(1):57-61.

Source of Support: Nil, **Conflict of Interest:** None declared