

Development of Pubic Symphysis - A morphometric Study in Foetuses.

Mahboobul Haque¹, Nafis A Faruqi², S. M. Yunus³

¹Associate Professor, Department of Anatomy, S.R.M.S., I.M.S., Bareilly

²Professor, Department of Anatomy J.N.M.C., A.M.U., Aligarh

³Professor, Department of Anatomy J.N.M.C., A.M.U., Aligarh

ABSTRACT

Background: Pelvic dimensions display considerable individual, sexual and racial differences. Fetal pelvis has been utilized for sex determination as well as for prediction of congenital anomalies such as Down's syndrome. Congenital anomalies diagnosed during intrauterine life are sometimes very useful especially if it could be corrected because such crucial step will lead to normal development of fetuses. Many congenital abnormalities might directly involve the pubic symphyseal region. Developmental details and morphometric measurements of this joint in fetuses remain unknown or poorly documented. **Methods:** The study was conducted in the department of anatomy J.N. Medical College. A.M.U. Aligarh, on 41 human foetuses, which were divided into five groups according to the gestational age. Group I comprises foetuses of 14–18 weeks, group II 19–22 weeks, group III 23–26 weeks, group IV 27–30 weeks and group V more than 30 weeks. Vertical height and antero-posterior thickness of the isolated pubic symphysis was measured. Different dimensions of pubic symphysis. Pattern of growth of pubic symphysis were compared with gestational age. **Results:** Anterior and posterior vertical height and thickness of pubic symphysis at all the three levels i.e. upper, middle and lower grew constantly throughout intrauterine life. Different measurements of pubic symphysis showed variable growth rates in different groups of foetuses. **Conclusion:** The present morphometrical study on foetuses gives baseline dimensions of the symphysis at different gestational age, which can hint towards one of the many congenital anomalies afflicting it.

Keywords: Fetus, gestational age, morphometry, pubic symphysis.

INTRODUCTION

Pelvis can be regarded as a bony ring, which houses the genito- excretory organs. Part of the ring formed by the union of hip bones of the two sides in front at the pubic symphysis, containing a cavity having two segments, the false and true pelvis; each having its own dimensions which can be measured using X-ray or MRI. All pelvic dimensions display considerable individual, sexual and racial differences.^[1,2] Fetal pelvis has been utilized for sex determination^[3] as well as for prediction of congenital anomalies such as Down's syndrome.^[4]

Recent advancement in medical sciences has given a new concept in which foetuses has become patients. This new dimension of in-utero fetal therapy has made studies in foetuses relevant. Congenital anomalies diagnosed during intrauterine life are sometimes very useful especially if it could be corrected because such crucial step will lead to normal development of foetuses. Many congenital abnormalities might directly involve the pubic symphyseal region [gamble]. Information related to late foetuses are always relevant in newborns and neonates. Most of the previous studies on pubic symphysis are in animals.^[6]

Although literature regarding morphometry of symphysis pubis in adults and children are available, developmental details and morphometric measurements of this joint in foetuses remain unknown or poorly documented.^[7] Therefore this study was undertaken with the aim to find out different dimensions of pubic symphysis in developing human foetuses and to possibly determine the pattern of growth taking place in the pubic symphysis throughout fetal life and to compare the result with that in the adults.

MATERIALS AND METHODS

The study which was conducted over a period of two years between October 2004 to August 2006, after taking a formal clearance from the institutional ethical committee, in the department of anatomy J.N. Medical College. A.M.U. Aligarh comprised of well preserved 41 human foetuses, from the department museum. All the Foetuses were carefully observed for any obvious musculo-skeletal anomalies, absence of which formed the inclusion criteria for the study. Foot lengths of the fetuses were measured for their gestational age.^[8] For the purpose of study fetuses were divided into five groups according to the gestational age. Group I comprises fetuses of 14–18 weeks, group II 19–22 weeks, group III 23–26 weeks, group IV 27–30 weeks and group V more than 30 weeks.

Name & Address of Corresponding Author

Dr. Mahboobul Haque
Associate Professor
Department of Anatomy
S.R.M.S., I.M.S., Bareilly, India
E mail: docmhaque@rediffmail.com

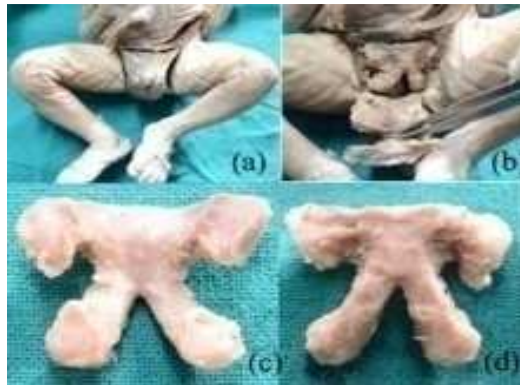

Figure 1: (a) incision (b) removal of soft tissue & excision of superior and inferior pubic ramus. Pubic symphyseal region after isolation (c) dorsal aspect (d) ventral aspect.

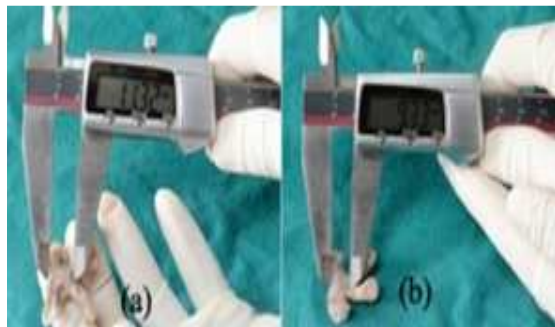


Figure 2: measurement of the symphysis (a) anterior vertical height (b) posterior vertical height.

Dissection of the pubic symphyseal region was done [Figure 1a, b] and the dissected symphyses along with pubis were cleaned of all the adhering soft tissues under a dissecting microscope [Figure 1c, d]. Morphometry of the pubic symphysis was done with the help of digital calipers and the measurements recorded. Measurements in the antero-posterior plane (thickness) at the upper end, in the middle and at the lower end were taken. Similarly, anterior (ventral) and posterior (dorsal) height in the vertical plane of the isolated pubic symphysis were taken [Figure 2a, b]. Statistical analysis of the readings using students't' test were done [Table 1].

RESULTS

The increase in the external anterior vertical height of pubic symphysis made steady progress throughout intrauterine life, with highly significant growth observed in groups II, III and V (p value<0.001) and significant growth in IV (p value<0.02). The rate of growth gradually reduced with gestational age of the fetus [Table 1]. Thus in-group II the gain in vertical height of the pubic symphysis was maximum (+43% difference) gradually decreasing in the last group V to a minimum value (+4% difference).

Table 1: Measurements of pubic symphysis in different groups (AVH- anterior vertical height, PVH- posterior vertical height)

Groups (n)	I(10)			II(10)			III(7)			IV(7)			V(7)		
	Mean ±SD	P value	% difference	Mean ± SD	P value	% difference	Mean ± SD	P value	% difference	Mean ± SD	P value	% difference	Mean ± SD	P value	% difference
AVH	4.57 ±0.79	-	-	6.53 ± 0.72	<0.001	+ 43	8.66 ± 0.96	<0.001	+ 33	10.89 ± 0.94	< 0.02	+ 26	11.37 ± 1.00	<0.001	+ 4
PVH	3.61 ±0.56	-	-	5.58 ± 0.49	<0.001	+55	7.56 ± 0.99	<0.001	+35	9.16 ± 0.94	<0.001	+21	9.63 ± 0.67	< 0.05	+5
Thickness Upper end	1.90 ± 0.34	-	-	2.81 ± 0.48	<0.001	+49	4.09 ± 0.50	<0.001	+45	4.80 ± 0.56	<0.001	+17	5.59 ± 0.72	<0.001	+16
Thickness middle	2.08 ± 0.46	-	-	2.86 ± 0.41	<0.001	+38	4.04 ± 0.51	<0.001	+41	4.77 ± 0.43	<0.001	+18	5.54 ± 0.50	<0.001	+16
Thickness Lower end	1.24 ± 0.29	-	-	1.69 ± 0.27	<0.001	+36	2.54 ± 0.45	<0.001	+50	2.82 ± 0.42	<0.001	+11	3.96 ± 0.59	<0.001	+40

The increase in intrapelvic posterior vertical height of pubic symphysis followed more or less the same trend as was evident in the external anterior vertical height [Table 1]. Highly significant growth was observed in groups II, III and IV (p value<0.001) and significant growth (P value <0.05) in-group V. The rate of growth decreasing with gestational age of the fetus as in anterior vertical height. Thus in-group II the gain in vertical height of the pubic symphysis was maximum (+55% difference) gradually decreasing in group V to a minimum value (+5% difference).

Anteroposterior thickness of pubic symphysis at the upper end showed steady growth throughout intrauterine life [Table 1] as the P value was highly

significant (<0.001) in all the groups. There was a growth spurt in groups II and III i.e. between 19-26 weeks of gestation. The growth was maximum (+49% difference) during 19-22 weeks and slightly less (+45% difference) during 23-26 weeks of gestation. However, it slowed down during later stages of the intrauterine life i.e. after 26 weeks. Pubic symphysis in the middle [Table 1], followed the same growth pattern as was evident at the upper end with highly significant growth (p<0.001) in all the groups. The maximum growth (+41% difference) was witnessed during the 23-26 weeks of intrauterine life in contrast to upper end that showed maximum growth (+49% difference) during 19-22 weeks of gestation.

Growth pattern of pubic symphysis at the lower end [Table 1] was quite similar to one witnessed at the upper end and in the middle. It showed a steady increase in thickness throughout intrauterine life with highly significant P value (<0.001) in all the age groups of gestation. Maximum gain in the thickness occurred during 23- 26 weeks of intrauterine life (+50% difference) and in last group i.e. >30 weeks of gestation (+40%).

DISCUSSION

The pelvic bones are formed by endochondral ossification in which primary centers of ossification develops. Cartilage templates for pelvic elements and lower limb develop by seven weeks. Primary centers for ilium appear at eight to nine weeks, for ischium in the third or fourth months and lastly for the pubis roughly at four to five months.^[9]

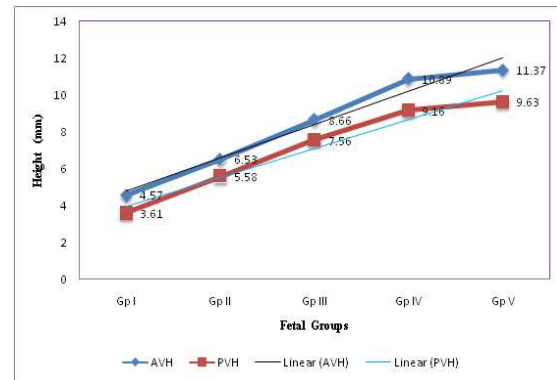
By the end of second month the two cartilaginous pubic masses meet and fuse in the midline in the region of the future symphysis^[10] resembling the adult joint.^[11] The pubic symphysis can be seen at 9.5 weeks but is not clearly visible until 18 weeks.^[12] At birth the symphysis is 9-10mm in width^[5] the connection between the pubic bones is uninterrupted, consisting posteriorly and superiorly of cartilage, anteriorly and inferiorly of vascularized ligamentous connective tissue.^[13]

The prenatal development of the human pelvic bone and acetabulum has been studied by means of classical histology^[14] and microradiography^[15] or ultrasonography and radiology both.^[16]

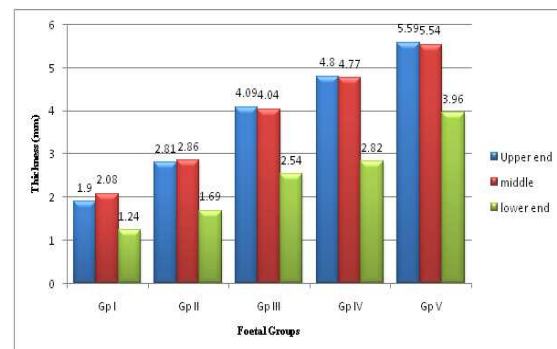
The fetal development of the pelvis and acetabulum seems to be highly related to mechanical stimuli, the most important being the gluteal muscular activity and the simultaneous pressure of the femoral head.^[17] Antenatal studies have not revealed much about pelvic morphometry and its complexities in fetuses or alterations in size and shape during gestation.

Mean vertical height on the anterior (ventral) aspect always remained greater than the mean posterior (dorsal) aspect with significant growth (p value <0.001) throughout gestational age suggesting a correlation between the two [Graph 1] and a possible parameter for fetal age determination. Many studies on fetal age determination either by appearance of ossification centres by radiography^[18] measurement of lengths of the major limb bones by ultrasonography^[19] or after fetal dissection^[20] had been done.

No literature is available on fetal pubic symphysis for comparison. However it is observed in adults that there is an increase in the symphyseal component of the pubis with advancing age^[21] and that the joint is more wider anteriorly than posteriorly^[22] this could be one of the possible reason for the difference in the two heights, which is reflected in the foetuses also.



Graph 1: comparison between anterior vertical height(AVH) and posterior vertical height(PVH).



Graph 2: antero-postero thickness in different foetal groups.

If we compare the antero-postero thickness between the three level of measurements, it is obvious the mean values at the upper end and in the middle at different gestational age is more or less same [Graph 2] and they grew almost at the same pace(% difference) after 22 weeks of gestation while at the lower end mean thickness always remained lower. If we analyze the antero-postero thickness at all the three level of measurements and the vertical height of the pubic symphysis then maximum per cent gain in the thickness of the symphysis, occurred in group II fetuses i.e. between 19-22 weeks of gestation which coincides with the appearance of the primary ossification centre for pubis [Table 1].

Growth pattern of the pubic symphysis was studied in different age groups of the fetuses in the anteroposterior plane at three levels i.e. upper, middle and lower. No parallel studies exist in literature for comparison. However in one of the studies in the pediatric population (2 years and 15 years) Nejad et al reported that the width of the pubic symphysis decreases during transition from infancy towards skeletal maturity.^[23] This finding was further strengthened by the findings of Chiba et al^[24] who showed that thickness of the connective tissue of the pubic symphysis decreases with age.

CONCLUSION

Pubic symphysis is longer anteriorly and thicker in the upper part throughout intrauterine life. The vertical height (anterior and posterior), of the pubic symphysis showed spurt of growth in-group II fetuses. Thickness of pubic symphysis invariably showed spurt of growth in-group III fetuses. Thickness of pubic symphysis at all the three levels i.e. upper, middle and lower grew constantly throughout intrauterine life. Different measurements of pubic symphysis showed variable growth rates in different groups of human fetuses.

The present morphometrical study on fetuses gives baseline dimensions of the symphysis at different gestational age which can hint towards possible intrauterine growth retardation or one of the many congenital anomalies afflicting it. Further studies are required to corroborate the findings of this study in different population groups.

REFERENCES

1. Iscan MY. Assessment of race from the pelvis. Am. J. Phys. Anthropol. 1983 oct; 62(2):205-8
2. Partha Pratim Mukhopadhyay. Determination of Sex from Fragment of Hip Bone In Indian Bengali J Indian Acad Forensic Med. October-December 2012, Vol. 34, No. 4:309-11
3. Fazekas I.G. and Kósa F. Forensic Fetal Osteology. Akademiai Kiado, Budapest. 1978.
4. Lee W, Balasubramaniam M, Yeo L, Hassan SS, Gotsch F, Kusanovic JP, Goncalves LF, Romero R. Iliac crest angle: a novel sonographic parameter for the prediction of Down syndrome risk during the second trimester of pregnancy. Ultrasound Obstet Gynecol. 2010;35:163-71
5. Gamble JG, Simmons SC, Freedman M. The symphysis pubis. Clin Orthop Related Res. 1986; 203:261 - 272.
6. Ortega H. H., Munoz-de-Toro M. M. , Luque E. H. and Montes G. S. Morphological characteristics of the interpubic joint (Symphysis pubica) of rats, guinea pigs and mice in different physiological situations. A comparative study, CellsTissues Organs. 2003; 73 (12): p105-14
7. Sadler TW. Langman's Medical Embryology. 13th ed. Philadelphia: Wolters Kluwer 2015. Chapter 12, Limbs; pp 163-74.
8. Streeter GL. Weight, sitting height, head size, foot length & menstrual age for human embryo. Contribution to Embryology. 1920; 11: p 143.
9. Susan Standring . Pelvic girdle, gluteal region and thigh. In Grays Anatomy- The Anatomical Basis of Clinical Practice, 40th ed. Elsevier Churchill Livingstone, London. 2008. ch80,1349-85.
10. Louise Scheuer, Sue Black, Craig Cunningham. Developmental Juvenile Osteology Academic Press. 2000 – the pelvic girdle ch 10 p341-373
11. Moore K, and Persaud T. The developing human: Clinically oriented embryology. 7th ed. Elsevier India, New Delhi 2003, ch 15. p381-99
12. J.P. McAuley and H.K. Uthoff. The Development of the Pelvis. In: The Embryology of the Human Locomotor System. Springer-Verlag-New York. 1990. p. 107-117
13. Putschar W.G. The structure of the human symphysis pubis with special consideration of parturition and its sequelae. Am J Phys Anthropol. 1976;45: 589-94
14. Sutro C. J. The pubic bones and their symphysis. Arch. Surg. 1936; 33: p 813-20.
15. Caffey J, Ross S., Pelvic bones in infantile mongoloidism-roentgenographic features. Am J Roentgenol. 1958; 80:458-467
16. van Zalen-Sprock,R.M., Brons, J.T.J.,van Vugt, J.M.G., van der Harten, H.J. and van Geijn, H.P., Ultrasonographic and radiologic visualization of the developing embryonic skeleton Ultrasound Obstet. Gynecol. 1997;(9): 392-7
17. Delaere O, and Dhém A. Prenatal development of the human pelvis and acetabulum. Acta Orthopaedica Belgica. 1999; 65(3):255-260.
18. Øystein E. Olsen, Rolv T. Lie, Ralph S. Lachman, Helga Maartmann-Moe, Karen Rosendahl., Ossification in Infants Who Die during the Perinatal Period: Population based References, Radiology. 2002; 225 (1):240-244
19. Wu X, Yang T, Li Y, Sun Z. The human fetal development time table of the major limb bones-ultrasonic bone age. Hua Xi Yi Ke Da Xue Xue Bao. 1995; 26(1):20-2
20. Vidhu Dhawan, Kanchan Kapoor, Mahesh Sharma, Balbir Singh and Alka Sehgal Morhometry of fetal femora as an indication of gestational age Eur. J. Anat. 18 (2): 85-92 (2014)
21. Dihlmann W. and Heinrichs V. Pelvic roentgenometry of the third kind : age and sex related measurement results in adulthood. Rofo. 1992; 156(5): 420 - 4.
22. Vix V. A. and Ryu C. Y. The adult symphysis pubis: normal and abnormal. Am J Roentgenol Radium Ther Nucl Med. (1971); 112 (3): p 517-25.
23. Nejad AH, Jamali A, Wootton-Gorges SL, Boakes JL, Ferguson TA. Symphysis pubis width in the pediatric population: A computerized tomography study.J Trauma Acute Care Surg. 2012 Oct; 73(4):923-7.
24. Chiba F, Makino Y, Motomura A, Inokuchi G, Torimitsu S, Ishii N, Kubo Y, Abe H, Sakuma A, Nagasawa S, Saitoh H, Yajima D, Hayakawa M, Miura M, Iwase H. Age estimation by quantitative features of pubic symphysis using multidetector computed tomography. Int J Legal Med. 2014 Jul; 128(4):667-73.

How to cite this article: Haque M, Faruqi NA, Yunus SM. Development of Pubic Symphysis - A morphometric Study in Foetuses. Ann. Int. Med. Den. Res. 2016;2(2):59-62.

Source of Support: Nil, **Conflict of Interest:** None declared