

Double Trouble: A Case of Local Anaesthetic Toxicity Followed By Tension Pneumothorax in a Patient of Marfan Syndrome.

Shahna Ali¹, Manazir Athar², Amrin Badar³, S Moied Ahmed⁴

¹Assistant Professor, Department of Anaesthesiology, JNMC, AMU, Aligarh (India).

²Senior Resident, Department of Anaesthesiology, JNMC, AMU, Aligarh (India).

³Junior Resident, Department of Anaesthesiology, JNMC, AMU, Aligarh (India).

⁴Professor, Department of Anaesthesiology, JNMC, AMU, Aligarh (India).

ABSTRACT

Spontaneous pneumothorax in patients with Marfan syndrome is common. Even a small pneumothorax can become a tension pneumothorax under positive pressure ventilation. Sometimes anaesthesiologists have to cater to more than one complication intraoperatively. Thorough knowledge of the subject and availability of monitors and anaesthesiologist in the operation theater as in general anaesthesia during locoregional anaesthesia is mandatory to avoid occurrence of catastrophe.

Keywords: Peribulbar anaesthesia, Local anaesthetic toxicity, Marfan syndrome, Tension pneumothorax.

INTRODUCTION

Local anaesthetic toxicity is a well-known complication of Peribulbar Block Anaesthesia.^[1] Technical expertise, knowledge of the subject and presence of Anaesthesiologist in operating room with same standards of monitoring as in General Anaesthesia is mandatory during locoregional anaesthesia to avoid occurrence of any catastrophe.^[2]

Marfan syndrome is associated with spontaneous pneumothorax in 4.4% in more than 12 years old.^[3]

Name & Address of Corresponding Author

Dr Shahna Ali

Assistant Professor,

Department of Anaesthesiology,

JNMC, AMU, Aligarh (India).

E mail: drshahna.farhan@gmail.com

CASE REPORT

A 27 year old female, of 80 kg, known case of Marfan Syndrome was scheduled for lensectomy. Right eye for Ectopia Lentis under Locoregional anaesthesia. Medical history suggestive of Marfan syndrome included a positive family history, decreased vision, on examination, we had an arm span to height ratio of 1.09, long slender fingers, high arched palate, axial length of RE:27.97mm and LE:27.75 mm. Routine investigations did not reveal any abnormality. Under strict aseptic precautions and following the proper technique, peripulbar block was performed with two injections in primary gaze. First injection in lower temporal peribulbar space and second in upper nasal peribulbar space Anaesthetic mixture consisted of 2% lidocaine and 0.5% bupivacaine. After 6-7 mins patient had generalized tonic clonic seizures. As anaesthetist was present in the OT for a case in GA, the patient was promptly managed by the team. The

patient was given iv midazolam 3 mg for seizures and monitors were attached with PR-90, BP 110/76, SPO₂ of 90%, but since there was a falling saturation RSI was done by inj Propofol 150 mg and in Succinylcholine 50 mg followed by 100 mg Fentanyl. Intubation was confirmed by capnography and auscultation of chest. Samples were sent for sugar, electrolytes, acid base balance. Even after intubation, oxygenation did not improve and there was circulatory collapse, which did not respond to fluids and vasopressors. Monitors displayed a decrease in SPO₂ from 90-86% and ETCO₂ from 36-24 and there was an increase in PIP from 25-39. Immediately cause for raising PIP was sought for and on auscultation, it was revealed that there was no entry on the right side of the chest. Needle was inserted in second ICS in midline, air was aspirated, and diagnosis of pneumothorax was made. Immediate chest tube was inserted and there was a rise in ETCO₂ and normalization of hemodynamic parameters. The surgery was abandoned and patient was shifted to ICU for further cardio pulmonary support. Patient was extubated in the evening without any neurological derangement. Patient was discharged from the hospital after lung expanded and ICTD was removed.

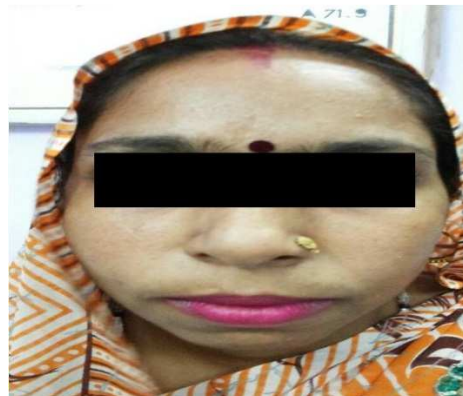

Figure 1: Marfanoid features: malar hypoplasia, retrognathia



Figure 2: Arm span length 170cm; Height 155cm
arm span height ratio>1.05

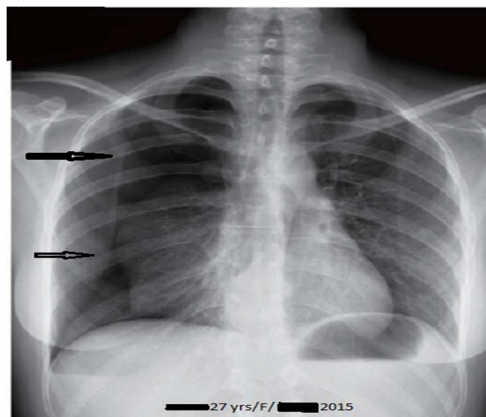


Figure 6: Right pneumothorax

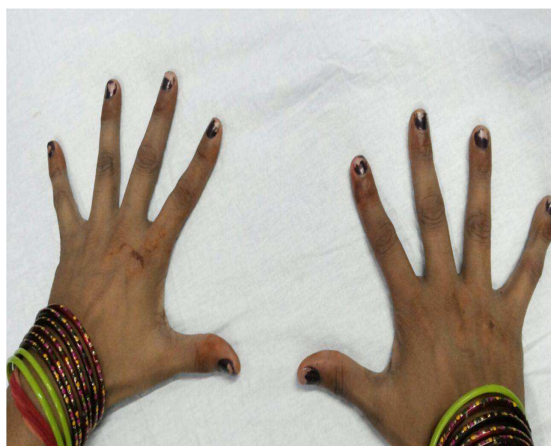

Figure 3: Long slender fingers

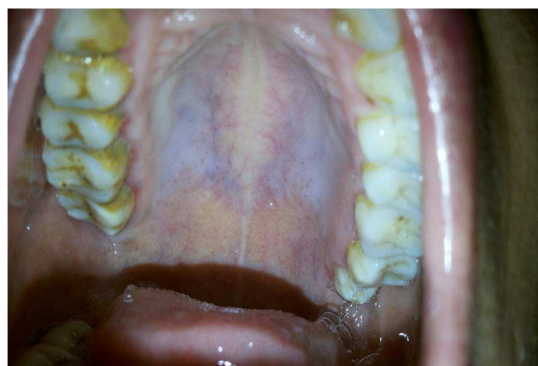


Figure 4: High arched palate

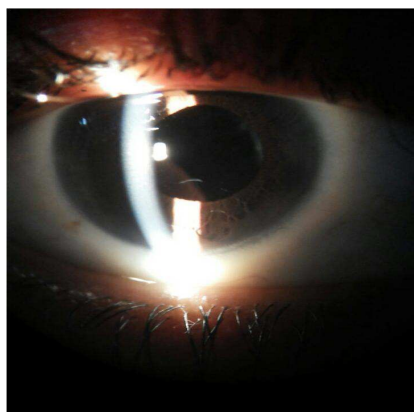


Figure 5: Rt eye- 27.97mm
Axial length >23.5mm
Subluxated inferotemporally, phacodonesis, cataractus

DISCUSSION

In ophthalmic surgery PBA has been found effective and safer than Retrobulbar anaesthesia.^[4,5] Despite this success there are complications reported of which convulsions is a very serious one.^[1,6]

Our case was unique that there was not one but two challenges for the anaesthesiologists. First local anaesthetic toxicity followed by development of tension pneumothorax intraoperatively due PPV. Convulsions can be due to hypoglycaemia, medicine errors, electrolyte imbalance, CNS intoxication by spread of local anaesthetic by inadvertent intra-arterial injection in ophthalmic art or inadvertent brain stem anaesthesia. Our patient had no hypoglycaemia, no medicine error or metabolic derangement and negative aspiration with delayed onset favours brain stem anaesthesia due to PBA.^[7-9] Whatever the mechanism was involved in the complication, prevention is necessary to avoid occurrence and prompt treatment is only possible with presence of Anaesthesiologist in the Operation theatre.

The second problem was development of tension pneumothorax and hemodynamic collapse after IPPV, which was initially thought due to local anaesthetic toxicity. Patients of Marfan syndrome are at risk of development of spontaneous pneumothorax.^[3] Monitors like capnography and ventilator parameter like PIP are important during intraoperative detection of tension pneumothorax in patient under GA.^[11] Prompt management of tension pneumothorax by chest tube insertion is the best way of managing it during PPV.^[12,13] The lesson learnt was presence of Anaesthesiologist always remain required during the locoregional anaesthesia for management of complications and type of monitoring during local anaesthesia should be similar to that of general anaesthesia and respect of standards in anaesthesia safety in ophthalmic surgery is mandatory.^[10]

CONCLUSION

Though locoregional anaesthesia is a simple minor procedure. It is always mandatory to have anaesthesiologist in the OT with strict adherence to safety standards in anaesthesia.

REFERENCES

1. Davis DB, Mandel MR. Peribulbar anesthesia. A review of technique and complications. *Ophthalmol Clin North Am.* 1990;3:101-110.
2. Eichhorn JH, Cooper JB, Cullen DJ, Maier WR, Philip JH, Seeman RG. Standards of patient monitoring during anesthesia at Harvard Medical School. *J Am Med Assoc.* 1986;256:1017-20.
3. Hall JR, Pyeritz RE, Dudgeon DL, Haller JR Jr. pneumothorax in marfan syndrome: prevalence and therapy. *An Thorac Surg.* 1984;37:500-4.
4. Weiss JL, Deichman CB. A comparison of retrobulbar and periorbital anesthesia for cataract surgery. *Arch Ophthalmol.* 1989;107:96-98.
5. Alhassan MB, Kyari F, Ejere HO. Peribulbar versus Retrobulbar anaesthesia for cataract surgery. *Cochrane Database Syst Rev.* 2008;16(3):CD004083.
6. Aqil M. Local anesthesia for the ophthalmic surgery. Select the best technique for your patient. *Saudi Med J.* 2010;31:605-614.
7. Boret H, Petit D, Ledantec P, Bénéfice S. Brainstem anesthesia after peribulbar anesthesia. *Ann Fr Anesth Reanim.* 2002; 21:725-727.
8. Rozentsveig V, Yagev R, Weckler N, Gurman G, Lifshitz T. Respiratory arrest and convulsions after peribulbar anesthesia. *J Cataract Refract Surg.* 2001;27:960-962.
9. Gomez R, Andrade L, Rezende Costa JR: Brainstem anaesthesia after peribulbar anesthesia. *Can J Anaesth* 1997;44:732-734.
10. Webb RK, Currie M, Morgan CA, Williamson JA, Mackay P, Russell WJ, Runciman WB. The Australian Incident Monitoring Study: an analysis of 2000 incident reports. *Anaesth Int Care.* 1993;21:520-28.
11. Tinker JH, Dull DL, Caplan RA. Role of monitoring devices in prevention of anesthetic mishaps. A closed claims analysis. *Anesthesiology.* 1989;71:541-546.
12. MacDuff A, Arnold A, Harvey J. Management of spontaneous pneumothorax: British Thoracic Society pleural disease guideline 2010. *Thorax* 2010; 65:18-31.
13. Kirsch TD, Mulligan JP. Tube thoracostomy. In: Roberts JR, Hedges JR, editors. *Clinical Procedures in Emergency Medicine.* 4th ed. Saunders; 2004. 189.

How to cite this article: Ali S, Athar M Badar A, Ahmed SM. Double Trouble: A Case of Local Anaesthetic Toxicity Followed By Tension Pneumothorax in a Patient of Marfan Syndrome. *Ann. Int. Med. Den. Res.* 2016;2(1):49-51.

Source of Support: Nil, **Conflict of Interest:** None declared