

Pattern of Acute Intestinal Obstruction and Outcome of Management in SRHF, Mizoram, India.

John Lalliangina¹, Vanlalhlua Chawngthu²

¹Assistant Professor, Department of Surgery, SRHF/MIMER, Mizoram, India.

²Assistant Professor, Department of Surgery, SRHF/MIMER, Mizoram, India.

Received: August 2018

Accepted: August 2018

Copyright: © the author(s), publisher. It is an open-access article distributed under the terms of the Creative Commons Attribution Non-Commercial License, which permits unrestricted non-commercial use, distribution, and reproduction in any medium, provided the original work is properly cited.

ABSTRACT

Background: The purpose of this study was to evaluate the aetiological pattern of acute intestinal obstruction, symptomatology, physical findings and outcome of management in State Referral Hospital, Falkawn (SRHF)/Mizoram Institute of Medical Education and Research (MIMER), Mizoram, India. **Methods:** The study was carried out on fifty (50) consecutive cases of acute intestinal obstruction admitted in the Department of Surgery, SRHF/MIMER, Mizoram, India, during a period of 1st January 2015 to 31st December 2017. **Results:** In this series, seven aetiologies were identified namely, adhesions & bands (28%), cancer (26%), hernia (22%), intussusception (8%), volvulus (6%), tuberculosis (6%) and Meckel's diverticulitis (4%) which are discussed in detail. All the patients complained of pain abdomen and 66% of them experienced nausea whereas 60% had vomiting. Distension of abdomen was complained by 80% while absolute constipation was complained by 82%. Per abdominal examination revealed distension in 92%, guarding in 38%, localized tenderness in 20% and palpable mass in 32%. Out of 50 cases, complications were encountered in 7 cases which constitute 14%. The mortality in this study was 4 (8%). **Conclusion:** The pattern of acute intestinal obstruction studied in order of frequency of occurrence is band/adhesion, cancer, hernia, intussusception, volvulus, tuberculosis and Meckel's diverticulitis. The outcome of management was evaluated by analyzing the post-operative complications and mortality. The present study showed that, differentiation between simple and strangulation obstruction on clinical ground and investigative parameters was not possible with certainty.

Keywords: Intestinal obstruction, band/adhesion, cancer, hernia, intussusception.

INTRODUCTION

Intestinal obstruction has been recognized as a disease entity for thousands of years. It is a fairly common surgical problem. The patient with acute abdominal pain represents one of the most common, most important and most difficult practical problems that the general surgeon has to face. Intestinal obstruction is responsible for approximately 20% of surgical admissions for acute abdominal conditions. It is also one of the commonest indications for emergency surgical intervention. Its early recognition and aggressive treatment in patients of all ages including neonates can prevent irreversible ischemia and transmural necrosis, thereby decreasing mortality and long-term morbidity.^[1] Intestinal obstruction is caused by an occlusion to the lumen or a lack of normal propulsion that prevents or delays the intestinal contents from passing along the gastrointestinal tract.^[2] Bowel obstruction can involve Dynamic type where

peristalsis is working against a mechanical obstruction, and Adynamic type where peristalsis may be absent or it may be present in a non-propulsive form. The diagnosis of dynamic obstruction is based on the classic quartet of pain, distension, vomiting and absolute constipation. It may be classified into small bowel (high or low) obstruction, and large bowel obstruction. Mechanical obstruction of intestines can also have the following nature of presentation, namely acute, chronic, acute on chronic, and subacute. Acute intestinal obstruction usually occurs in small bowel with sudden onset of severe colicky central abdominal pain, distension, and early vomiting and constipation. Other manifestations include dehydration, hypokalaemia, pyrexia and localized tenderness.^[3] Treatment of acute intestinal obstruction includes gastrointestinal drainage, fluid and electrolyte replacement and relief of obstruction. The first two steps are always necessary prior to the surgical relief of obstruction and are the mainstay of postoperative treatment. Surgical treatment is necessary for most cases of intestinal obstruction, but should be delayed until resuscitation is complete, provided there is no sign of strangulation and/or evidence of closed-loop obstruction. There are wide variations in the frequency and etiology of bowel

Name & Address of Corresponding Author

Dr. Vanlalhlua Chawngthu
Assistant Professor, Department of Surgery,
SRHF/MIMER,
Mizoram,
India.

obstruction throughout the world depending on ethnicity, age group, dietary habits, and geographic location; among other factors. Reports from different parts of the world indicate that a variety of local factors determines the local pattern of intestinal obstruction. Tropical series differ not only from the established pattern in temperate countries but also amongst themselves.^[4] In western society, a continuous increase in the number of major abdominal operations together with earlier detection and elective treatment of groin hernias and intra-abdominal malignant disease has resulted in a considerable alteration in the spectrum of intestinal obstruction encountered over the past 70 years.^[5] Non-availability of recent study in this subject in SRHF, and a wide variety of conditions that may lead to acute intestinal obstruction, and the multitude of its symptoms and signs has prompted us to undertake the proposed study.

MATERIALS AND METHODS

Materials

This research work was carried out on fifty (50) consecutive cases of acute intestinal obstruction admitted in the Department of Surgery, State Referral Hospital, Falkawn, Mizoram, India, during a period of 2 years from 1st January 2015 to 31st December 2017. Exclusion from the study was subacute intestinal obstruction, chronic intestinal obstruction and adynamic obstruction.

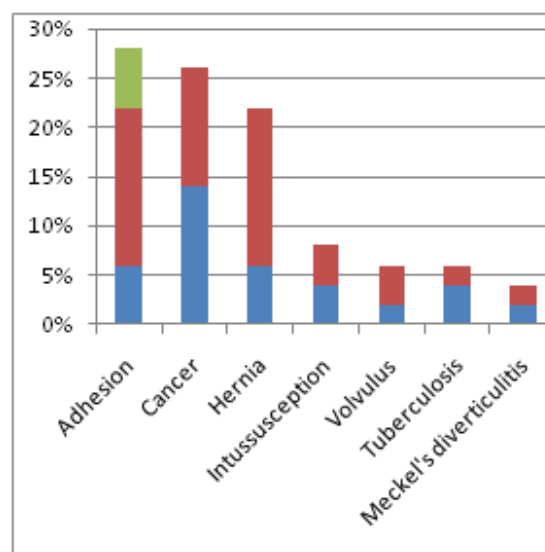
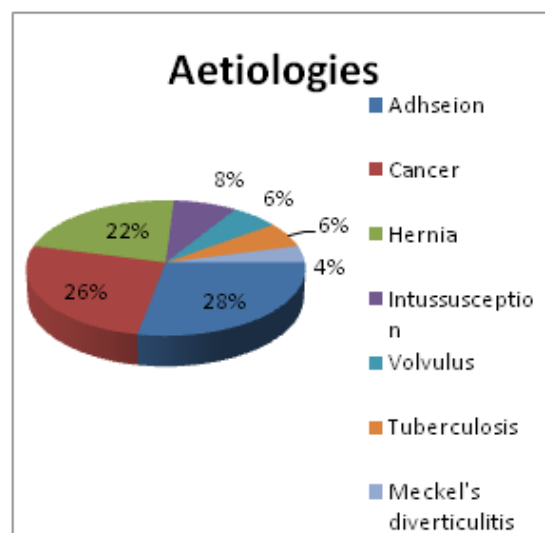
Methods

Before taking up the study, approval for carrying out the research work was obtained from the Institute Ethical Committee (IEC) of SRHF. Informed Consent was taken for each study. A standard proforma of informed consent issued by IEC is enclosed in the annexure of this thesis. Detailed history and thorough physical examination was the basis of clinical diagnosis. Complete haemogram, urinalysis, and estimation of blood sugar level, serum urea, serum creatinine, serum electrolytes, liver function test, radiological investigations, namely Chest X-Ray and Plain X-Ray Abdomen were included in routine investigations. Ultrasonography, CT scan and MRI were carried out when indicated. Confirmation of clinical diagnosis was made only at exploratory laparotomy. Operative findings of all cases were recorded in detail for correlation with the cause of obstruction. After noting the cause of obstruction for each case, the pattern of intestinal obstruction was analyzed with regard to age, sex, race, religion, and socio-economic status. Clinical features of acute intestinal obstruction including symptomatology was analyzed and correlated with the causative factors. A proforma is prepared to suit the study and all the relevant findings were entered.

RESULTS

Table 1:

Sl. No.	Cause of obstruction	No. of cases	%
1.	Adhesion	14	28 %
2.	Cancer	13	26 %
3.	Hernia	11	22 %
4.	Intussusception	4	8 %
5.	Volvulus	3	6 %
6.	Tuberculosis	3	6 %
7.	Meckel's diverticulitis	2	4 %
	Total	50	



This study was conducted on 50 consecutive patients of acute intestinal obstruction admitted in the department of surgery in State Referral Hospital, Falkawn, Mizoram, India. Those patients having subacute, chronic, adynamic intestinal obstruction and those on conservative treatment were excluded from the study. After taking informed written consent and detailed history, a thorough physical examination was done. Necessary investigations were sent and correlated with history and physical findings for making preoperative diagnosis. After

operation, the provisional diagnoses were correlated with operative findings. From the results thus obtained, the pattern of acute intestinal obstruction was constructed.

The aetiological pattern

In this series, seven aetiological causes were identified namely, adhesions & bands (14 cases), cancer (13), hernia (11), intussusception (4), volvulus (3), tuberculosis (3) and Meckel's diverticulitis (2). The first three (adhesion, cancer and hernia) constitute 76% of all the 50 case as shown in [Table 1]

Symptomatology

In this study, all the patients complained of pain abdomen and 66% of them experienced nausea whereas 60% had vomiting. Distension of abdomen was complained by 80% while absolute constipation was complained by 82%. Inguino-scrotal swelling and lump in the abdomen was complained by 26%, Fever was associated in 28% of the patients as shown in [Table 2].

Table 2:

Sl. No.	Symptoms	No. pt	Percentage
1.	Pain abdomen	50	100%
2.	Nausea	33	66%
3.	Vomiting	30	60%
4.	Distension	40	80%
5.	Absolute constipation	41	82%
6.	Lump	13	26%
7.	Fever	14	28%

Physical Findings

On examination fever was found in 14%, tachycardia in 26%, hypotension in 18% and visible peristalsis in 42%. Per abdominal examination revealed distension in 92%, guarding in 38%, localized tenderness in 20% and palpable mass in 32% as shown in [Table 3].

Table 3:

Sl. No.	Signs	No. patients	%
1.	Fever	7	14%
2.	Tachycardia	13	26%
3.	Hypotension	9	18%
4.	Visible peristalsis	21	42%
5.	Abdominal distension	46	92%
6.	Guarding	19	38%
7.	Localized tenderness	10	20%
8.	Palpable mass	16	32%

DISCUSSION

Intestinal obstruction is one of the most common problems which surgeons encountered. Patients present with a variety of complaints; the difficulty often lies in making the correct diagnosis. Untreated complete bowel obstruction can lead not only to the need for bowel resection but to significant associated morbidity and mortality as well. The challenge lies in making the correct diagnosis and implementing an appropriate treatment strategy.^[6]

Pathophysiology

Obstruction relates to a mechanical blockage which precludes intestinal contents from moving in the usual oral to anal progression. This may be due to torsion at the point of an adhesion, incarceration in a hernia sac, intraluminal masses, or extrinsic compression. Obstruction can be complete, meaning nothing can pass beyond the point of obstruction, or partial, meaning that transit occurs through a significantly narrowed lumen. Strangulation implies compromised blood flow to the involved segment with impending necrosis. Intestinal contents back up from the point of obstruction creating dilatation of small bowel proximal to the site of mechanical obstruction. The resulting intraluminal distention can lead to venous engorgement, ischemia, and eventual intestinal wall necrosis. Additionally, the large bowel is deprived of its usual absorption of fluid, since the enteric contents are prevented from reaching the colon. These two factors set up a cycle of fluid shifts from the intravascular space to the lumen and interstitium of the small intestine. Haemoconcentration ensues, followed by electrolyte abnormalities, worsening intestinal necrosis, and eventual haemodynamic collapse. Complete obstruction requires operative intervention to relieve the mechanical blockage and to prevent strangulation. Partial obstruction, however, may respond to non-operative management. Thus the goal of evaluation is to determine which patients will require operation and which can be safely managed non-operatively.^[7]

Aetiological Pattern

In this series, seven aetiologies were identified namely, adhesions & bands (28%), cancer (26%), hernia (22%), intussusception (8%), volvulus (6%), tuberculosis (6%) and Meckel's diverticulitis (4%) which are discussed in detail below.

1. Adhesion

The most common cause of acute intestinal obstruction in this series is adhesions and bands which is similar with that of the west as per McEntee G et al,^[8] and some of the affluent countries of the east according to the study done by Rehman AU et al.^[9] Out of the 50 patients in this series, 28% were having adhesive obstruction which was confined to small bowel only. Of these, 57% were due to previous operations such as Gynecological procedures, operations on the appendix and colon which is in consistency with most of literatures on postoperative adhesions including (more ref) the study made by Shih SC et al.^[10] Intra-abdominal adhesions are the most common cause of SBO in industrialized countries, accounting for approximately 65% to 75% of cases as per the study on "Adhesive small bowel obstruction: epidemiology, biology and prevention" done by Attard JAP et al.^[11] Comparing the incidence of adhesion with the western series, our finding is still relatively low.

2. Cancer

The second most common etiology in this series is cancer which constitutes 26%. Although the percentage is much higher than the western series (15-20%), it follows a similar pattern by coming after adhesion obstruction. In our series more than 84% of all cancer cases belong to colorectal carcinoma which is in agreement with the finding of Adhikari S et al.^[12] The remaining cases were metastatic disease from intra-abdominal malignancy such as ovarian cancer (4%) which is in agreement with Ketcham AC et al,^[13] and causing extrinsic obstruction to the small intestine.

3. Hernia

The third most common cause of acute intestinal obstruction in this study is obstruction of external hernia which is 22%. This finding is in agreement with Stewardson RH et al,^[14] in their study on Critical Operative Management of Small Bowel Obstruction. All the cases belong to groin hernia, and more than 81% were incarcerated inguinal hernia, the remaining being femoral hernia.

4. Intussusception

Intussusception is defined as the invagination of one portion of the bowel into an immediately adjacent portion. It is the fourth leading cause of intestinal obstruction in this series (8%). It is in agreement with the study done by Ti TK et al,^[15] in their study on the pattern of intestinal obstruction in Malaysia. Out of 4 cases three of them are ileo-colic, the remaining being ileo-ileal. Half of the intussusception cases were adults, comprising 4.44% of all adult patients with acute intestinal obstruction which is in agreement with Joseph T et al.^[16] Intussusception is uncommon in adults compared with the pediatric population. Aetiology, symptoms, diagnosis, and treatment are different in the pediatric and adult populations. In the pediatric population, most cases are idiopathic and result in the common scenario of ileo-colic intussusception.^[17]

5. Volvulus

The fifth etiology is primary volvulus (3 cases) which accounts for 6% which is in agreement with Adhikari S et al,^[18] in their study on the etiology and outcome of acute intestinal obstruction: a review of 367 patients in eastern India. Two cases belong to the small bowel (5.26% of all small bowel obstruction) which is in agreement with Iwuagwu O et al,^[19] in their study on Small bowel volvulus: a review. The third volvulus occurs in large bowel (caecum).

6. Tuberculosis

Tuberculosis is the 6th cause of acute intestinal obstruction (6%) in the present study. This result is in close proximity to a study done 30 years ago in Bankura, West Bengal.^[20] The first case was an

Injecting Drug user with known hepatitis infection. There was a stricture obstruction in the terminal ileum with extensive inter-loop bowel adhesion. Ileo-transverse bypass was done. He developed postoperative mechanical bowel obstruction and expired after 40 days of hospital stay. The second case underwent resection & anastomosis and sticturoplasty. For the third case, resection could not be done for which ileo-transverse bypass surgery was done

7. Meckel's diverticulitis

In the present study, acute intestinal obstruction due to Meckel's diverticulitis accounts for 4% of all the causes. Most of the literatures do not have this much percentage for the same. According to Sharma RK et al,^[21] Meckel's diverticulum is the most common congenital anomaly of the gastrointestinal tract (2% of the general population) but the life time risk of developing complications in this vestigial organ is 4 – 6%. According to Wong BS et al,^[22] the Pathophysiology is analogous to that of acute appendicitis, with inflammation being secondary to stasis and bacterial infection, which occurs due to the obstruction of the lumen by enteroliths or foreign body or by parasites (*Ascaris lumbricoides* or *Taenia saginata*).

Evaluation of outcome of management

1. Complications

Out of 50 cases, complications were encountered in 7 cases which constitute 14%. None had more than single complication. Most of the series have higher complication rate, the lowest being 21% in the study made by Rehman AU et al.^[23] The low complication rate in this series may be accountable to small sample size and short duration of study. The most common complications were 2 cases each of surgical site infection and ascites. Wound infection was found in 1 case each of Ca splenic flexure of the colon for which colostomy was done and the second case of Meckel's diverticulitis for which wedge resection and primary repair was done. Ascites developed in 2 cases of ovarian tumours. Surgical site infection and ascites constitute 57.14% of all complications. This is followed by 1 case (14.2%) each of wound dehiscence in case of adhesion due to appendicular perforation, basal atelectasis in case of adhesion due to suspected DU perforation and electrolyte imbalance (hyponatraemia) in the first case of Meckel's diverticulitis.

2. Mortality

The mortality in this study was 4 (8%). This is in agreement with that of Adhikari S et al.^[24] Other literatures have different mortality rates ranging from 1.3% in the series of Markogiannakis H et al,^[25] 5 to 28% in Pal JC et al,^[26] series. The first case was a known case of Ca rectum with colostomy in situ. Abdomino-Perineal Resection had been done

and while he was on chemotherapy adhesive obstruction of small intestine occurred. Adhesiolysis and ileostomy was done. He expired after 18 days due to distant metastases. The second case was tubercular stricture obstruction with hepatitis infection. He was a known case of injecting drug user. On exploration he was found to have abdominal cocoon. Ileo-transverse bypass was done. He developed early postoperative mechanical bowel obstruction and expired on the 40th postoperative day. The third case was annular growth in the sigmoid colon. Segmental resection and end-to-end anastomosis was done. His general condition deteriorated and expired due to acute renal failure after 2 weeks. The last death case was a female who had a malignant growth in the hepatic flexure. Ileo-transverse bypass was done he she expired due to septic shock after 1 week. There was no intra-operative and immediate postoperative death.

CONCLUSION

This study was carried out on fifty consecutive cases of acute intestinal obstruction admitted and operated upon in the department of general surgery from 1st January 2015 to 31st December 2017. It included all age-groups ranging from newborn to elderly patients. Analysis was made on the history, clinical presentation, laboratory and imaging reports and operative findings. The pattern of acute intestinal obstruction studied in order of frequency of occurrence is band/adhesion, cancer, hernia, intussusception, volvulus, tuberculosis and Meckel's diverticulitis. The symptoms and physical findings were studied and correlated with the cause of obstruction. Then, correlation between the clinical and operative findings was made. The clinical features, laboratory and radiological findings were studied in assessing the nature of obstruction. These findings correlated with the operative findings. The outcome of management was evaluated by analyzing the post-operative complications and mortality. The present study showed that, differentiation between simple and strangulation obstruction on clinical ground and investigative parameters was not possible with certainty.

REFERENCES

- Maglinte DT, Balthazar EJ, Kelvin FM, Megibow AJ. The role of radiology in the diagnosis of small bowel obstruction. *AJR* 1997 May; 168.
- Yeboah MO, Adippah E, Gyasi-sarpong K. Acute intestinal obstruction in adults in Kumasi, Ghana. *Ghana Med J* 2006 June; 40: 2.
- Winslet MC. Intestinal obstruction. In: Williams NS, Bulstrode CJK, O'Connell PR, editors. *Bailey & Love's short practice of surgery*. 25th ed. London: Edward Arnold; 2008. p. 1188-203.
- McAdam IWJ. A three year review of intestinal obstruction, Mulago Hospital, Kampala, Uganda. *East Afr Med J* 1961; 38: 536-43.
- McEntee G, Pender D, Mulvin D, McCullough M, Naeeder S, Farah S, et al. Current spectrum of intestinal obstruction. *Br J Surg* 1987; 74:976-80.
- Soybel DI. Acute abdominal pain. In: Souba WW, Fink MP, Kaiser LR, Jurkovich GJ, Pearce WH, Soper NJ, editors. *ACS Surgery: Principles & Practice*. 6th ed. Chicago: WebMD Inc; 2007.
- Markogiannakis H, Messaris E, Dardamanis D, Pararas N, Tzertzemelis D, Giannopoulos P, et al. Acute mechanical bowel obstruction: Clinical presentation, aetiology, management and outcome. *World J Gastroenterol* 2007 January 21; 13(3): 432-7.
- McEntee G, Pender D, Mulvin D, McCullough M, Naeeder S, Farah S, et al. Current spectrum of intestinal obstruction. *Br J Surg* 1987; 74:976-80.
- Rehman AU, Khan M, Aman Z, Haq MZU, Ahmad S, Ahmad S. Pattern of small bowel obstruction in adults. *J Med Sci* 2010 April-June; 18 (2): 77-8.
- Shih SC, Jeng KS, Lin SC, Kao CR, Chou SY, Wang HY, et al. Adhesive small bowel obstruction: How long can patients tolerate conservative treatment? *World J Gastroenterol* 2003; 9(3):603-5.
- Attard JAP, MacLean AR. Adhesive small bowel obstruction: epidemiology, biology and prevention. *Can J Surg* 2007 August; 50:4.
- Adhikari S, Hossein MZ, Das A, Mitra N, Ray U. Aetiology and outcome of acute intestinal obstruction: a review of 367 patients in eastern India. *The Saudi J of Gastroenterol* 2010; 16(4): 285-7.
- Ketcham AC, Hoyer RC, Pilch YH, Morton DL. Delayed intestinal obstruction following treatment for cancer. *Cancer* 1970 February; 25:406-10.
- Stewardson RH, Bombeck CT, Nyhus LM. Critical operative management of small bowel obstruction. *Ann Surg* 1978 February; 189-94.
- Ti TK, Yong NK. The pattern of intestinal obstruction in Malaysia. *Br J Surg* 1976; 63:963-5.
- Joseph T, Desai AL. Retrograde intussusception of sigmoid colon. *J R Soc Med* 2004; 97:127-8.
- Chang YT, Huang YS, Chan HM, Huang CJ, Hsieh JS, Huang TJ. Intestinal obstruction during pregnancy. *Kaohsiung J Med Sci* 2006; 22(1):20-3.
- Adhikari S, Hossein MZ, Das A, Mitra N, Ray U. Aetiology and outcome of acute intestinal obstruction: a review of 367 patients in eastern India. *The Saudi J of Gastroenterol* 2010; 16(4): 285-7.
- Iwuagwu O, Deans GT. Small bowel volvulus: a review. *R Coll Surg Edinb* 1999 June; 44:150-5.
- Pal JC, De SR, Das D. The pattern of acute intestinal obstruction in a peripheral district of eastern India. *Int Surg* 1982; 67:41-3.
- Sharma RK, Jain VK. Emergency surgery for Meckel's diverticulum. *WJES* 2008; 3:27.
- Wong BS, Larson DW, Smyrk TC, Oxentenko AS. Perforated Meckel's diverticulum presenting with combined bowel and urinary obstruction and mimicking Crohn's disease: a case report. *Journal of Medical Case Reports* 2010; 4:264.
- Rehman AU, Khan M, Aman Z, Haq MZU, Ahmad S, Ahmad S. Pattern of small bowel obstruction in adults. *J Med Sci* 2010 April-June; 18 (2): 77-8.
- Adhikari S, Hossein MZ, Das A, Mitra N, Ray U. Aetiology and outcome of acute intestinal obstruction: a review of 367 patients in eastern India. *The Saudi J of Gastroenterol* 2010; 16(4): 285-7.
- Markogiannakis H, Messaris E, Dardamanis D, Pararas N, Tzertzemelis D, Giannopoulos P, et al. Acute mechanical bowel obstruction: Clinical presentation, aetiology, management and outcome. *World J Gastroenterol* 2007 January 21; 13(3): 432-7.

26. Pal JC, De SR, Das D. The pattern of acute intestinal obstruction in a peripheral district of eastern India. *Int Surg* 1982; 67:41-3.

How to cite this article: Lalliandinga J, Chawngthu V. Pattern of Acute Intestinal Obstruction and Outcome of Management in SRHF, Mizoram, India. *Ann. Int. Med. Den. Res.* 2018; 4(5):SG30-SG35.

Source of Support: Nil, **Conflict of Interest:** None declared