

# A Study of Transobturator Tape in Stress Urinary Incontinence.

G. Latha<sup>1</sup>

<sup>1</sup>Senior Resident in Department of Urology, Government Pudukottai Medical College, Tamilnadu, India.

Received: April 2018

Accepted: April 2018

**Copyright:** © the author(s), publisher. It is an open-access article distributed under the terms of the Creative Commons Attribution Non-Commercial License, which permits unrestricted non-commercial use, distribution, and reproduction in any medium, provided the original work is properly cited.

## ABSTRACT

**Background:** Stress urinary incontinence is the most common type of urinary incontinence in women. Stress incontinence is often seen in women who have had more than one pregnancy and vaginal delivery. **Aim:** To study the efficacy of Trans-obturator tape in SUI. **Methods:** It is the prospective study. 60 female patients included in this study after Trans-obturator tape surgery. The period of study from 3- 20 months after surgery. **Results:** Symptom improvement seen in all cases after surgery. We assess the outcome by doing cough stress test and subjective questioning. **Conclusion:** Transobturator tape is a simple, effective and safe procedure for the treatment of female stress urinary incontinence confirmed after more than 1 year of follow-up. It offers increased safety. The post-operative morbidities associated with this technique are minimal and manageable. Evaluation of the results after a longer follow-up period is needed. The learning curve is simple and easy.

**Keywords:** Stress urinary incontinence, Transobturator tape, cystoscope, cough stress test.

## INTRODUCTION

Stress urinary incontinence (SUI) has a significant impact on the quality of life for many women, although estimates of prevalence vary widely due to inconsistencies in the definitions of SUI and differences in populations studied.<sup>[1]</sup> The estimated prevalence of urinary incontinence is nearly 30% in women aged 30–60 years, with approximately half of the cases attributed to SUI.<sup>[2,3]</sup> The treatment for this problem includes initial conservative therapies (i.e., lifestyle interventions, pelvic floor muscle training, and bladder training), followed by surgery, which is an option for women whose quality of life is still impaired after a diagnosis of genuine stress incontinence has been confirmed. In 1998, Nickel et al. from Holland reported a successful sling procedure using a polyester ribbon passed through the obturator foramen and around the urethra for treatment of refractory urethral sphincter incompetence in female dogs.<sup>[4]</sup> In France in 2001, Delorme introduced the trans-obturator sling procedure in humans.<sup>[5]</sup> Thousands of procedures have been performed in Europe and more recently in the United States, and lately, this newer, seemingly safer approach to the tension-free tape sling procedure is picking up in India.

## Aim

To study the efficacy of Transobturator tape in SUI.

## MATERIALS AND METHODS

This was a prospective experimental study to see the outcome measures in patients of SUI treated with the trans-obturator sling. The study population comprised Indian patients attending the urology OPD at a tertiary care teaching hospital at Government Medical College Hospital, Pudukottai, and the patients were recruited from July 2016 to February 2018. It was an experimental design to see the efficacy of TOT in SUI and study intra-operative parameters, intra and postoperative complications, and patient satisfaction. In this study, there were no controls, and no comparisons were made. All patients attending urology OPD at a tertiary care teaching hospital, who complained of de novo involuntary passage of urine on coughing, laughing, straining, or any other action suggestive of the increase in intra-abdominal pressure, were subject to a thorough history taking and physical examination. Patients with the history suggestive of urge incontinence were excluded and were treated for the same. Also, the patients who had a co-existing pelvic organ prolapse or any other gynecological problem which required treatment and was planned to be corrected in the same surgical sitting were excluded. Furthermore, patients who had previously undergone corrective surgery for stress incontinence were also excluded. Patients who were pregnant were excluded. Only non-pregnant patients with a history suggestive of genuine stress incontinence, who had

### Name & Address of Corresponding Author

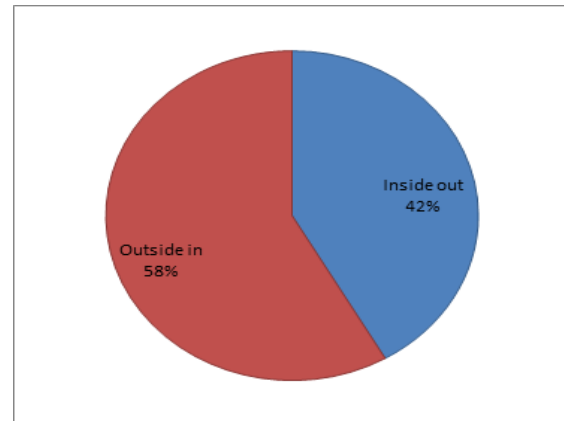
Dr. G.Latha,  
Senior resident in Urology,  
Department of Urology,  
Government medical college,  
Pudukottai.

never undergone any previous corrective surgery for the same, and for whom no other gynecological surgery was planned in the same sitting were included in this study and considered for final recruitment. All the patients diagnosed with SUI and a positive Bonney's test were explained about their disease, and the available modes of treatment including non-surgical and surgical options were discussed. Patients who were willing for an operative procedure, either initially or after failure in relief of symptoms after a trial of pelvic floor muscle training and were desirous of a TOT placement were the patients who were finally recruited for this study. After they were declared fit for anesthesia, surgery was planned on a mutually convenient date, and the patient was admitted the night before. Informed consent was taken. The part preparation was done in the morning before sending to Operation Theater. After that, on the day of surgery, a transobturator sling was applied using a TOT by outside-in technique. The time taken for the surgical procedure was recorded and noted for every patient. The blood loss at the time of surgery was assessed by using pre-weighed swabs and estimating their difference in weight before and after surgery. Also, the quantity of blood drained by negative suction, if any, was estimated by noting its volume in the suction drainage chamber. The period of their hospital stay was noted and recorded. All patients were given extensive advice at the time of discharge which specifically stressed to avoid squatting and intercourse for 4 weeks. They were told to use chair-style toilet seat only and not to squat while micturition or while defecating. They were also stressed upon the requirement of adequate fluid intake to prevent urinary infections and also avoid constipation. At the follow-up visits, they were specifically asked about the relief of symptoms for which they underwent surgery, any chronic pain, and their overall satisfaction with the surgical outcome. Statistics study all the data were recorded and in the end, was analyzed, and outcomes were derived. All these accumulated data were statistically analyzed. TOT is an established and safe procedure for treatment of SUI. This was an observational study, and there were no controls kept.

### RESULTS

60 cases were evaluated for 3-20 months after surgery-TOT. The age group included in this study from 30 to 60 years. The mean age of the patients operated for SUI under this study was 45 years. Out of the total 60 patients, 39 were premenopausal and 21 were postmenopausal. Out of total 60 transobturator slings applied, 3 were in primiparous women and 57 were in multiparous women. The patients examined in detail with stress leak present in all cases. 30% of patients having combined SUI & UI. Urge incontinence alone

present patient excluded from the study. USG ABD KUB with post void residual urine done in all patients. Urine c/s, Urodynamic study in all the cases. The surgery planned for all SUI patients was Transobturator Tape. Post-operative period uneventful all the cases. Patients were discharged after 5-7 days after improvement. Post-operative complications expected in these cases are bladder injury, vaginal erosion, voiding dysfunction, thigh abscess, and intra obturator hematoma. Two patients developed irritative symptoms and one patient developed obstructive symptoms.



Cough stress test and subjective questioning was followed as assessment of outcome after stress urinary incontinence surgery. The patients were followed up from 3- 20 months, showed cure in 95% of patients.

**Table 1: Follow up and Outcome**

Method	No. of patients	Follow up	Outcome		
			Cure	Improved	Failed
Inside out TOT	25	3 to 20 months	100%	0%	0%
Outside in TOT	35	3 to 20 months	95%	5%	0%

### DISCUSSION

In transobturator tape (TOT) placement, through small incisions placed in the groins and in the vagina under the urethra, the mesh can be placed under the urethra in the correct position without having to pass needles blindly through the retropubic space, as in transvaginal tape (TVT). The space that the needle passes through has been extensively studied and has been found to be a very safe space to work in. The mean operative time is significantly shorter in the transobturator sling and risk of bladder injury and of postoperative urinary retention is also considerably lower than other sling procedures.<sup>[6]</sup> The TOT is a tension-free sling as the resting urethral angle is not changed by the procedure, nor is it necessary to correct urethral hypermobility.<sup>[7]</sup> One of the most important and not well-recognized advantages of the

TOT as compared with other mid-urethral sling procedures is the lower rate of de novo urge/urge incontinence.<sup>[8]</sup> As far as sexual activity is concerned, there is no significant change in patients' sexual life as regards frequency of intercourse and pleasure and/or pain during penetration, whereas there is a significant decrease in coital incontinence.<sup>[9]</sup> TOT application was successful in 95% cases in this study and it improved in 5% cases. Delorme in 2003 reported on 40 patients in whom TOT was applied for the first time, 39 patients had no incontinence postsurgery and 1 patient had improvement in symptoms.<sup>[5]</sup> DeTayrac in 2004 reported a 1-year cure rate of 84% with the TOT procedure.<sup>[6]</sup> In a series of 117 patients with a median follow-up of 16.3 months, Spinosa in 2005 reported subjective complete and partial satisfaction rates of 92.3% and 4.2%, respectively.<sup>[10]</sup> In 2007, Latthe et al. quoting their experience in Britain in a series of 135 patients who were applied TOT reported the subjective level of complete cure and improvement reported by patients were 89.6% and 8.8%, respectively.<sup>[11]</sup> Taweel et al. reported a 92% cure or improvement rate after 12 months and 85% after 24 months by an objective assessment and a patient satisfaction rate of 88% at 1 year by subjective assessment. The mean age of the patients operated for SUI under this study was 46.2 years (SD 11.2 years; range 24–70 years). The mean age of patients reported by Taweel in his series was 52 ± 9 years (range 34–70 years).<sup>[12]</sup> Moore et al. in their study had patients with an average age of 56.8 years with an SD of 11.7.<sup>[13]</sup> Isabelle et al. in their analysis of 233 cases had patients with an average age of 57.9 years (SD 13.2 years. Out of 60 patients studied in this study, 27 (45.8%) were discharged within 3 days of surgery and rest of the patients discharged within 5-7 days. Purnichescu et al. from France reported mean duration of hospitalization in the cases of isolated TOT as 1.25 days. Isabelle et al., for women who had only TOT procedure, reported the mean hospitalization as 2.2 days.<sup>[14]</sup> In our series of 60 patients, Cystoscopy was done after the complete procedure to confirm success of repair. In the immediate postoperative period, only one patient (1.7%) had transient urinary retention after removal of urinary catheter, which was relieved by recatheterization and subsequently had successful voiding on the next week. No patient in this study had vascular, neural, or bowel injury. The most important step to avoid erosion and voiding dysfunction was found to be tape adjustment without

any tension or any contact with the urethra. There were no complaints of thigh pain in our series, which confirms findings of a meta-analysis published in BJOG in 2007 by Latthe et al.; that the outside-in technique is usually not associated with this specific symptoms. None of the patients had developed erosion in the period of study till the last follow-up, which is probably due to the use of the tape material made of non-woven polypropylene mono filament with macropores. Obstructive voiding dysfunction is the most commonly reported complication of some other mid urethral sling placements like TVT. Because the TOT is positioned horizontally across the urethra, it provides less chance for static urethral kinking and the associated urethral obstruction that may follow. In this series, no patient developed urethral obstruction requiring complete or even partial tape release. One of the most important and not well recognized advantages of the TOT as compared with other mid-urethral sling procedures is the lower rate of de novo urge/urge incontinence. In the transobturator approach, the path of the tape, crossing the obturator foramen, muscle, and fascia, reproduces the natural suburethral suspension by reinforcing the rotational pivot point, restoring continence while sparing the retropubic space. Sparing the retropubic space may preserve any periurethral nerve fibers that may be associated with urethral function and stability. Second, the TOT is associated with a lower risk of urethral obstruction as compared with other mid-urethral sling procedures. The transobturator sling procedure spares the retropubic space and thus also eliminates the risk of major bowel, neural, and vascular complications which have been reported with the TVT. Another important advantage of TOT is that since it is not possible anatomically to over tighten the tape, there is hardly any reported incidence of urinary retention because of mechanical obstruction, whereas obstructive voiding dysfunction is the most commonly reported complication of some other mid urethral sling placements like TVT. In the present series, no patient developed urethral obstruction. The Agency for Health Care Policy and Researcher's Clinical Practice Guidelines on SUI in Adults advice that "the least invasive and least dangerous procedure that is appropriate for the patient should be the first choice". Transobturator (TOT) tape was a viable method for correction of SUI. In Europe, as of 2005, approximately 83.9% of all procedures are mid urethral-type synthetic slings, of which 26.9% are TOT (de Tayrac and Medelenat, 2004).

**Table 2: Comparison of outcome with other studies**

Study	N	Age	Follow up	Cured	Improved	Failed	Assessment of outcome
Delorme et al,2003	150	50 - 81	17 months	90.6%	9.40%	0	cough stress test.uroflow
de Tayrac et al, 2004	30	54.7	12 months	80.5%	7.50%	12%	cough stress test. questionnaire
mellier et al, 2004	94	58.1+/- 9.3	12.8 months	95%	4%	1%	questionnaire
Our study	60	30 – 63	3 - 20 months	95%	5%	0	cough stress test. questionnaire

## CONCLUSION

Transobturator tape is a simple, effective and safe procedure for the treatment of female stress urinary incontinence confirmed after more than 1 year of follow-up. It offers increased safety. The post-operative morbidities associated with this technique are minimal and manageable. Evaluation of the results after a longer follow-up period is needed. The learning curve is simple and easy. However, the limitations of our study were the period for which the patients were followed, and given the same, any long-term morbidity or long-term satisfaction level of the patients treated could not be recorded and analyzed. Although there have been studies quoted in the literature which have followed up patients for almost up to 2 years after TOT application, it is still felt desirable that larger trials with bigger sample size and with a longer duration of follow-up for evaluating long-term success of TOT are required. Further, comparative trials comparing TOT with other surgical options available for treatment of SUI shall be able to give it its right place of honor in the treatment of SUI. It has all the potential to be the new Gold Standard in the treatment of female SUI.

district general hospital. J Obstet Gynecol. 2007;27:177–80.[PubMed]

**How to cite this article:** Latha G. A Study of Transobturator Tape in Stress Urinary Incontinence. Ann. Int. Med. Den. Res. 2018; 4(3):SG25-SG28.

**Source of Support:** Nil, **Conflict of Interest:** None declared

## REFERENCES

1. Luber KM. The definition, prevalence, and risk factors for stress urinary incontinence. Rev Urol. 2004;6:S3. [PMC free article] [PubMed]
2. Hampel C, Weinhold D, Benken N, Eggersmann C, Thurhoff JW. Definition of overactive bladder and epidemiology of urinary incontinence. Urology. 1997;50:4. [PubMed]
3. Hampel C, Artibani W, Espuña Pons M, Haab F, Jackson S, Romero J, et al. Understanding the burden of stress urinary incontinence in Europe: A qualitative review of the literature. Eur Urol. 2004;46:15. [PubMed]
4. Nickel RF, Wiegand U, Brom WV. Evaluation of a transpelvic sling procedure with and without colposuspension for treatment of female dogs with refractory urethral sphincter mechanism incompetence. Vet Surg. 1998;27:94–104. [PubMed]
5. Delorme E. Transobturator urethral suspension: Mini-invasive procedure in the treatment of stress urinary incontinence in women. Prog Urol. 2001;11:1306–13. [PubMed]
6. DeTayrac R, Deffieux X, Droupy S, Chauveaud-Lambling A, Calvanese-Benamour L, Fernandez H. A prospective randomized trial comparing tension-free vaginal tape and transobturator suburethral tape for surgical treatment of stress urinary incontinence. Am J Obstet Gynecol. 2004;190:602–8.[PubMed]
7. Minaglia S, Ozel B, Hurtado E, Klutke CG, Klutke JJ. Effect of Transobturator tape procedure on proximal urethral mobility. Urology. 2005;65:55–9. [PubMed]
8. Juma S, Brito CG. Transobturator tape: Two years follow-up. Neurourol Urodyn. 2007;26:37.[PubMed]
9. Abdel-Fattah M, Ramsay I, Pringle S, Bjornsson S, Hardwick C, Tierney J, et al. Transobturator suburethral tapes in the management of urinary incontinence: Success, safety and impact on sexual life. Gynecol Surg. 2007;4:267–73.
10. Spinoso JP, Dubuis PY. Suburethral sling inserted by the transobturator route in the treatment of female stress urinary incontinence: Preliminary results in 117 cases. Eur J Obstet Gynecol Reprod Biol. 2005;123:212–7. [PubMed]
11. Latthe PM, Patodi M, Constantine G. Transobturator tape procedure in stress urinary incontinence: UK experience of a