

# Retrograde Facial Nerve Dissection Using Zygomatic Branch as Landmark in Parotid Gland Surgery for Pleomorphic Adenoma: A 4 Year Prospective Study of 40 Cases.

Jayanth Kumar Biswal<sup>1</sup>, Jino Sebastian<sup>2</sup>

<sup>1</sup>Associate Professor, Department of General Surgery S.C.B Medical College, Cuttack, Odisha.

<sup>2</sup>Junior Resident, Department of General Surgery, S.C.B Medical College, Cuttack, Odisha.

Received: April 2018

Accepted: April 2018

**Copyright:** © the author(s), publisher. It is an open-access article distributed under the terms of the Creative Commons Attribution Non-Commercial License, which permits unrestricted non-commercial use, distribution, and reproduction in any medium, provided the original work is properly cited.

## ABSTRACT

**Background:** The retrograde dissection for doing parotidectomy is technically easier and surgeon can limit the dissection to 1 or 2 branches of facial nerve if required and hence avoids injury to the trunk or other branches of facial nerve, aiming at removal of only the parotid parenchymal area that bears the tumour. Objectives: To compare our results with those of similar studies in the recent literature. To compare nerve recovery rates when zygomatic branch is used as landmark with that of other techniques from literature. **Methods:** In this study 40 patients with pleomorphic adenoma of parotid gland underwent superficial parotidectomy at V.S.S Medical College hospital Burla and S.C.B medical college Cuttack in a 4 year period between 2013 and 2016. All 40 patients underwent retrograde superficial parotidectomy. We compared our results with results of similar studies in the recent literature. **Results:** Although all 40 patients experienced paresis immediately after surgery, 25% patients completely recovered and 75% patients had facial nerve weakness at the end of first week. Among this 60% patients were having H.B-2 weakness, 7.5% had H.B-3 weakness, 5% had H.B-4 and 2.5% had H.B-5 weakness. Any injury equal to or more than H.B-3 was considered serious. 15% patients were having serious injury. None of the patients had H.B-6 (severe) facial nerve weakness. **Conclusion:** Transient nerve weakness after retrograde parotidectomy is common but recovery will be faster than that of ante grade technique and within 6 months to 1 year all patients should recover nerve function completely.

**Keywords:** Superficial parotidectomy, Facial nerve injury, Nerve recovery.

## INTRODUCTION

Salivary tumours are most common in the parotid gland, and most of them arise in the superficial lobe. Pleomorphic adenoma is the most common tumour of the parotid gland. As for most of the parotid tumours surgical excision is its treatment of choice. In the early 20th century benign parotid tumours were treated with simple enucleation, but the recurrence rates were significantly high (25%).<sup>[4]</sup> So surgeons started doing superficial parotidectomy by which recurrence rates got reduced. But due to extensive dissection incidence of facial nerve paresis increased and cosmesis was also unacceptable. As even with a temporary paresis of facial nerve, patients struggles a lot and also due to poor cosmesis associated, more conservative methods were thought of. As a result of which extracapsular dissection,

selective deep lobe parotidectomy and retrograde parotidectomy techniques came into practice.<sup>[2,3]</sup>

Retrograde technique (for enucleation) was introduced earlier than the introduction of superficial parotidectomy (by ante grade technique) [Table 1]. After introduction of antegrade superficial parotidectomy, due to its advantage of low recurrence rates retrograde technique lost its popularity. In recent literature studies showing significant reduction in complication rates by retrograde technique when compared with ante grade technique for doing parotidectomy were published, which again attracted attention towards this "older" technique.<sup>[1,5,10,11,15]</sup>

The retrograde dissection is technically easier and surgeon can limit the dissection to 1 or 2 branches of facial nerve if required and hence avoids injury to the trunk or other branches of facial nerve, aiming at removal of only the parotid parenchymal area that bears the tumour. A retrograde approach may conserve normal parotid tissue, result in a more favourable cosmetic outcome and reduce operative time. Aim of this study is to compare incidence of various outcome parameters in retrograde superficial

### Name & Address of Corresponding Author

Dr. Jino Sebastian,  
Earimattathil (House),  
Karoor (P.O), Pala (P.S), Kottayam (Dist),  
Karala (State).

parotidectomy done in our institution with those of studies in literature.

### MATERIALS AND METHODS

In this study 40 patients with pleomorphic adenoma of parotid gland underwent superficial parotidectomy at V.S.S Medical College hospital Burla and S.C.B medical college Cuttack in a 4 year period between 2013 and 2016. All of the 40 patients underwent retrograde superficial parotidectomy. Among them 28 were females (age range 35 to 61 years; mean age 48) and 12 were males (age range 40 to 62 years; mean age 51). Patients were followed up for a mean duration of 24 months. Preoperative diagnosis was made using CT and FNAC in all cases. We excluded those patients who were diagnosed with malignant disease as presence of any neural invasion may necessitate to sacrifice facial nerve. The purpose of this was to study the incidence of injury (temporary/permanent) to facial nerve trunk or to any of the main branches and classify according to House Brackman score [Table 2]. Occurrence of Frey’s syndrome and salivary fistula were also studied through followup. All the surgeries were done by the first author with informed and written consent.

We compared our results with results of similar studies in the recent literature. Search key words included superficial parotidectomy, retrograde technique and pleomorphic adenoma. We excluded studies which included recurrent diseases of the parotid gland, and those that didn’t include retrograde superficial parotidectomies. Nomenclature used for the surgical procedures of parotid gland was highly variable among different

authors. We used classification proposed by Snow which was the easiest [Table 3].<sup>[13]</sup> An excellent classification of the surgical procedures on parotid gland is also done by Forresta et al.<sup>[14]</sup>

### Surgical Technique

We started each of our surgeries by putting a modified Blair incision. Fascio - cutaneous flap was raised till the anterior border of the parotid gland. The greater auricular nerve was identified, mobilised and preserved.<sup>[22]</sup> Nerve stimulator was not used. Then we identified the zygomatic branch of the facial nerve which is having relatively predictable and superficial course where it crosses the zygomatic arch by dissecting the parotid tissue over it [Figure 1]. After that the zygomatic branch is traced in a retrograde manner by blunt and sharp dissection to identify the facial nerve trunk. Then each of the facial nerve branches are dissected out while lifting up the superficial lobe along with the lesion [Figure 2]. A corrugated drain was placed after every surgery which was removed between post-operative days 3 to 5.

### RESULTS

**Table 1: Evolution of parotid surgeries.**

Surgery	First described by	Year
Enucleation	Senn	1895
Retrograde technique	Sistrunk	1921
Superficial parotidectomy	Janes	1940
Extra capsular dissection	Anderson	1975
Partial superficial parotidectomy	Lizuka and Ishikawa	1978

**Table 2: House – Brackman score.**

Grade	Description	Gross function	Resting appearance	Dynamic appearance
1	Normal	Normal	Normal	Normal
2	Mild dysfunction	Slight weakness with effort, may have mild synkinesis	Normal	Mild oral and forehead asymmetry. Eye closure with minimal effort.
3	Moderate dysfunction	Obvious asymmetry with effort.	Normal	Mild oral asymmetry, complete eye closure with effort. Slight forehead movement.
4	Moderately severe dysfunction	Obvious asymmetry	Normal	Asymmetrical mouth, incomplete eye closure, no forehead movement.
5	Severe dysfunction	Barely perceptible movement	Asymmetry	Slight oral or nasal movement with effort, incomplete eye closure
6	Total paralysis	No movement	Asymmetry	No movement

**Table 3: Types of parotidectomy.**

No.	Surgery	Procedure done
1.	Superficial parotidectomy	Entire parotid gland lateral/superficial to facial nerve is removed.
2.	Total parotidectomy	Entire parotid gland removed.
3.	Selective deep lobe parotidectomy	Only deep lobe of the parotid gland removed.
4.	Partial superficial parotidectomy	Lesion along with a cuff of normal parotid tissue of the superficial part of parotid gland removed.
5.	Extracapsular dissection.	Lesion is dissected just outside the capsule without nerve dissection.

**Table 4: Temporary facial nerve injury.**

Temporary facial nerve paresis.	At 1 week	At 1 month	At 3 months	At 6 months
% of patients affected (n=40)	75% (n=30)	35% (n=14)	20% (n=8)	0%
% of patients completely recovered	25% (n=10)	65% (n=26)	80% (n=32)	100% (n=40)

**Table 5: Time taken for recovery.**

House-Brackman score	No. of patients affected	Number of patients with temporary facial nerve weakness at the end of 1st week.	Time taken for Duration for recovery. (in weeks)
Normal	10		-
Mild dysfunction	24 (60%)		16 patients recovered in 4 weeks, 6 in 12 weeks & 2 in 12- 14 weeks.
Moderate dysfunction	3 (7.5%)		12- 16
Moderately severe dysfunction	2 (5%)		16-20
Severe dysfunction	1 (2.5%)		24
Total paralysis	0		

**Table 6: Parameters**

Parameters	Result
Mean Operation time	88min
Frey's syndrome	6 (15%)
Salivary fistula formation	0

**Table 7: Percentage of complications obtained in various studies.**

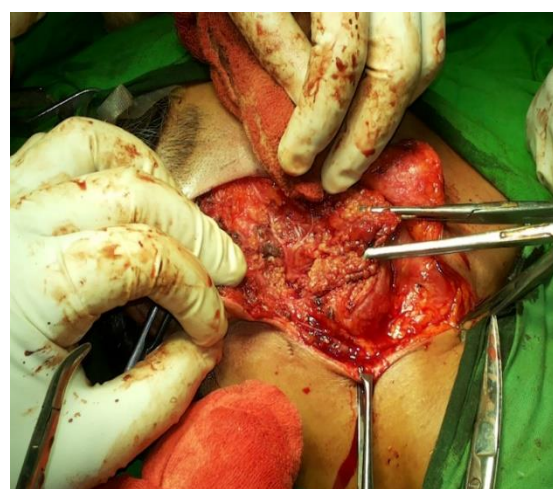
RETROGRADE SUPERFICIAL PAROTIDECTOMY					
Author	Nerve paralysis		Other complications		
	% of facial nerve paresis	% of permanent facial nerve paralysis	Frey,s syndrome	Salivary fistula	
1. K. Anjum etal [15]; 2008; n= 40	45% (n=18)	0%	20%	2.5%	
2. O'regan etal [11]; 2011 ; n=15	60 % ( with HBSIII or more at week 1) 0% ( with HBSIII or more at 6 months)	0%	-	-	
3. Yu ting lai etal [16]; 2015; n=54	22.2%(n=12)	0%	61%	0	
4. Sreshta S etal [17]; 2011; n=25	16% (n=4)	0%	-	4%	
5. Gurung etal [18]; 2017; n=60	13.33% (n=8)	0%	0	1.6%	
6. Mohammood V.H etal [23];2012;n=15	26% (n=4)	0%	0%	-	

Among 40 patients 28 were females and 12 were males. Mean age of female patients was 48 and that of male patients was 51 [Figure 3]. All patients were having unilateral lesions confined to the superficial lobe of parotid gland. All patients underwent retrograde superficial parotidectomy.

Although all 40 patients experienced paresis immediately after surgery, 10 patients (25%) completely recovered and total 30 patients (75%) had facial nerve weakness at the end of first week [Table 4]. Among these 30 patients, 24 patients (60%) were having H.B-2 weakness, 3 patients (7.5%) had H.B-3 weakness, 2 had H.B-4 (5%) and 1 had H.B-5 weakness (2.5%). Any injury equal to or more than H.B-3 was considered serious. Thus 6 patients were having serious injury (15%). None of the patients had H.B-6 (severe) facial nerve weakness.

Among patients with H.B-2 paresis, 16 recovered completely at the end of one month. Among remaining 8 patients, 6 patients recovered by the end of 3rd month and the rest 2 recovered completely between 12 and 14 weeks. Patients with H.B-3 paresis (3 patients) recovered between and 16 weeks after surgery. 2 patients who had H.B-4 paresis got

recovered by 20 weeks and one patient with H.B-5 paresis recovered by 24 weeks [Table 5 & Figure 4]. The mean operative time was 88 minutes. Frey's syndrome was developed in 6 patients. None of the patients had salivary fistula formation or tumour recurrence during follow up [Table 6].



**Figure 1: Identifying the zygomatic branch of facial nerve.**



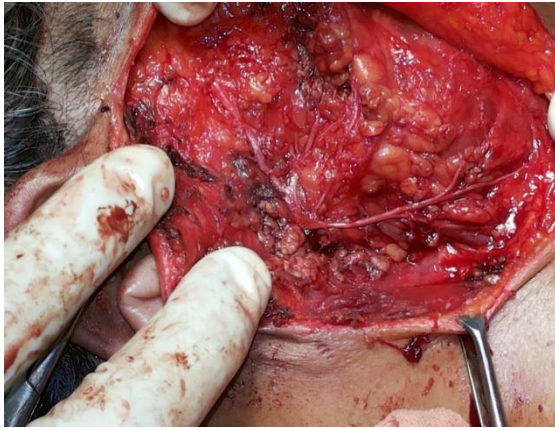


Figure 2: All branches of facial nerve identified.

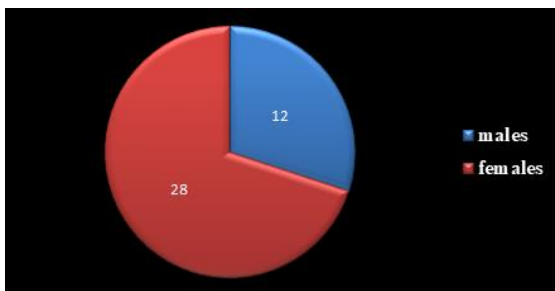


Figure 3: Number of patients.

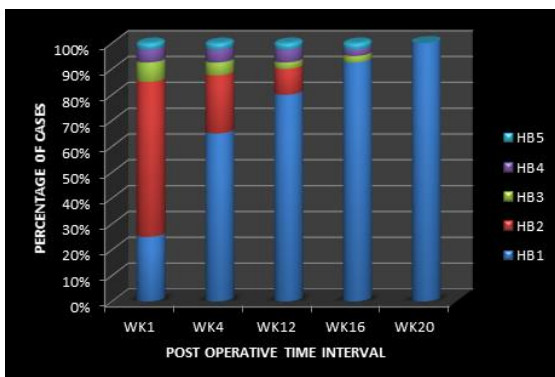


Figure 4: Nerve recovery rates.

## DISCUSSION

Recurrences after parotid surgery for pleomorphic adenoma was high in previous days and the reason for which identified was leaving small projections of tumour tissue into the normal surrounding parotid parenchyma, while doing enucleation. Later evolved superficial parotidectomy technique, although was a success to reduce recurrences, since superficial lobe constitutes 80% of the parotid gland, removal of the same resulted in significant reduction in parotid function. Thus surgeons started doing function preserving parotidectomy.

In ante grade superficial parotidectomy main trunk of the facial nerve is identified using the land marks such as tympanomastoid suture, tragal pointer, and posterior belly of digastric muscle. Then dissection is carried out to remove the entire superficial lobe along with the lesion. Advantages of this technique

are adequate resection of the lesion and ease for teaching. Also is a better choice if the diagnosis is not clear or if tumour involves one or more of the branches of facial nerve or the facial nerve trunk itself.<sup>[1]</sup> Disadvantages are, need for more extensive dissection which leads to increased incidence of facial nerve injury, longer operative time, more loss of normal parotid tissue, more blood loss and larger contour defect.<sup>[5]</sup> This technique is also more difficult to conduct in obese patients due to increased difficulty in finding facial nerve trunk.

In obese patients even an experienced surgeon may fail to identify the facial nerve trunk also in patients with large tumours and in revision surgeries. Retro grade technique includes identifying any one or two main branches of the facial nerve near to the lesion and then dissection is proceeded to remove the lesion without exposing the main trunk of the facial nerve. Advantages of this procedure includes avoidance of injury to the main trunk and unexposed branches of the facial nerve, less blood loss, shorter operative time, removal of less normal parotid tissue and a more favourable cosmetic outcome.<sup>[1,6]</sup> This technique also offers wide operative field visibility for both surgeons and the assistants thus resulting in less traction induced nerve injuries.<sup>[7]</sup> A wider operative field will help in easier dissection and better haemostasis. If the tumour is large or if the main trunk of the facial nerve is displaced by the tumour, it will be difficult to expose the main trunk and the retrograde technique may be useful.<sup>[8]</sup> R.S.P is more advisable for lesions that are located along the anterior or the inferior border of the gland as these lesions can be excised with minimal dissection and removal of minimal amount of normal parotid tissue. Also incidence of recurrence rates are also comparable with that of A.S.P.<sup>[9,10]</sup>

One possible drawback of this technique is that, if multiple intercommunicating branches are present it may result in following these branches and doing unnecessary dissection. In this circumstance nerve stimulator will help us to proceed in the proper direction.<sup>[1]</sup> Also patients with potentially metastatic lesions, high grade malignancies and those cases that may require concurrent neck dissection are also poor candidates for this approach. In such cases if it is found that the tumour is involving the facial nerve trunk R.P.S.P must be converted to ante grade technique.<sup>[1]</sup> Incidence of nerve injuries reported in various studies is given in [Table 6].

None of the compared studies had reported a permanent facial nerve paresis after retrograde parotidectomy which is also true in our study. O' regan et al in 2011 studied on outcome and recovery of facial nerve injuries after both ante grade and retrograde parotidectomies and concluded that temporary paresis after retrograde dissection recovers more faster at 3 months post-operative than those after ante grade dissection.<sup>[11]</sup>

73% of patients recovered their facial paresis at the end of 3 months in the present study. In our study only 15% of patients had serious facial nerve injury at week 1. (more than or equal to H.B-3). O' Regan in his study had 66% of patients with such injury which is much higher than ours. This difference may be due to inclusion of total parotidectomy also (4 among 20). Also at 6 months he found that both group had similar outcome with none of the patients having any residual paresis. In the present study also all patients recovered completely at the end of 6 months.

Lai Y. T et al, in his study reported an incidence of 22.2% of temporary facial nerve paralysis and 61% incidence of Frey's syndrome.<sup>[16]</sup> Anjum et al reported an incidence of 45% of temporary facial nerve injury and 20% incidence of Frey's syndrome. In a recent study it was reported that the incidence of temporary facial nerve injury after R.P was 13.6% and none were more than HB-2 (house brackman score).<sup>[7]</sup> Bhattacharya et al had,<sup>[11]</sup> in his study in 2004, none of his patients injured (temporary or permanent) their facial nerve that underwent retrograde parotidectomy. Wang et al also reported no incidence of facial nerve paresis on his study of 383 patients.<sup>[12]</sup>

Even though in almost all recent studies buccal branch or marginal mandibular branch of facial nerve is mentioned as the most reliable branch for retrograde facial nerve dissection,<sup>[11,15,16]</sup> in the present study we followed zygomatic branch of facial nerve and concluded that the later is also dependable for the retrograde dissection. The lower border of the zygomatic arch is a reliable bony landmark for the zygomatic branches.<sup>[6]</sup>

Many studies have shown that retrograde technique reduces duration of surgery.<sup>[1,5,9,17]</sup> In the present study mean surgery duration is 88 minutes and is comparable with observations in the above studies. Kornbult A.D et al and Singleton G.T observed that in almost all cases Frey's syndrome will be present if starch-iodine test is done. Incidence of Frey's syndrome can be reduced by smaller partial resections.<sup>[19-21]</sup> Most of the patients experienced dryness of mouth and paresthesia on the side of surgery which got subsided in time. None of the patients had salivary fistula formation or recurrence of tumour during follow up.

## CONCLUSION

1. Transient nerve weakness after retrograde parotidectomy is common but recovery will be faster than that of ante grade technique and within 6 months to 1 year all patients should recover nerve function completely.
2. It seems prudent to recommend that the retrograde parotidectomy approach be considered for straight forward cases that are highly likely to represent benign disease in a favourable location.

3. Zygomatic branch of facial nerve is also a reliable a landmark for doing retrograde parotidectomy and is having comparable complication rates as those for established techniques.

## REFERENCES

1. Bhattacharyya N, Richardson ME, Gugino LD. An objective assessment of the advantages of retrograde parotidectomy. *Otolaryngol Head Neck Surg* 2004;131:392-6.
2. O'Brien CJ. Current management of benign parotid tumours—the role of limited superficial parotidectomy. *Head Neck* 2003;25:946-52.
3. Witt RL. Facial nerve function after partial superficial parotidectomy: An 11-year review (1987-1997). *Otolaryngol Head Neck Surg* 1999;121:210-3.
4. Zbaren, P., et al., Recurrent pleomorphic adenoma of the parotid gland. *Am J Surg*, 2005. 189(2): p. 203-7.
5. Emodi O, El-Naaj IA, Gordin A, Akrih S, Peled M. Superficial parotidectomy versus retrograde partial superficial parotidectomy in treating benign salivary gland tumor (pleomorphic adenoma). *Journal of oral and maxillofacial surgery : official journal of the American Association of Oral and Maxillofacial Surgeons*. Sep 2010;68(9):2092-2098.
6. O'Regan B, Bharadwaj G, Bhopal S, Cook V. Facial nerve morbidity after retrograde nerve dissection in parotid surgery for benign disease: a 10-year prospective observational study of 136 cases. *The British journal of oral & maxillofacial surgery*. Mar 2007;45(2):101-107.
7. Kligerman M, Song Y, Schoppy D. Retrograde Parotidectomy and Facial Nerve Outcomes: A Case Series of 44 patients. *American journal of otolaryngology*. 2017;38(5):533-36.
8. Wong DSY. Surface landmarks of the facial nerve trunk: a prospective measurement study. *Aust NZ J Surg* 2001;71:753-6
9. Roh JL, Kim HS, Park CI. Randomized clinical trial comparing partial parotidectomy versus superficial or total parotidectomy. *The British journal of surgery*. Sep 2007;94(9):1081-1087.
10. Huang G, Yan G, Wei X, He X. Superficial parotidectomy versus partial superficial parotidectomy in treating benign parotid tumors. *Oncology letters*. Feb 2015;9(2):887-890
11. O'Regan B, Bharadwaj G. Comparison of facial nerve injury and recovery rates after antegrade and retrograde nerve dissection in parotid surgery for benign disease: prospective study over 4 years. *The British journal of oral & maxillofacial surgery*. Jun 2011;49(4):286-291.
12. Wang DZ, Liu SJ, Donoff RB, Guralnick W. A modified centripetal approach to parotidectomy. *J Oral Maxillofac Surg* 1985;43:14-9.
13. Snow GB. The surgical approaches to the treatment of parotid pleomorphic adenomas. In: McGurk M, Renehan AG, eds. *Controversies in the Management of Salivary Gland Disease*. Oxford, England: Oxford University Press; 2001:chap 5, 58.
14. Foresta E, Torroni A, Di Nardo F, de Waure C, Poscia A, Gasparini G, et al. Pleomorphic adenoma and benign parotid tumors: extracapsular dissection vs superficial parotidectomy -- review of literature and meta-analysis. *Oral Surg Oral Med Oral Pathol Oral Radiol*. 2014;117:663--76.2
15. Anjum K, Revington PJ, Irvine GH. Superficial parotidectomy: antegrade compared with modified retrograde dissections of the facial nerve. *Br J Oral Maxillofac Surg* 2008;46:433-434.
16. Lai YT, Liang Q, Jia XH, Zhang XT. Tumor recurrence and complications of parotidectomy using the marginal mandibular branch as a landmark during the retrograde technique. *The Journal of craniofacial surgery*. Mar 2015;26(2):e193-195.
17. Shrestha S, Gurung NV, Upadhyaya P. Superficial Parotidectomy: Comparison of Antegrade Versus Retrograde

- Facial Nerve Dissection.postgraduate medical journal of NAMS.2011;11:38-40
18. Gurung N.V, Shrestha D1, Acharya A. Superficial Parotidectomy by Retrograde Facial Nerve Dissection. Journal of Gandaki Medical College-Nepal. 2017;10(1):25.
  19. Kornblut AD, Westphal P, Miehke A. A re-evaluation of the Frey syndrome following parotid surgery. Arch Otolaryngol 1977;103:258–61.
  20. Singleton GT, Cassisi NJ. Frey's syndrome: incidence related to skin flap thickness in parotidectomy. Laryngoscope 1980;90:1636–9.
  21. Wenmo C, Spandow O, Emgard P, et al. pleomorphic adenomas of the parotid gland: superficial parotidectomy or limited excision? J Laryngol Otol 1988;102:603-5.
  22. Hui Y, Wong DS,Wong LY, Ho WK,Wei WI. A prospective controlled double-blind trial of great auricular nerve preservation at parotidectomy. Am J Surg 2003; 185: 574–579
  23. Mohamood V.H . Buccal Branch as a Guide for Superficial Parotidectomy.The Journal of Craniofacial Surgery. 2012; 23:5.

**How to cite this article:** Biswal JK, Sebastian J. Retrograde Facial Nerve Dissection Using Zygomatic Branch as Landmark in Parotid Gland Surgery for Pleomorphic Adenoma: A 4 Year Prospective Study of 40 Cases. Ann. Int. Med. Den. Res. 2018; 4(3):SG14-SG19.

**Source of Support:** Nil, **Conflict of Interest:** None declared