

Comparison of the Diagnostic Accuracy of FNAC and Biopsy in the Diagnosis of a Palpable Breast Lump.

Mohammad Shuaib¹, Avinash Chandra Sharma², Akhil Kumar Gupta³, Rizwan Ali⁴, Mohd. Mojeeb Ahsan², Zainab Inam⁵, Mohsin Ali⁶

¹Assistant Professor, Department of Surgery, Muzaffarnagar Medical College, Muzaffarnagar, Uttar Pradesh, India.

²Associate Professor, Department of Surgery, Muzaffarnagar Medical College, Muzaffarnagar, Uttar Pradesh, India.

³Professor, Department of Surgery, Muzaffarnagar Medical College, Muzaffarnagar, Uttar Pradesh, India.

⁴Private Practitioner, General Surgeon, Muzaffarnagar, Uttar Pradesh, India.

⁵Private Practitioner, Obstetrician & Gynaecologist, Muzaffarnagar, Uttar Pradesh, India.

⁶Senior Resident, Department of Medicine, Muzaffarnagar Medical College, Muzaffarnagar, Uttar Pradesh, India.

Received: March 2018

Accepted: April 2018

Copyright: © the author(s), publisher. It is an open-access article distributed under the terms of the Creative Commons Attribution Non-Commercial License, which permits unrestricted non-commercial use, distribution, and reproduction in any medium, provided the original work is properly cited.

ABSTRACT

Background: Mammary gland carcinoma is the most common malignant tumor. Annually worldwide more than 1,000,000 cases of breast carcinoma occur, which is the leading cause of carcinoma death in women. The most relevant and important method to diagnose breast cancer is Fine Needle Aspiration Cytology (FNAC). The use of core needle biopsy (CNB) has been increasing because of various limitations. Advantages of core needle biopsy over FNAC is, that core needle biopsy provide sufficient tissue for definitive histological diagnosis, differentiate between invasive cancer and carcinoma. The purpose of this study was to determine if there is a difference in diagnostic accuracy in using CNB and FNAC in patients with palpable breast lumps undergoing breast surgery. **Methods:** This was cross sectional type of study conducted in the Department of General Surgery at Muzaffarnagar Medical College, Muzaffarnagar. The study was carried out from July 2016 to March 2018. The study population was recruited from the patients presenting with suspicious palpable breast lump clinically and/or radiologically, attending at General Surgery Outpatient Department (OPD), Muzaffarnagar Medical College, Muzaffarnagar. Hundred (100) patients suffering from breast lumps were included in this study. **Results:** Total 58 patients (58% of total patients with breast lump) were found with malignancy having C5 category of FNAC. All of them confirmed malignancy after the surgery. FNAC showed malignancy in 58% cases of breast lump. There was no false positive case in FNAC findings. Rest of 42 patients showed non-malignant breast lumps which showed C2, C3 and C4 category of FNAC. Findings after excision biopsy showed that there were 26 patients (26%) were false negative. **Conclusion:** Findings of the present study suggest that FNAC is almost equally effective technique for the diagnosis of malignancy in patients suffering carcinoma of mammies. FNAC is considered as an economical, less complicated, rapid and reliable method for the pathological diagnosis of breast carcinoma in a developing country like India. Malignant tumour can be exactly diagnosed by FNAC as it is highly sensitive for malignancy. CNB should be put after FNAC If initial FNAC fails to determine the type of tumour, CNB can be a useful second line method of pathological diagnosis in order to minimize the chance of missed diagnosis of breast cancer. Excision biopsy should be considered as last option for pathological diagnosis.

Keywords: FNAC, CNB, Breast cancer, Breast lumps.

INTRODUCTION

Mammary gland carcinoma is the most common malignant tumor. Annually worldwide more than 1,000,000 cases of breast carcinoma occur, which is the leading cause of carcinoma death in women.^[1] The most relevant and important method to diagnose breast cancer is Fine Needle Aspiration Cytology (FNAC), but technological problems such as limited cellularity, excessive air drying and/or

artificial mechanical disaggregation can potentially limit the interpretation, as well as put into a false-negative or a false-positive diagnosis of malignancy, respectively. However, in our experience as well as that of others, the major present limitation of FNAC is differentiating DCIS from invasive carcinoma and the separation of atypical ductal hyperplasia (ADH) from ductal carcinoma in situ (DCIS) which affects the patient's management. Occasional inability to make a definitive diagnosis of low-grade carcinomas, such as tubular carcinoma or invasive lobular carcinoma, papillary and fibroepithelial lesions, differentiate primary from metastatic carcinoma are the other major limiting factors. A further most important concern in breast FNAC is the potential false-positive diagnoses in the

Name & Address of Corresponding Author

Dr. Avinash Chandra Sharma,
Associate Professor,
Department of Surgery,
Muzaffarnagar Medical College,
Muzaffarnagar, Uttar Pradesh, India.

aspiration of a number of benign reactive, inflammatory, and metaplastic breast lesions, prompting inappropriate treatment having clinical and medicolegal implications.^[2] FNAC and core needle biopsy (CNB) without aspiration are the techniques of FNB. Both methods are all cytological studies. FNAC technique is painful, many times is traumatic and results in hematoma formation. This technique depends on suction and thus yields hemorrhagic material for cytological study. Patients are anxious because of the needle mounted on the syringe, unlike FNS. This, therefore, affects the diagnostic precision and capability of FNAC.^[3-6] Greater ease of sampling has been provided by Fine Needle Sampling with better control of the hand, a good insight of the lesion, more accurate entry into the mass and patients are much less anxious when no syringe is used and the smears obtained are without much blood in the background, hence with much less artefacts and better cellularity.^[4-6]

The use of CNB has been increasing because of these limitations. Advantages of core needle biopsy over FNAC is, that core needle biopsy provide sufficient tissue for definitive histological diagnosis, differentiate between invasive cancer and carcinoma in situ patients for whom FNAC is inconclusive due to not enough samples but having suspicious ultrasound and/or mammography findings; and breast lesions with microcalcifications; and for research purpose tissue banking specimen core needle biopsy is of great advantage.^[7] Multiple tumor tissue samples can be taken in core needle biopsy due to increased cross-sectional diameter, with an amount of up to 20 mg for which the diagnostic is easier. It is reported that with the first sample collected of core needle biopsy an accuracy rate of up to 90.1% can be achieved. The procedure has now become easier and diagnostic efficacy has been improved with the recent introduction of 14G core biopsy needle and automated large core biopsy gun. We, therefore, carry out this study to diagnose breast carcinoma by comparing between Fine Needle Aspiration Cytology (FNAC) and Core Needle Biopsy (CNB). The purpose of this study was to determine if there is a difference in diagnostic accuracy in using CNB and FNAC in patients with palpable breast lumps undergoing breast surgery in Muzaffarnagar Medical College, Muzaffarnagar. However, for breast masses, no adequate studies have been documented as regards the use of FNS.

MATERIALS AND METHODS

This was cross sectional type of study conducted in the Department of General Surgery at Muzaffarnagar Medical College, Muzaffarnagar. The study was carried out from July 2016 to March 2018. The study population was recruited from the patients presenting with suspicious palpable breast lump clinically and/or radiologically, attending at General

Surgery Outpatient Department (OPD), Muzaffarnagar Medical College, Muzaffarnagar. Hundred (100) patients suffering from breast lumps were included in this study.

As per the preoperative protocol all the patients underwent for all three procedures - Fine Needle Aspiration Cytology (FNAC), Core Needle Biopsy (CNB) and subsequent excision surgeries done at Department of General Surgery. None of the patients had received chemotherapy, radiotherapy, or hormone therapy between CNB and surgical excision.

FNAC technique

The FNAC was done by the principal investigator. After gloving, the skin over the breast lump was cleansed with antiseptic followed by determination of location for FNAC by palpitation. Non-dominant hand's thumb and index fingers were used to immobilize the lump. The fine needle was inserted into the lesion and later a vacuum created. The needle was moved back and forth within the tumour several times. The biopsy manoeuvre was terminated when fluid appeared in the hub. Then the needle was removed and the sample expressed on the clean dry labelled slide.

Smear preparation and staining.

The samples were expressed on the slides labelled with the patient's laboratory number. Material was spread on the slide by placing a second slide over the aspirated material and gently pulling apart. Slide was immediately fixed by 95% ethanol and stained with papanicolaou stain while the second slide was air dried and stained with a Romanowosky stain. The slides were then covered with cover slips and examined by the cytopathologist.

Regarding diagnosis, outcomes of FNAC and CNB were reported using the standard NHSBSP criteria (National Health Service Breast Screening Programme) (Table 1) The histological diagnosis obtained from tissue sections from excision specimens were categorised into two broad groups: carcinoma i.e. malignancy- diagnosed and malignancy- not-diagnosed (include all benign, with atypia, suspicious, etc.) following conventional histological protocol for individual diagnosis.

Statistical analysis

Results were expressed as mean \pm sd (standard deviation). The Chi-square test was conducted to assess the relationship between categorical variables including the clinic pathologic parameters of prognostic significance The Fisher's-exact test was used when expected cell counts were less than five.

RESULTS

Results of the present study was expressed as mean \pm sd. Results of the present study showed that mean age of all 100 patients (Age 25 to 70 years) included in the study was 48.6 \pm 12.6 years. Out of 100 patients

with breast lump 84 patients were found having breast carcinoma. Incidence of breast carcinoma was more common in 31 – 40 years age group, followed by 41 – 50 years age group. [Table 2]

Table 1: Categories of FNAC and CNB according to NHSBSP.

Cytology		Core biopsy	
C1	Unsatisfactory	B1	Normal tissue
C2	Benign	B2	Benign
C3	Possibly benign	B3	Possibly benign
C4	Suspicious for malignancy	B4	Suspicious for malignancy
C5	Malignancy	B5	Malignancy

Table 2: Distribution of breast carcinoma patients according to age groups.

Age group	<30 years	31-40 years	41 – 50 years	>50 years
Number of patients	21	27	23	13
Percentage of patients	25%	32.14%	27.3%	15.4%

Carcinoma was more common in right breast (52.3%) compare to left breast (47.7%). However, there was no significant difference between occurrence of carcinoma in right or left breast. [Table 3]

Table 3: Distribution of breast carcinoma patients according to side affected.

Side of breast	Right	Left
Number of patients	44	40
Percentage of patients	52.3%	47.7%

Upper outer quadrant (41 patients, 50%) of the breast was the most common place for breast cancer. Followed by centre quadrant (14 patients 16.66%) Size of lump was ranged 3 cm to 13 cm, mean 6.87+3.98 cm. Further, malignancy was more common in 54 carcinoma patients (64.3%) having lump size >5 cm.

Eighty patients (80), in whom preoperative sonomammography were suggestive of malignancy (BI-RADS 5); (Breast Imaging Reporting and Data System) all of them were later confirmed as having malignant lesions by HPE of subsequent excision specimens (malignancy outcome = 100%) and none of the patient who was predicted as having benign lesion (BI-RADS 3) was diagnosed other way as having any malignant lesion by final histopathological examination of excision specimens (malignancy outcome = 0.0%) [Table 4 & Figure 2]. All 80 patients of BI-RADS GRADING-5 were subsequently proved as malignant by subsequent of excision specimens.

[Table 5] shows that total 58 patients (58% of total patients with breast lump) were found with malignancy having C5 category of FNAC. All of them confirmed malignancy after the surgery. FNAC showed malignancy in 58% cases of breast lump. There was no false positive case in FNAC findings.

Rest of 42 patients showed non-malignant breast lumps which showed C2, C3 and C4 category of FNAC. Findings after excision biopsy showed that there were 26 patients (26%) were false negative.

On the other hand, CNB findings showed that 70 patients were found under malignant category B5. Total 70 % cases of breast lump were found malignant by CNB technique. [Figure 1] CNB showed 30 % cases as non-malignant.

Table 4: Distribution of patients according to BI-RADS GRADING based on mammography reports.

	Malignant	Non-Malignant	Total
BI-RADS GRADING III	0	14	14
BI-RADS GRADING IV	4	2	6
BI-RADS GRADING V	80	0	80
Total	84	16	100

Table 5: Distribution of all patients according FNAC and CNB

	FNAC categories					Total
	C1	C2	C3	C4	C5	
Number and % of patients FNAC	0	28	4	10	58	100
	-	28%	4%	10%	58%	100%
	CNB categories					Total
	B1	B2	B3	B4	B5	
Number and % of patients CNB	0	16	6	8	70	100
	-	16%	6%	8%	70%	100%

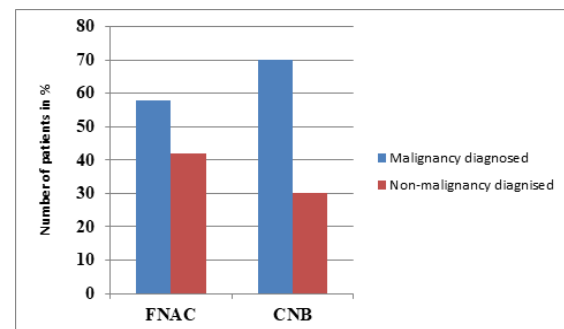


Figure 1: Distribution of patients as per their diagnosis on the basis of FNAC and CNB

[Table 6] shows that 84 patients out of 100 patients showed malignancy after subsequent surgery has been done. Excision biopsy of the breast tissue confirmed carcinoma in 84% patients with breast lump.

Table 6: Distribution of all patients according to final diagnosis confirmed after surgery.

	Malignant	Non-malignant	Total
Number of patients	16	84	100
Percentage of patients	16%	84%	100%

DISCUSSION

Traditional method of diagnosis of breast lumps was excision biopsy of the breast. Improving the techniques for establishing diagnosis of breast lump before surgery is a topic of recent attention. Various studies have been done to compare the role of FNAC and CNB in the diagnosis of breast cancer.^[8,9] The present study compares the diagnosis of breast mass established by FNAC and CNB. Findings of the present study have shown that mean age of all 100 patients included in the study was 48.6±12.6 years. Incident of breast cancer was more common in 31 to 40 years age group (31%) followed 28% in 51 to 60 years age group. These findings are in agreement with previous study of Khemka A et al,^[8] as they recorded higher incident of breast carcinoma near the age of 40 years. Demographic trends in India suggest that age of tendency of developing breast cancer is decreasing in India and now majority number of patients belong to 25 to 40 years age group.^[10]

On the basis of side affected 52.3 % patients had right side while 47.7 % patients had left side breast carcinoma. These findings are consistent with the findings of the previous study of Aljarrah A et al.^[11] In which they recorded frequency of breast cancer was almost equal in both side 52.4% right side whereas 47.6% left side.

Upper outer quadrant was the most common part affected by breast carcinoma. 38 patients out of 84 breast cancer patients had carcinoma in upper outer quadrant followed by 16% lesions in central quadrant. In addition, 50% patients out of 100 patients had breast lump in upper outer quadrant. These findings are consistent with the earlier study Aljarrah A et al,^[11] in which they showed breast carcinoma was most common in upper outer quadrant of breast. Similarly, Husain et al,^[12] recorded frequency of breast lump was highest in 58% of patients in upper outer quadrant.

These findings can be helpful as early diagnosis of breast cancer can enhance the possibility of patients' survival as breast cancer in centre quadrant compare to any other quadrant have poor prognosis.^[13] Therefore, it is necessary to evaluate the location of breast lump. Alike, Lohrisch C et al,^[14] and Sarp S et al 15 recorded breast carcinoma was more common in medial side compare to lateral side of breast.

Out of 100 patients of present study, Size of lump was ranged 3 cm to 13 cm, mean 6.87+3.98 cm. Further, malignancy was more common in 54 carcinoma patients (64.3%) having lump size >5 cm. These findings are consistent with the findings of previous study of Jombwe et al and Franzens S et al as they observed a malignancy positive in breast lumps >5 cm in size.^[16,17] Increased size of breast lump is considered one of the important prognosis markers. Diverse studies stated that increase size of

tumours is indirectly related to survival age of the patients.^[16-18]

Results of the present study showed that both techniques FNAC and CNB were 100% free from false positive. These findings are in agreement with earlier studies of Homesh NA et al, and Usami S et al in which they observed similar sensitivity of both techniques.^[19,20]

CONCLUSION

Findings of the present study suggest that FNAC is almost equally effective technique for the diagnosis of malignancy in patients suffering carcinoma of mammary glands. FNAC is considered as an economical, less complicated, rapid and reliable method for the pathological diagnosis of breast carcinoma in a developing country like India. Malignant tumour can be exactly diagnosed by FNAC as it is highly sensitive for malignancy. CNB should be put after FNAC If initial FNAC fails to determine the type of tumour, CNB can be a useful second line method of pathological diagnosis in order to minimize the chance of missed diagnosis of breast cancer. Excision biopsy should be considered as last option for pathological diagnosis.

However, we emphasise more studies are required to establish a generalized policy for the diagnosis of breast cancer.

REFERENCES

1. Breast Ch. No. 20 in Juan Rosai (ed.), Rosai and Ackerman's Surgical Pathology, Vol-II, 10th ed. Elsevier, 2011: 1660-1771.
2. Ducatma BS, Wang HH. Breast. Chapter 9 Breast. In: Edmund s. Cibas, Barbara S. Ducatman, (ed.) Cytology Diagnostic Principles and Clinical Correlates, 4th edition. Philadelphia, USA: Elsevier Saunders; 2014. Pp. 233-66.
3. Raghuvver CV, Leekha I, Pai MR, Adhikari P, Fine needle aspiration vs fine needle sampling without sampling in the diagnosis of superficial masses (2002), A prospective study of 200 cases. Indian J Med Sci 2002;56:431-9.
4. Bhattacharya S, Raghuvver CV, Adhikari P. FNAC diagnosis of tuberculosis-an eight years study at Mangalore. Indian J, Med Sci 1998;52:498-506.
5. Misra M, Chawla SC, Bandyopadhyay SP. Fine Needle Capillary Sampling (Non Aspiration Technique) Vs Conventional FNAC in Cytological Diagnosis. Cytology 2001; 18:25-30.
6. Kumarasinghe MP, Sherifedeen AH. Fine Needle Sampling without aspiration. Pathology 1995;27:330-332.
7. Raghuvver CV, Leekha I, Pai MR, Adhikari P, Fine needle aspiration vs fine needle sampling without sampling in the diagnosis of superficial masses. A prospective study of 200 cases. Indian J Med Sci 2002;56:431-9.
8. Khemka A, Chakrabarti A, Shah S, Patel V. Palpable breast lumps; Fine Needle Aspiration Cytology versus histopathology: A Correlation Of Diagnostic Accuracy. Internet J Surg. 2009; 18:25-30.
9. Tariq GR, Haleem A, Zaidi AH, Afzal M. Role of FNA cytology in the management Of carcinoma breast. J Coll Phys Surg Pak. 2005;15:207-10.
10. www.breastcancerindia.net/bc/statistics/trendshtm.

11. Aljarrah A, Miller WR Trends in the distribution of breast cancer over time in the south of Scotland and review of the literature *Ecancermedical science*. 2014;8:439-43.
12. Husain MT. Comparison of fine needle aspiration cytology with excision biopsy of breast lump. *J Coll Physician Surg Pak*. 2005;15(4):211-14.
13. Zucali R, et al. Early breast cancer: evaluation of the prognostic role of the site of the primary tumour. *J Clin Oncol*. 1998;16:1363-66.
14. Lohrisch C, et al. Relationship between tumour location and relapse in 6,781 women with early invasive breast cancer. *J Clin Oncol*. 2000;18(15):2828-35.
15. Sarp S, et al. Tumour location of the lower-inner quadrant Is associated with an impaired survival for women with early-stage breast cancer. *Ann Surg Oncol*. 2007;14:1031.
16. Jombwe J. The use of fine needle aspiration biopsy in the diagnosis of palpable breast masses (2002), dissertation. *MMED Surg*.
17. Franzens S, Zajicek J. Aspiration biopsy in diagnosis of palpable lesions of the breast. Critical review of 3479 consecutive biopsies. *Acta Radiol Therapy Physic* 1968, 7:241-262.
18. Hoda SA, Brosi E, Koerner FC, Rosen PP. *Rosen's Breast Pathology*, 4th edition. Philadelphia, USA: Lippincot Williams & Wilkins; 2014.
19. Homesh NA, et al. The diagnostic accuracy of fine needle aspiration cytology versus core needle biopsy for palpable breast lump(s). *Saudi Med J*. 2005;26(1):42-46.
20. Usami S, et al. Pathological aspects of core needle biopsy for non-palpable breast lesions. *Breast Cancer*. 2005;12(4):272-78..

How to cite this article: Shuaib M, Sharma AC, Gupta AK, Ali R, Ahsan MM, Inam Z, Ali M. Comparison of the Diagnostic Accuracy of FNAC and Biopsy in the Diagnosis of a Palpable Breast Lump. *Ann. Int. Med. Den. Res*. 2018; 4(4):SG10-SG14.

Source of Support: Nil, **Conflict of Interest:** None declared