

# Etiology and Clinicopathological Evaluation of Liver Abscess; A Prospective Study from a Tertiary Hospital Centre

Mohammad Kashif<sup>1</sup>, Shabi Ahmad<sup>2</sup>

<sup>1</sup>Senior Resident, Department of Surgery, Teerthankar Mahaveer Medical College, Moradabad, Uttar Pradesh, India.

<sup>2</sup>Director, Professor and Head, P.G. Department of Surgery, M.L.N. Medical College, Allahabad, Uttar Pradesh, India.

Received: June 2018

Accepted: July 2018

**Copyright:** © the author(s), publisher. It is an open-access article distributed under the terms of the Creative Commons Attribution Non-Commercial License, which permits unrestricted non-commercial use, distribution, and reproduction in any medium, provided the original work is properly cited.

## ABSTRACT

**Background:** Liver abscess is defined as collection of purulent material in liver parenchyma which can be due to bacterial, parasitic, fungal, or mixed infection. Liver abscess are categorized into various types based on etiology, of which Amoebic Liver Abscess and Pyogenic Liver Abscess are major types. Common presenting complains of liver abscess are abdominal pain, fever, and weight loss. Most of the amoebic liver abscesses are typically right lobe solitary abscess. Majority of patients are young alcoholic male of lower socioeconomic class. **Methods:** 60 patients of liver abscess were studied for etiology and clinicopathological evaluation. **Results:** Out of total 60 cases studied, 47 (78.34%) patients had amoebic liver abscess in which 41 (68.33%) patients had primary amoebic liver abscess with positive amoebic serology and rest 6 (10%) cases had amoebic liver abscess with secondary bacterial infection in which amoebic serology and pus culture both were positive. 11 (18.33%) patients had pyogenic liver abscess in which only pus culture was positive and amoebic serology was negative. Rest 2 (3.33%) patients had abscess of indeterminate etiology in which amoebic serology and pus culture both were negative. **Conclusion:** Majority of patients of liver abscesses studied were amoebic in nature with positive amoebic serology.

**Keywords:** Amoebic liver abscess, Pyogenic liver abscess.

## INTRODUCTION

Liver abscess also known as hepatic abscess is an accumulation of pus within liver as a result of an infection. Amoebic Liver Abscess are more common in the developing nations. Pyogenic Liver Abscess constitutes the bulk of hepatic abscesses in developed nations. Amoebiasis is presently the third most common cause of death from parasitic disease. Amoebic liver abscess is caused by parasite protozoan *Entamoeba histolytica*. Pyogenic liver abscess is a condition with significant mortality. Common symptoms of liver abscess are abdominal pain, fever, and weight loss. Two uncommon signs of liver abscess are jaundice and ascites. Pyogenic liver abscess result from ascending biliary tract infection, hematogenous spread through portal venous system, septicemia with involvement of liver by way of hepatic arterial circulation and secondary spread from intraperitoneal infection. Majority of abscesses are multiple which are due to biliary

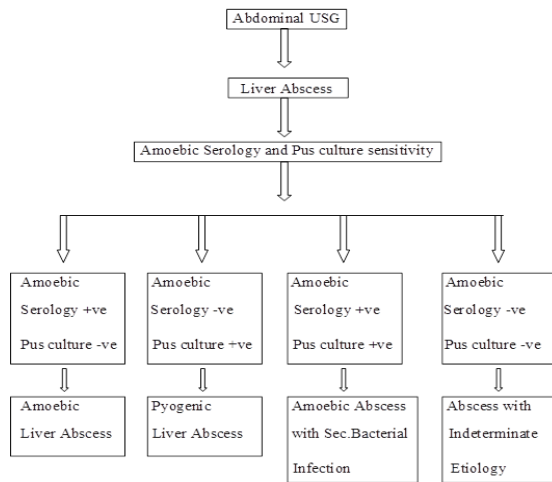
system and arterial circulation and are noted in the right lobe of liver. Solitary or single abscess is due to portal circulation and trauma and may be due to cryptogenic cause. Pyogenic liver abscess are associated with predisposing benign or malignant biliary tract or colonic disease. Etiologically, Gram negative organisms commonly inhabiting the gut and biliary microflora are frequently encountered, *E. coli* being the most common pathogen.

## MATERIALS AND METHODS

This study was conducted on 60 patients at Swaroop Rani Nehru Hospital associated with Moti Lal Nehru Medical College, Allahabad from August 2014 to July 2015 after approval from the ethical committee and obtaining written and informed consent from the patients. All the patients with history and clinical examination suggestive of liver abscess attending surgical OPD and those coming for follow up in outpatient department at regular intervals were included in the study. Patients not willing to participate in the study, dropped out cases during the study period and patients who did not give consent were excluded from the study. After taking informed consent, all patients were subjected to ultrasound guided aspiration of liver abscess either by percutaneous needle or pigtail catheter.

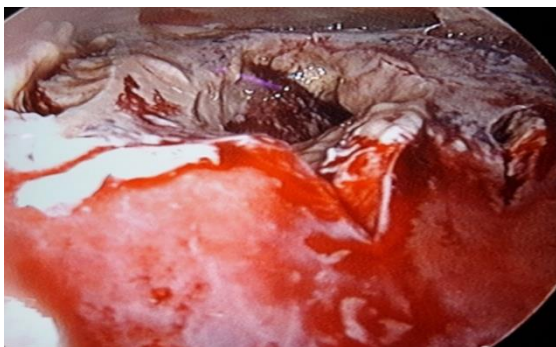### Name & Address of Corresponding Author

Dr. Mohammad Kashif  
Senior Resident, Department of Surgery,  
Teerthankar Mahaveer Medical College,  
Moradabad, Uttar Pradesh,  
India.



### RESULTS

In this study, out of 60, 58 patients (96.67%) were males and 2 patients (3.33%) were females; male to female ratio was 29:1. Fever was the most common presenting symptom in this study present in 46 cases (76.67%). Tenderness at right upper quadrant was the most common clinical sign present in 33 (55%) cases. Out of 60 cases of liver abscess, history of alcoholism were present in 44 (73.33%) cases. Pus aspirated from all abscesses was sent for culture and sensitivity. It showed E.coli in 09 cases (15%), Klebsiella in 06 cases (10%), Enterococcus faecalis in 02 cases (3.33%) and no growth in 43 (71.67%) cases. Amoebic serology (IgM ELISA) done in all cases to confirm the diagnosis. In the present study out of total 60 patients studied, amoebic serology was positive for IgM antibodies with significant titres in 47 (78.33%) patients and absent in 13 (21.67%) patients. Ultrasound usually demonstrates a round or oval area that was less echogenic than the surrounding liver and can reliably distinguish solid from cystic lesions. In this study, 80% (48 patients) of the abscesses were located in right lobe of liver, 15% (09 patients) of the abscesses were located in left lobe of liver and rest 05% (03 patients) of the abscesses were located in both lobes of liver. Out of total 60 cases, 47 (78.34%) patients had amoebic liver abscess, 11 (18.33%) patients had pyogenic liver abscess and rest 2 (3.33%) patients had abscess of indeterminate etiology.



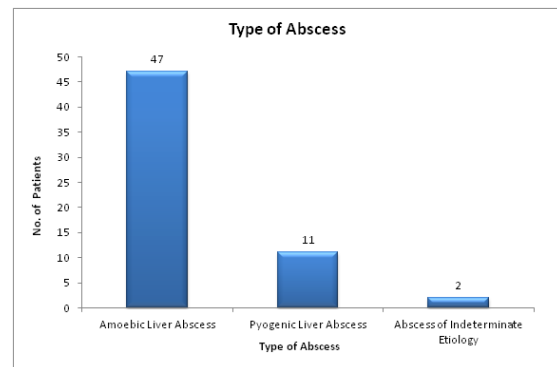
Showing Ruptured Liver Abscess

#### Location of Abscess on the basis of USG

USG Finding	Number (N=60)	Percentage (%)
Right Lobe Liver Abscess	48	80
Left Lobe Liver Abscess	09	15
Both Lobes Liver abscess	03	05

#### Type of Abscess

Type of Abscess	Number of Patients	Percentage (%)
Amoebic Liver Abscess	47	78.34
Pyogenic Liver Abscess	11	18.33
Abscess of Indeterminate Etiology	02	3.33
Total	60	100.0



### DISCUSSION

Liver abscess is a burning problem in tropical nations with often lethal consequences and diagnostic /therapeutic challenges. Diagnosis was made on the basis of clinical features (such as right upper abdomen pain and fever), laboratory investigations and radiological evidence of liver abscess. Amoebic liver abscess was the most common (78.34%) type of liver abscess among the study groups. There was a strong correlation with occurrence of liver abscess and addiction to alcohol, history of diabetes mellitus and low socioeconomic status. Amoebic liver abscess is caused by parasite protozoan Entamoeba histolytica. The most common etiology of pyogenic liver abscess was Escherichia coli. The most common pathogenesis of liver abscess was ascending biliary tract infection. Initially USG was done in all patients of liver abscess. Confirmation of pyogenic liver abscess involves aspiration of abscess as well as positive blood cultures. Amoebic serology (IgM ELISA) done in all cases to confirm the diagnosis of amoebic liver abscess. High quality CT scans can demonstrate very small abscesses and can more easily identify multiple small abscesses.

### CONCLUSION

Liver abscess both amoebic and pyogenic continue to be an important cause of morbidity and mortality

in tropical countries. However recent advances in interventional radiology, intensive care, progressive antibiotic therapy and liberal use of sonography and computerised tomography scanning of abdomen had lead to early diagnosis and treatment of patients with liver abscess, thus improving the patient outcome.

## REFERENCES

1. Perez JY., Jr Amoebic liver abscess: Revisited. Philip J Gastroenterol. 2006;2:11-3.
2. Greenstein AJ, Lowenthal D, Hammer GS, Schaffner F, Aufses AH., Jr. Continuing changing patterns of disease in pyogenic liver abscess: a study of 38 patients. The American Journal of Gastroenterology. 1984;79(3):217-226.
3. Branum GD, Tyson GS, Branum MA, Meyers WC. Hepatic abscess: changes in etiology, diagnosis, and management. Annals of Surgery. 1990;212(6):655-662.
4. Aikat BK, Bhusnurmath SR, Pal AK, Chhuttani PN, Datta DV. Amoebic liver abscess: a clinicopathological study. Indian Journal of Medical Research. 1978;67(3):381-391.
5. Pang TCY, Fung T, Samra J, Hugh TJ, Smith RC. Pyogenic liver abscess: an audit of 10 years' experience. World Journal of Gastroenterology. 2011;17(12):1622-1630.
6. Heneghan HM, Healy NA, Martin ST, et al. Modern management of pyogenic hepatic abscess: a case series and review of the literature. BMC Research Notes. 2011;4, article 80
7. Mukhopadhyay M, Saha AK, Sarkar A, Mukherjee S. Amoebic liver abscess: presentation and complications. Indian Journal of Surgery. 2010;72(1):37-41.
8. Abbas MT, Khan FY, Muhsin SA, Al-Dehwe B, Abukamar M, Elzouki AN. Oman Med J. 2014 Jul;29(4):260-3. doi: 10.5001/omj.2014.69.
9. Gyorffy EJ, Frey CF, Silva J, Jr, McGahan J. Pyogenic liver abscess. Diagnostic and therapeutic strategies. Ann Surg. 1987;206:699-705.
10. Alvarez J, et al, 2001: Pyogenic liver abscesses: a comparison of older and younger patients. HPB (Oxford) 3:201-206.
11. Jha AK, Das A, Chowdhury F, Biswas MR, Prasad SK, Chattopadhyay S. J Nat Sci Biol Med. 2015 Jan-Jun;6(1):71-5. doi: 10.4103/0976 9668.149091.
12. Makkar RP, Sachdev GK, Malhotra V. Alcohol consumption, hepatic iron load and the risk of amoebic liver abscess: A case-control study. Intern Med. 2003;42:644-9.
13. Xiaojuan Zhu, Shaohui Wang, Ravi Jacob, Zhining Fan, Faming Zhang, Guozhong Ji Gut Liver. 2011 June; 5(2): 221-227. Published online 2011 June 27. doi: 10.5009/gnl.2011.5.2.221.
14. Miedema BW, Dineen P. The diagnosis and treatment of pyogenic liver abscesses. Ann Surg. 1984;200:328-335.
15. Ghosh S, Sharma S, Gadpayle AK, Gupta HK, Mahajan RK, Sahoo R, Kumar N. J Trop Med. 2014;2014:142382. doi: 10.1155/2014/142382. Epub 2014 Jun 4.
16. Khan R, Hamid S, Abid S, et al. Predictive factors for early aspiration in liver abscess. World J Gastroenterol. Apr 7 2008;14(13):2089-93. <http://reference.medscape.com/medline/abstract/18395912>

**How to cite this article:** Kashif M, Ahmad S. Etiology and Clinicopathological Evaluation of Liver Abscess; A Prospective Study From a Tertiary Hospital Centre. Ann. Int. Med. Den. Res. 2018; 4(5):SG06-SG08.

**Source of Support:** Nil, **Conflict of Interest:** None declared