

## Evaluation of Ossification of Iliac Crest in Children as Per Risser's Sign in Gurugram Region of Haryana.

Neeru Kapur<sup>1</sup>, Shashi Sharma<sup>2</sup>, B. B. Sharma<sup>3</sup>, Shantanu Singh Chauhan<sup>1</sup>, Mir Rizwan Aziz<sup>4</sup>, Dileep Kumar Jha<sup>4</sup>

<sup>1</sup>Assistant Professor. Dept.of Radio-diagnosis,SGT Medical College Budhera (Gurgaon).

<sup>2</sup>Professor, Deptt of Paediatrics, SGT Medical College Budhera (Gurgaon) 122505.

<sup>3</sup>Professor & HOD, Dept.of Radio-diagnosis,SGT Medical College Budhera (Gurgaon).

<sup>4</sup>Senior Resident, Dept.of Radio-diagnosis,SGT Medical College Budhera (Gurgaon).

Received: September 2018

Accepted: September 2018

**Copyright:** © the author(s), publisher. It is an open-access article distributed under the terms of the Creative Commons Attribution Non-Commercial License, which permits unrestricted non-commercial use, distribution, and reproduction in any medium, provided the original work is properly cited.

### ABSTRACT

**Background:** Risser's sign is a good indicator of skeletal maturity in pediatric age group. The observations drawn from this can be well documented for the age verification and in relation to some pathologies. Ossification centers are evaluated with their further fusion. **Methods:** We carried out the evaluation by this sign in judging the exact skeletal maturity. Twenty one individual group comprising of eight females and thirteen males were included in this study. All children underwent pelvic radiography with antero-posterior view. Their iliac crest ossification and fusion was evaluated. **Results:** Grading of ossification of ileal cartilage was done as per the percentage extent of the ossification from Grade I to V. **Conclusion:** It was observed that there is delay of skeletal maturity in females as compared to males of the same age group in Gurugram region of Haryana which is contrary to the earlier studies conducted in general.

**Keywords:** Risser's sign; ossification centre; pelvic radiography; skeletal maturity.

### INTRODUCTION

The appearance of ossification centers of the ilial apophysis and their further fusion to the iliac crest is important issue in the age determination. This has great value in terms of forensic and criminal evidences. This helps in providing justice to the individual where age dispute is there. Risser's sign in plain pelvic radiography plays a crucial role in the age evidence of the individuals. This also helps in predicting regarding the future scoliosis of the spine.<sup>[1]</sup> The growth of the pelvis continues even after puberty. This is more prolonged in females as compared to males. The variations do exist even in relation to topographical region and socio economic background.

### MATERIALS & METHODS

The study was carried out at the department of Radiodiagnosis of SGT hospital of SGT Medical College & RI Gurugram of Haryana between 02.03.2018 to 13.04.2018. All the cases were selected

at random from outpatient department who had come for radiographic investigations for some other reasons. They were all hailing from the district of Gurugram of Haryana. All underwent X-ray pelvis antero-posterior view in Allengers 800 mA X-ray machine. The exposure factor protocol was strictly followed and all the precautions for radiation safety were observed. The written consent was taken from all the individuals or guardians depending upon case to case basis. Total twenty one cases (n=21) were included in the study comprising from 13 years to 20 years age group (mean age = 16.9 years). This included seven 8 female (38 %) and 13 male (62%). The ossification of the iliac crest was graded according to the percentage of the region. Each quadrant was assessed for the ossification and then for the fusion with the iliac bone.

### RESULTS

Six patient (four male and two female) were found to be having complete ossification of the ilial apophysis and their fusion with the underlying bone. Female age group was showing delayed ossification and fusion as compared to the male counterpart. Following observations were made:  
Grade I in four children (19%)  
Grade II in six children (28.5%)  
Grade III in three children (14.2)

#### Name & Address of Corresponding Author

Shashi Sharma  
Professor,  
Department of Paediatrics,  
SGT Medical College Budhera (Gurgaon) 122505  
C 35 First Floor,  
Anand Niketan, New Delhi - 110021

Grade IV in two children (9.5%)  
 Grade V in six patients (28.5%)  
 The ossification pattern was not tallying as per the standard data but rather as that of individual factors.

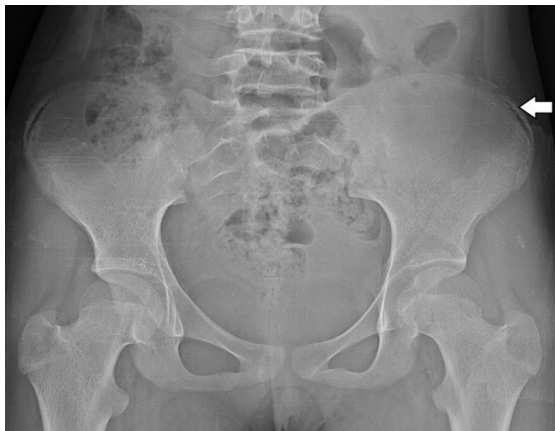

Figure 1: 17-Years female with Grade I ossification depicting 25% of iliac apophysis ossification on the lateral part (horizontal white arrow).

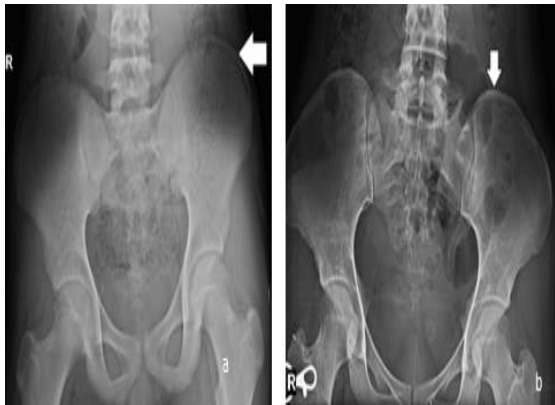


Figure 2: X-ray pelvic antero-posterior view (a) 15 years old male and (b) 20 years old female with Grade II ossification of iliac apophyseal cartilage (white arrows).

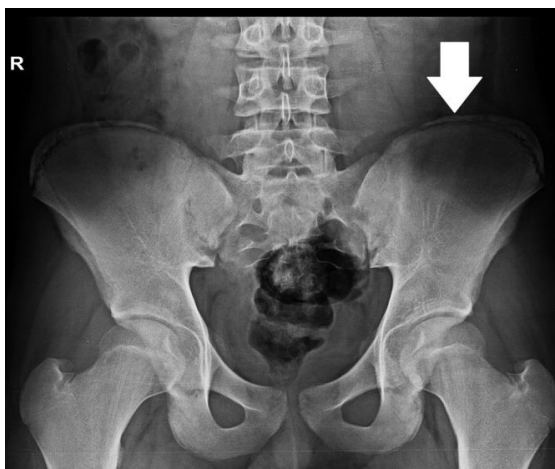

Figure 3: Xray pelvic anteroposterior view of 15 years old boy with Risser's sign Grade IV where iliac apophysis is extending from lateral to the medial side up to the spinal extent (vertical white arrow).

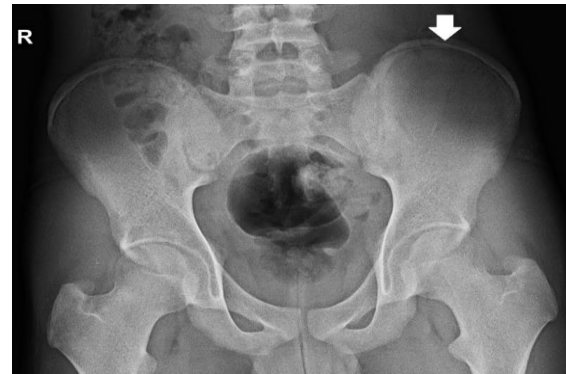

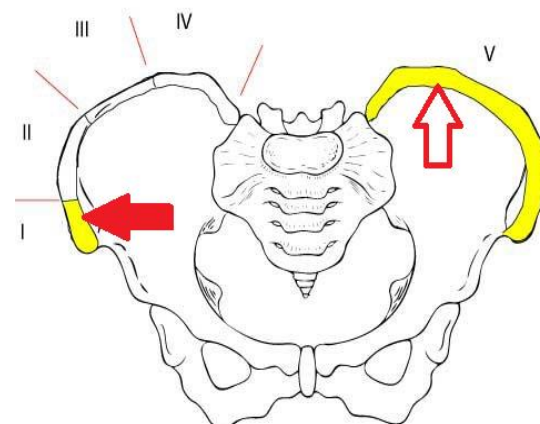
Figure 4: X-ray pelvis anteroposterior view of pelvis of 17 years old boy with Grade V where complete iliac apophyseal ossification and fusion with that of iliac crest (white arrow)

There was delayed skeletal maturity in case of females as compared to males in this region. The other factors which can be attributed are the dietary background. There is also some discrimination of females in Haryana state and the sex ratio is alarmingly declining.

## DISCUSSION

Ilium is one of the innominate bones which unite with ischium and pubis bone in adulthood in the acetabulum. Ilium has got flared upper part called as iliac crest. This extends from the anterior superior to posterior superior iliac spine. Ventral segment is bigger forming two third as compared to the dorsal which is smaller forming rest of one third. The primary centre appears at eighth week of intrauterine life. Two secondary centres for iliac crest appear at the puberty and joins at 15-25 years.<sup>[2]</sup>

Risser staging system is widely used for assessing the skeletal maturity and predicting about the scoliosis.<sup>[3-5]</sup>



Risser Sign

Figure 5: Grading of Iliac crest ossification. Depiction from Grade 1 (red solid arrow) to Grade IV. There is complete fusion of apophysis with the iliac bone which is regarded as Grade V (red hollow arrow)

There is some delay in maturity in axial skeleton as compared to the appendicular. It is very convenient to use this sign in plain radiography. Many reports rely on wrist x-rays rather than Risser grading. Postero-anterior view may give false observation as antero-posterior view is the mainstay for the accuracy. Lateral radiograph may be adjunct to the standard protocol. 1% cases were found to be having fragmented apophysis on the posterior overlapping part which resembled the appearance of iliac apophysis. 10% cases found as variable excursions of iliac apophysis. Shuren et al found apophyseal ossification in the form of capping in the middle part. This may lead to the miscalculations. Some authors have suggested the lateral radiograph in addition to the antero-posterior view. 3D-CT scores over the Rigger staging by removing these doubts about excursions and structural contours.<sup>[6]</sup>

Ultrasonography is a useful tool and is complemented with X-ray for the microcalcification and the extent of ossification as this is without any ionizing radiation. This is more suitable for the pediatric age group.<sup>[7]</sup> The accuracy can be increased by modifying to minimize the divisions of iliac apophysis. As per this following is the categorization

Stage 0: No ossification

Stage 1: Ossification less than one-fourth anywhere in iliac wing

Stage 2: Ossification of  $> 1/4$ th but  $< 2/4$ th of the iliac wing without any fusion.

Stage 3: Ossification  $2/4$ th -  $3/4$ th of iliac wing with appearance of fusion

Stage 4: appearance of complete iliac apophysis without fusion with the iliac crest

Stage 5: Complete fusion of apophysis with the ilium

Ossification age is a very important issue among children and young adults. This evaluation has got a great forensic value. This sign is of great help in assessing the skeletal maturity and predicting scoliosis.<sup>[8]</sup>

## CONCLUSION

Plain radiography is quite reliable and easily reproducible investigation for Risser's staging in apophyseal ossification.

There are many limitations because of apophyseal excursions. This may lead to the error of measuring the apophyseal length, ossification and fusion. Modified Rigger's staging is quite accurate and can be used as a tool for the skeletal maturity and predicting for the scoliosis of the spine.

### Acknowledgement

We are thankful to Mr Nitish, Mr Rajdeep Thidwar, Miss Nitika and Mrs Anuradha for carrying out the radiography of the patients and providing all the appropriate images.

## REFERENCES

1. Reem J, Carmey J, Stanley M, Cassidy J. Risser sign inter-rater and intra-rater agreement: is the Risser sign reliable? *Skeletal Radiol.* 2009 Apr; 38 (4):371-5.
2. Izumi Y. *Spine (Phila Pa 1976)*. 1995 Sep 1; 20(17):1868-71.
3. Little DG, Sussman MD. The Risser Sign: a critical analysis. *J Pediatr Orthop.* 1994; 14:569-575.
4. Torlak G, Kiter E, Oto M, Akman A. Ultrasonographic evaluation of the Risser sign. *Spine (Phila Pa 1976)* 2012; 37:316-320.
5. Kotwicki T. Risser sign: the value of the lateral spinal radiograph to assess the excursion of the iliac apophysis. *Stud Health Technol Inform.* 2008; 140:44-47.
6. Kotwicki T. Improved accuracy in Risser sign grading with lateral spinal radiography. *Eur Spine J.* 2008; 17:1676-1685.
7. Thaler M, Kaufmann G, Steingruber I, Mayr E, Leibensteiner M, Bach C. Radiographic versus ultrasound evaluation of the Risser Grade in adolescent idiopathic scoliosis: a prospective study of 46 patients. *Eur Spine J.* 2008 Sep; 17(9):1251-5.
8. Sanders JO, Khoury JG, Kishan S, Browne RH, Mooney JF, Arnold KD, McConnell SJ, Bauman JA, Finegold DN. Predicting scoliosis progression from skeletal maturity: a simplified classification during adolescence. *J Bone Joint Surg Am.* 2008; 90:540-553

**How to cite this article:** Kapur N, Sharma S, Sharma BB, Chauhan SS, Aziz MR, Jha DK. Evaluation of Ossification of Iliac Crest in Children as Per Risser's Sign in Gurugram Region of Haryana. *Ann. Int. Med. Den. Res.* 2018; 4(6):RD08-RD10.

**Source of Support:** Nil, **Conflict of Interest:** None declared