

Histopathological and Endoscopic Correlation of Gastric Lesions in Endoscopic Gastric Biopsies.

Amoledeep Kaur Bhatti¹, Harpal Singh², Ashish Kumar³, Ramesh Kumar Kundal⁴, Prabhjot Kaur¹

¹Junior resident Department of Pathology, Government Medical College, Patiala, Punjab, India.

²Associate Professor, Department of Pathology, Government Medical College, Patiala, Punjab, India.

³Assistant Professor, Department of Medicine, Government Medical College, Patiala, Punjab, India.

⁴Professor and Head of department, Department of Pathology, Government Medical College, Patiala, Punjab, India.

Received: March 2018

Accepted: March 2018

Copyright: © the author(s), publisher. It is an open-access article distributed under the terms of the Creative Commons Attribution Non-Commercial License, which permits unrestricted non-commercial use, distribution, and reproduction in any medium, provided the original work is properly cited.

ABSTRACT

Background: There are a number of lesions that could affect the stomach varying from dyspepsia to highly lethal cancers; that can be chronic and incapacitating or merely an occasional discomfort or asymptomatic. Objective: The study was done to establish a correlation between endoscopic findings and histopathological characteristics of the various pathological gastric lesions. **Methods:** The study was a prospective study and done on 150 affected patients in 2 years. The endoscopic biopsy was taken from number of points of suspicious lesion for histopathologic diagnosis of the type of gastric lesions. The biopsies were fixed in formalin and adequately processed. The sections were stained with routine Haematoxylin and Eosin stain. Giemsa staining for H.pylori was also done. **Results:** In this study the most common clinical indications for endoscopic biopsy were pain epigastrium (82.0%) and dyspepsia (67.3%) with mean age of 54.25 and male predominance (1.9:1). The various gastric lesions were chronic gastritis (66.0%), adenocarcinoma (8.0%), no specific diagnosis (8.0%), dysplasia (4.7%), hyperplastic polyp (4.7%), acute on chronic gastritis (3.3%), eosinophilic gastritis (2.0%), acute gastritis (1.3%), intestinal metaplasia (1.3%) and chronic atrophic gastritis (0.7%). **Conclusion:** H. pylori is most commonly associated with acute on chronic gastritis.

Keywords: Gastric lesions, Endoscopy, H & E staining & Giemsa staining.

INTRODUCTION

Upper GI Endoscopy permits biopsy and endoscopic therapy. It also provides an excellent opportunity to improve correlation of histological features and gross features of disease in both early and advanced phases so that early therapeutic decisions can be taken allowing improved prognosis. The various gastric lesions include inflammatory, non-neoplastic and neoplastic lesions. The various inflammatory lesions are acute gastritis, chronic gastritis, peptic ulcer disease, autoimmune gastritis, eosinophilic gastritis, lymphocytic gastritis, granulomatous gastritis and intestinal metaplasia. Neoplastic and non-neoplastic proliferations include menetrier disease, Zollinger-Ellison syndrome, hypertrophic pyloric stenosis, portal hypertensive gastropathy, inflammatory and hyperplastic polyps, fundic gastric polyps, gastric adenomas, gastric adenocarcinomas, primary gastric lymphomas, carcinoid tumors, gastrointestinal stromal tumor.^[1]

MATERIALS AND METHODS

A sample size of 150 patients was taken in the present study and correlation was established between endoscopic findings of the patient and the histopathological diagnosis of endoscopy guided biopsy taken from the suspicious lesions. Once paper mounted gastric biopsies were taken from the suspicious lesions in the endoscopy ward, Rajindra Hospital, Patiala by an expert, they were placed in 10% formalin and received by the Department of Pathology for histopathological diagnosis. Then, after grossing and processing biopsies in histokinette, FFPE (formalin-fixed, paraffin embedded) blocks were made. 4 µm sections were cut from the FFPE blocks on the microtome and stained with routine Haematoxylin and Eosin Stain. Giemsa staining was done for H. pylori. Data for patient's age, gender, site of biopsy (cardia, fundus, corpus or body and pylorus of stomach), endoscopic appearance (erythema, ulceration, nodular and erosions) were analysed. Frequency of various gastric lesions both benign and malignant was calculated in the study group. Finally correlations were established between age, gender, endoscopic findings and final histopathological diagnosis of various gastric lesions.

Name & Address of Corresponding Author

Dr. Harpal Singh Seemar,
Associate Prof. Pathology,
#835/13 Ghuman Nagar A,
Sirhind Road Patiala 147001,
Punjab, (India).

Chi-square test was used to determine the statistical significance between endoscopic findings and histopathological findings. A p-value of <0.05 was considered statistically significant. All p-values calculated were two sided.

RESULTS

It was found that in all age groups, male patients were more than females and the maximum number of patients were in the age group of 51-60 years [Figure 1]

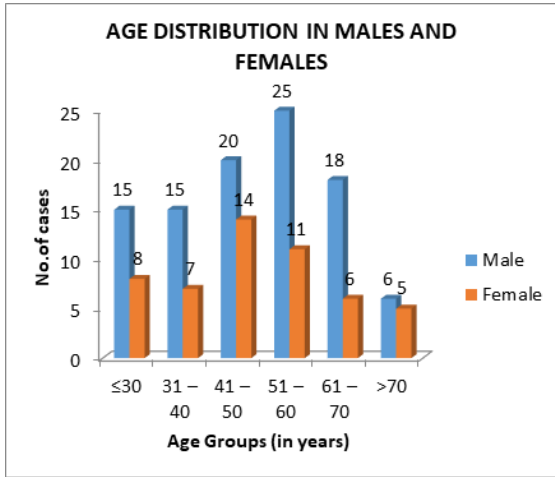


Figure 1: Age distribution in males and females.

Out of 150 cases reviewed, there were 99 (66.0%) cases of chronic gastritis, 12 (8.0%) cases of adenocarcinoma, 12 (8.0%) cases with no specific diagnosis, 7 (4.7%) cases of hyperplastic polyp, 7 (4.7%) cases of dysplasia, 5 (3.3%) cases of acute on chronic gastritis, 3 (2.0%) cases of eosinophilic gastritis, 2 (1.3%) cases of acute gastritis, 2 (1.3%) cases of intestinal metaplasia and 1 (0.7%) case of chronic atrophic gastritis [Figure 2]

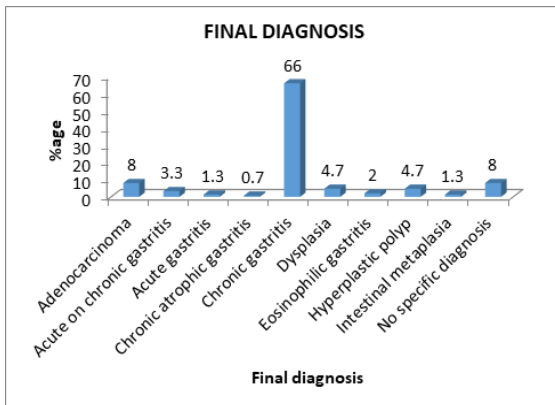


Figure 2: Various histopathological diagnosis

The common clinical features in patients with gastric lesions were pain epigastrium present in 123 (82%) and dyspepsia present in 101 (67.3%) patients. Dyspepsia was present in 11 out of 12 cases of

adenocarcinoma and 36 out of 63 case of chronic gastritis. Hence dyspepsia has a significant correlation with adenocarcinoma and chronic gastritis (p-value < 0.05).

Tobacco, alcohol, NSAIDs and hot tea intake were found in significant number of cases with gastric lesions particularly adenocarcinoma and chronic gastritis.

Most common site of gastric lesions was found to be antrum (62.7%) followed by body (46.7%), fundus (11.3%) and cardia (3.3%).

Various endoscopic appearances of gastric lesions found were erythema 68 (45.3%), erosions 59 (39.3%), nodule 39 (26%), ulcer 20 (13.3%) and PHG 12 (8%). There was a highly significant correlation between erythema and final histopathological diagnosis (<0.001); between erosions and final histopathological diagnosis (<0.05); between nodule and final histopathological diagnosis (<0.001)

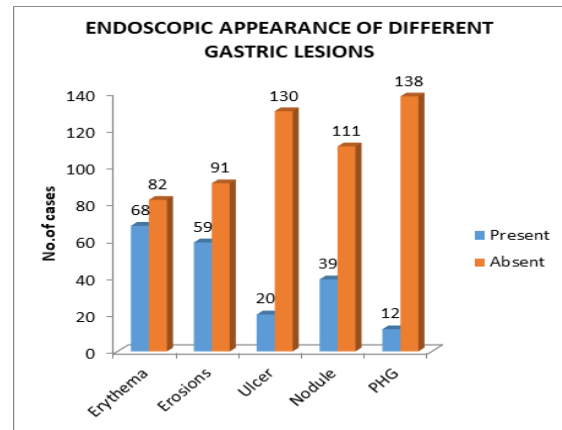


Figure 3: Endoscopic appearance of different gastric lesions

Table 1: Endoscopic appearance in different histopathological diagnosis

Final Diagnosis	Erythema	Erosions	Ulcer	Nodule	PHG
Adenocarcinoma	8.3%	8.3%	25.0%	91.7%	0.0%
Acute on chronic gastritis	80.0%	20.0%	40.0%	0.0%	0.0%
Acute gastritis	100.0%	50.0%	50.0%	0.0%	0.0%
Chronic atrophic gastritis	100.0%	0.0%	0.0%	0.0%	0.0%
Chronic gastritis	51.5%	49.5%	12.1%	13.3%	10.1%
Dysplasia	0.0%	28.6%	14.3%	71.4%	14.3%
Eosinophilic gastritis	33.3%	33.3%	0.0%	0.0%	33.3%
Hyperplastic polyp	0.0%	0.0%	0.0%	100.0%	0.0%
Intestinal metaplasia	50.0%	50.0%	0.0%	50.0%	0.0%
No specific diagnosis	58.3%	25.0%	8.3%	16.6%	0.0%

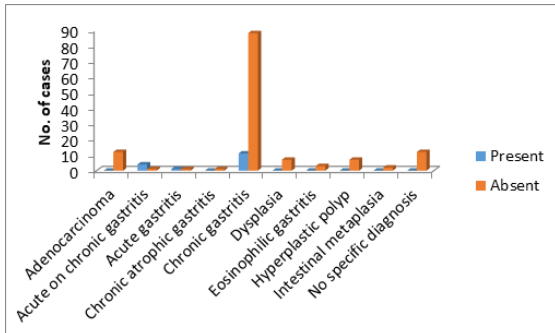


Figure 4: H. pylori in different histopathological diagnosis.

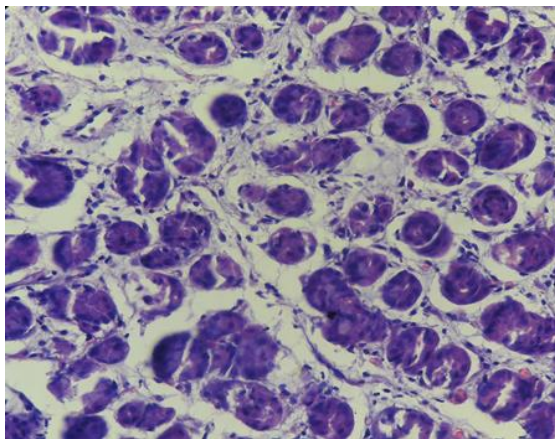


Figure 5: Photomicrograph showing chronic gastritis. (H&E- 400x).

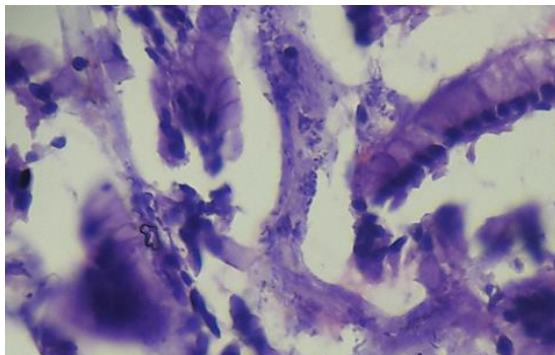


Figure 6: Photomicrograph showing H.pylori. (H&E- 400x).

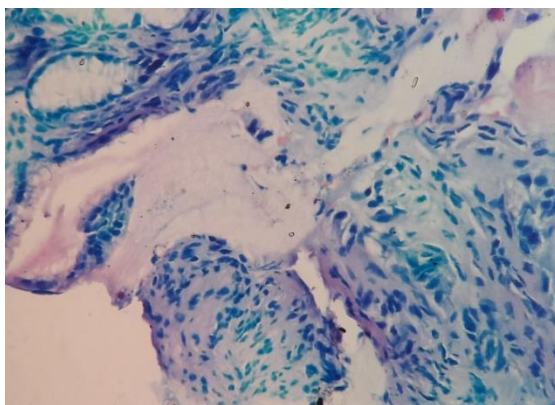


Figure 7: Photomicrograph showing H. pylori. (Giemsa- 400x).

Histopathologically, chronic gastritis was the most common gastric lesion found in 99 (66%) of 150 endoscopic gastric biopsies. Adenocarcinoma was the second most common gastric lesion found in 12 (8%) cases. H. pylori was found in 16 (10.7%) cases, most commonly associated with acute on chronic gastritis. There was a highly significant correlation between H. pylori and final histopathological diagnosis (<0.001). [Figure 4]

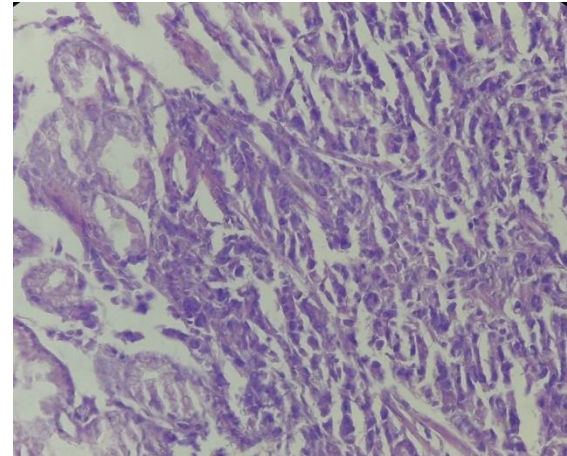


Figure 8: Photomicrograph showing adenocarcinoma. (H&E- 400x).

DISCUSSION

The average age for chronic gastritis in the present study was 49.53 years. This figure is comparable to that of the average age studied by various authors in other similar studies as shown in [Table 2]. According to Ddine et al,^[2] Joo et al and Du et al,^[3,4] the average age was 49.4, 48 and 48.7 years, respectively.

Table 2: Age Distribution For Chronic Gastritis

Author and year of Study	Average Age
Ddine et al[2] (2012)	48
Joo et al[3](2013)	48.7
Du et al[4](2014)	49.4
Present study (2017)	49.53

The average age for the carcinoma of stomach in the present study was 54.25 years. This figure is comparable to that of the average age studied by various authors in other similar studies as shown in [Table 3].

Table 3: Age Distribution For Gastric Cancer

Author and year of Study	Average Age
Cherian et al [5] (2007)	>40
Sharma and Radhakrishnan[6] (2011)	58
Lakshmi et al[7](2017)	50
Present study (2017)	54.25

Of the 150 patients with gastric biopsies, 34.0% were females and 66.6% were males. Male: female ratio was 1.9:1. This was also proved by another study done by Gabriel et al,^[8] in which the ratio was

2.8:1. According to P. Sharma et al,^[9] the ratio was 1.86:1. According to S. Sharma et al,^[10] the ratio was 1.3:1. This gender ratio favoring males could be reflective of the fact that males are exposed to more risk factors than females or due to large number of male patients attending outpatient department of the hospital as compared to female patients. [Table 4]

Table 4: Gender Distribution

Author and year of Study	M:F (ratio)
Gabriel et al [8] (2010)	2.8:1
P. Sharma et al[9] (2015)	1.86:1
S. Sharma et al[10](2015)	1.3:1
Present study (2017)	1.9:1

In the present study, the most common chief complaints were pain epigastrium (82%), dyspepsia (67.3%), regurgitation (55.3%) and hematemesis (52%).

There is a significant correlation between dyspepsia and final histopathological diagnosis ($p < 0.05$). According to Hussain et al,^[11] dyspepsia was present in 37.9% patients. According to Shanmugasamy et al,^[12] dyspepsia was present in 39% patients. [Table 5]

Table 5: Dyspepsia

Author and year of study	Dyspepsia
Hussain et al[11] (2015)	37.9%
Shanmugasamy et al[12] (2016)	39%
Present study (2017)	67.3%

In a study conducted by Silvoso,^[13] erythema was present in 76%, erosions in 40% and ulcer in 17%. According to Sharma et al,^[10] erythema was present in 10%, erosions in 24%, ulcer in 32% and nodule in 34% of patients.

In the present study, erythema was present in 45.3%, erosions in 39.3%, nodule in 26.0% and ulcer in 13.3%. [Table 6]. Out of 12 patients with adenocarcinoma, nodule was present in 11 patients. Along with nodule, some patients with adenocarcinoma also presented with ulcers. Patients with chronic gastritis mainly presented with erythema along with erosions. Hence, it was concluded that all endoscopically diagnosed gastric lesions should be subjected for histopathological confirmation.

Table 6: Endoscopic Appearance Of Various Lesions In Stomach

Author and year of study	Erythema	Erosions	Ulcer	Nodule
Silvoso[13] (1979)	76.0%	40.0%	17.0%	-
Sharma et al[10] (2015)	10.0%	24.0%	32.0%	34.0%
Present study (2017)	45.3%	39.3%	13.3%	26.0%

In the present study, various benign lesions were present in 86% and premalignant and malignant

lesions were present in 14%. Similar findings were present in other study conducted by Poudel et al,^[14] in which benign lesions were present in 90.7% and premalignant and malignant lesions were present in 9.3% patients. According to Pailoor et al,^[15] benign lesions were present in 44% and premalignant and malignant lesions were found in 56%. According to Mahmuda et al,^[16] benign lesions were present in 56% and premalignant and malignant lesions were found in 44%. [Table 7]

Table 7: Final Histopathological Diagnosis

Author and year of study	Benign	Premalignant and Malignant
Poudel et al[14] (2013)	90.7%	9.3%
Pailoor et al [15] (2013)	44.0%	56.0%
Mahmuda et al[16] (2016)	56.0%	44.0%
Present study (2017)	86.0%	14.0%

In the present study, H. pylori was present in 10.7% patients. The reason for such a low prevalence is that most of the patients were referred from other physicians and were already on proton pump inhibitors.

Marshall and Warren,^[17] identified H. pylori in 11% patients. According to Wright et al,^[18] H. pylori was present in 8.3% patients. According to Franklin et al,^[19] H. pylori was present in 11.4% patients. [Table 8]

Table 8: H. Pylori In Final Histopathological Diagnosis

Author and year of study	H. pylori
Marshall and Warren [17] (1984)	11.0%
Wright et al [18] (2006)	8.3%
Franklin et al[19] (2015)	11.4%
Present study (2017)	10.7%

CONCLUSION

It was concluded that chronic gastritis was the most common gastric lesion, being more common in men in the age group (41-50 years) and adenocarcinoma was histopathologically the commonest gastric malignancy in our region, being more common in men in the old age group (61-70 years). Pain epigastrium and dyspepsia are common presenting complaints in various gastric lesions and all cases with dyspepsia and pain epigastrium should be further investigated using endoscopy followed by histopathological confirmation. H. pylori is most commonly associated with acute on chronic gastritis.

REFERENCES

1. Kumar, Abbas, Aster. The Gastrointestinal Tract- Stomach. Robbins and Cotran Pathologic Basis of Disease – South Asia edition 2015; 2:760-77.
2. Ddine LC, Ddine CC, Rodrigues CC, Kirsten VR, Colpo E. Factors associated with chronic gastritis in patients with

- presence and absence of *Helicobacter pylori*. *Arquivos Brasileiros de Cirurgia Digestiva* 2012;25(2):96-100.
- Joo YE, Park HK, Myung DS, Baik GH, Shin JE, Seo GS, et al. Prevalence and Risk Factors of Atrophic Gastritis and Intestinal Metaplasia: A Nationwide Multicenter Prospective Study in Korea. *Gut and Liver* 2013; 7(3): 303.
 - Du Y, Bai Y, Xie P, Fang J, Wang X, Hou X, et al. Chronic gastritis in China: a national multi-center survey. *BMC Gastroenterology* 2014;14(1):21.
 - Cherian JY, Sivaraman R, Muthusamy AK, Venkataraman J. Stomach carcinoma in the Indian subcontinent: A 16-year trend. *The Saudi Journal of Gastroenterology* 2007;13(3):114-7.
 - Sharma A, Radhakrishnan V. Gastric cancer in India. *Indian Journal of Medical and Paediatric Oncology* 2011;32(1):12-6.
 - Sushma J, Kartheek BV, Lakshmi AB. Clinicopathological study of carcinoma stomach over a period of 5 years. *International Journal of Research in Medical Sciences* 2017;5(2):558-62
 - Gabriel AM, Hernández I, Mengual E, Fuenmayor A, Romero G, Lizarzabal M. Comparison of three methods based on endoscopic gastric biopsies for diagnosis of *Helicobacter pylori* active infection in a clinical setting. *Arquivos de Gastroenterologia* 2010; 48(3):190-4.
 - Sharma P, Kaul KK, Mahajan M, Gupta P. Histopathological Spectrum of various gastroduodenal lesions in North India and prevalence of *Helicobacter pylori* infection in these lesions: a prospective study. *International Journal of Research in Medical Sciences* 2015;3(5): 1236-41.
 - Sharma S, Makaju R, Dhakal R, Purbey B, Gurung RB, Shrestha R. Correlation between Endoscopic and Histopathological Findings in Gastric Lesions. *Kathmandu University Medical Journal* 2015;13 (51): 216-9.
 - Hussain SI, Reshi R, Akhter G, Beigh A. Clinicopathological study of upper gastrointestinal tract endoscopic biopsies. *International Journal of Current Research and Review* 2015; 7(16): 78.
 - Shanmugasamy K, Bhavani K, Narashiman R, Kotasthane DS. Clinical Correlation of Upper Gastrointestinal Endoscopic Biopsies with Histopathological Findings and To Study the Histopathological Profile of Various Neoplastic and Non-Neoplastic Lesions. *Journal of Pharmaceutical and Biomedical Sciences* 2016; 6(3):220-4.
 - Silvoso GR, Ivey KJ, Butt JH, Lockard OO, Holt SD, Sisk C, et al. Incidence of gastric lesions in patients with rheumatic disease on chronic aspirin therapy. *Ann Intern Med* 1979; 91(4):517-20.
 - Poudel A, Regmi S, Poudel S, Joshi P. Correlation between endoscopic and histopathological findings in gastric lesions. *Journal of Universal College of Medical Sciences* 2013;1(3):37-41
 - Pailoor K, Sarpangala MK, Naik RC. Histopathological diagnosis of gastric biopsies in correlation with endoscopy—a study in a tertiary care centre. *Advance Laboratory Medicine International* 2013; 3(2): 22-31
 - Mahmuda S, Bashir MF, Yesmin N, Khatun MA. Correlation between Histopathological and Endoscopic Findings of Stomach Growth. *Mymensingh medical journal* 2016;25(1):138-40.
 - Marshall BJ, Warren JR. Unidentified curved bacilli in the stomach of patients with gastritis and peptic ulceration. *Lancet* 1984; 323(8390):1311-5.
 - Wright CL, Kelly JK. The use of routine special stains for upper gastrointestinal biopsies. *The American Journal of Surgical Pathology* 2006;30(3):357-61.
 - Franklin AL, Koeck ES, Hamrick MC, Qureshi FG, Nadler EP. Prevalence of Chronic Gastritis or *Helicobacter pylori* Infection in Adolescent Sleeve Gastrectomy Patients Does

Not Correlate with Symptoms or Surgical Outcomes. *Surgical infections* 2015;16(4):401-4.

How to cite this article: Bhatti AK, Singh H, Kumar A, Kundal RK, Kaur P. Histopathological and Endoscopic Correlation of Gastric Lesions in Endoscopic Gastric Biopsies. *Ann. Int. Med. Den. Res.* 2018; 4(3): PT13-PT17.

Source of Support: Nil, **Conflict of Interest:** None declared