

The Diagnosis and Treatment of Benign Paroxysmal Positional Vertigo through Particle Repositioning Manoeuvre: An Observational and Prospective Study

Deepthi Balakrishnan¹, Divya Anirudhan²

¹Consultant in Physical Medicine and Rehabilitation District Hospital Mananthavady, Wayanad, Kerala.

²Assistant Professor in Physical Medicine and Rehabilitation Govt. Medical College, Thrissur, Kerala.

Received: June 2018

Accepted: July 2018

Copyright: © the author(s), publisher. It is an open-access article distributed under the terms of the Creative Commons Attribution Non-Commercial License, which permits unrestricted non-commercial use, distribution, and reproduction in any medium, provided the original work is properly cited.

ABSTRACT

Background: Benign paroxysmal positional vertigo (BPPV) can be defined as a transient position induced torsional vertical or horizontal nystagmus with vertigo. Findings such as latency, reversibility, crescendo, transience and fatigability are often pre-set and support this diagnosis. This study is done to prove the efficacy of Particle Repositioning manoeuvre (PRM) in Benign Paroxysmal positional by evaluating the changes in vertigo scales before and after the PRM. This study also focusses to evaluate changes in Symptom status before and after the particle repositioning maneuver. **Methods:** The prospective Hospital based study was done in the Department of Physical Medicine and Rehabilitation, Medical College, Thiruvananthapuram for the period of 2 years on 35 subjects of either gender above 18 years with vertigo presenting to the outpatient clinics. Vertigo scale evaluation was done prior to the manoeuvre and at 7 days, 4 weeks and 6 months after the Particle Repositioning manoeuvre. **Results:** Particle Repositioning Maneuver resulted in reversal of vertigo and associated disability. Vertigo scales showed marked improvement. Recurrence of vertigo following Particle Repositioning Maneuver can be successfully treated by repeating the maneuver, which is easy to perform, simple and cost effective. No statistically significant association was found between idiopathic Benign Paroxysmal Positional Vertigo and conditions like neck pain, trigger points and x-ray evidence of cervical spondylosis in this study. **Conclusion:** This study establishes the efficacy of Particle Repositioning Maneuver in the management of Benign Paroxysmal Positional Vertigo.

Keywords: Particle repositioning manoeuvre, benign paroxysmal positional vertigo, vertigo scale.

INTRODUCTION

Benign paroxysmal positional vertigo (BPPV) can be defined as a transient position induced torsional vertical or horizontal nystagmus with vertigo. Findings such as latency, reversibility, crescendo, transience and fatigability are often pre-set and support this diagnosis.^[1]

Definitions of findings supporting the diagnosis of BPPV.^[2-5]

Latency: a brief period of 1-5 seconds between assuming provocative head position and onset of nystagmus and vertigo.

Reversibility: Nystagmus reverses direction when head is returned to the erect position.

Crescendo: Nystagmus intensity increases quickly to a peak and then slowly subsides.

Name & Address of Corresponding Author

Dr. Divya Anirudhan,
Assistant Professor in Physical Medicine and Rehabilitation
Govt. Medical College,
Thrissur, Kerala.

Transience: Nystagmus and vertigo subside within 5-30 seconds.

Fatigability: With repeated head positioning, nystagmus and vertigo are no longer elicited.

Alder first described paroxysmal vertigo in 1897. Dix and Hallpike coined the descriptive term "benign paroxysmal positional vertigo". Dix and Hallpike also described a method of maximally provoking the attack by moving the patient rapidly from a sitting position to a position of head hanging with one ear downward.^[3]

Since that time, numerous studies and reports of positional vertigo and nystagmus have been offered and a variety of aetiologies have been suggested. These include the following.^[6-9]

- **Cerebellar:** Reisco-Mac Clure postulated that cerebellar inhibition of the vestibular system was destroyed in a patient with brainstem glioma. This theory was further supported by Fernandez who removed the nodules of cerebellum in cats and produced positional nystagmus.
- **Cervical:** Cope and Ryan postulated that cervical spondylosis and trauma produced abnormal proprioceptive information to the brain.
- **Vascular:** Sanstrom suggested that vertebral artery compression by osteophytes produced brain ischemia which caused torsional nystagmus.

Balakrishnan & Anirudhan; Diagnosis and Treatment of Benign Paroxysmal Positional Vertigo

- Labyrinthine: Schuknecht coined the term cupulo-lithiasis and documented basophilic deposits on the cupula of the posterior semicircular canal. He theorized that displaced otoconia with a specific gravity greater than endolymph collect in the posterior semicircular canal ampulla rendering it gravity sensitive. Certain head movements may then produce inappropriate endolymph/cupula displacement, causing nystagmus and a sense of rotation. Hall et al proposed that free floating debris within the posterior semicircular canal would result in BPPV and would better explain the phenomenon of fatigability which occurs when this debris becomes dispersed or trapped within another part of the labyrinth.

The most accepted of the above possible aetiologies in BPPV is the labyrinthine origin for this disorder, with free floating debris in the semicircular canal (canalithiasis) probably occurring more frequently than cupulo-lithiasis. Relief of showing labyrinthectomy, vestibular neurectomy, singular neurectomy and posterior semicircular canal occlusion further support a labyrinthine site of this disease process.^[10-13]

Treatment successes based on repositions on free floating debris also support this conclusion. The “canalith repositioning procedure” (CRP), a series of head manoeuvres is thought to induce the displacement of canalith through the non ampulated end of the canal into the utricle where they no longer produce positional nystagmus or vertigo.^[14,15]

This study is done to prove the efficacy of Particle Repositioning manoeuvre (PRM) in Benign Paroxysmal positional by evaluating the changes in vertigo scales before and after the PRM. This study also focusses to evaluate changes in Symptom status before and after the particle repositioning maneuver.

MATERIAL AND METHODS

The prospective Hospital based study was done in the Department of Physical Medicine and Rehabilitation, Medical College, Thiruvananthapuram for the period of 2 years from January 2006 to December 2007.

35 subjects of either gender above 18 years with vertigo presenting to the outpatient clinics were included in the study.

Inclusion Criteria

- Age – 18 years or older.
- History consistent with the diagnosis of BPPV.
- Rotatory vertigo lasting less than 30 seconds
- Precipitated by head movements
- Positive Dix – Hallpike test showed either nystagmus or reproduction of symptoms while in the head dependent position.

Exclusion criteria

- Evidence of ongoing central nervous system disease
- Unstable Heart disease
- Severe cervical spondylosis
- Alternative diagnosis of peripheral vertigo

Procedure for the study group

The diagnosis of BPPV and the identification of the offending ear were established by the Dix – Hallpike test .The patient was seated on the examination table close enough to the end so that the neck may be extended over the edge of the table when the patient becomes supine.

Position 1: The patient was seated and subsequently placed into supine position with the head rotated 45 degrees from the vertical plane toward the affected ear. The head was allowed to subtend an angle of 30 degrees to the horizontal plane. Various characteristics of nystagmus (latency, duration, type and direction) and vertigo were recorded.

Position 2: The head was turned by 90 degrees toward the contralateral side from the position 1 (ie, 45 degrees to the vertical plane towards the opposite ear)

Position 3: Later on, the head was rotated by a further 90 degrees in the same direction. To ease the head movement, the body was rotated by 90 degrees towards the opposite ear, thus making the head to attain 135 degrees from supine position.

Position 4: The patient was brought back to sitting position with the head in the same position as in position 3.

Position 5: The patient’s head was later turned by 45 degrees to bring it in line with the rest of the body.

In each position, the patient was allowed to rest for 2 minutes after the cessation of nystagmus.

Post procedural Instructions

All patients who had undergone PRM were asked to sleep in an upright position with the head elevated at an angle no less than 45 degrees from the bed for the next 48 hours. A rigid two piece cervical collar was given for 48 hours to ensure an upright position. The patients were allowed to resume normal activities after 2 days.

Follow up

The period of follow up for all cases was for 6 months. Patients were reviewed after one week, four weeks and 6 months after the procedure. At each visit the Dix-Hallpike manoeuvre was repeated and the symptomatic status revised.

Investigations

Routine blood examination, fasting blood sugar, supine blood pressure, X-ray cervical spine.

Balakrishnan & Anirudhan; Diagnosis and Treatment of Benign Paroxysmal Positional Vertigo

Assessment

The difference in vertigo scores before and after Particle repositioning maneuver was assessed by patients on a previously described one to ten point numerical analog scale.^[10]

RESULTS

Table 1: Symptom Status in the first week after the Particle Repositioning Maneuver (PRM) in patients with Idiopathic benign paroxysmal positional vertigo and benign paroxysmal positional vertigo with other associated conditions

Symptom status	Idiopathic BPPV	BPPV with other associations	Total
Gr. 1	26	6	32
others	2	1	3
Total	28	7	35

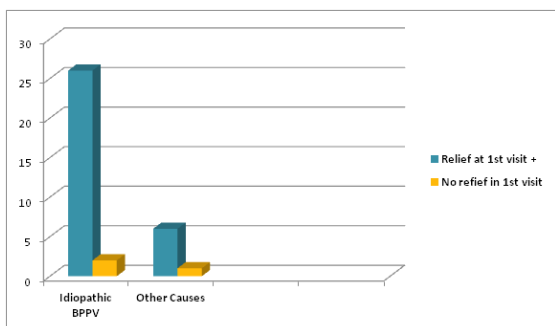


Figure 1: Symptom Status in the first week after the Particle Repositioning Maneuver (PRM).

Chi Square: 0.02; p value: 0.88

Of the total 35 patients studied, there were 28 (80 percentage) cases of idiopathic benign paroxysmal positional vertigo and 7 (20 percentage) cases of benign paroxysmal positional vertigo with other associations. 26 patients (92 percentage) with idiopathic benign paroxysmal positional vertigo showed complete resolution of symptoms (grade 1 symptomatic scale) at the end of one week while 6 (85 percentage) out of 7 cases of benign paroxysmal positional vertigo with other associations showed similar results.

Of the 2 cases of idiopathic benign paroxysmal positional vertigo who did not have complete relief of symptoms at one week, one was a case of bilateral benign paroxysmal positional vertigo, he had complete relief of symptoms after repeating the maneuver. The other person, though the Hallpike test was negative, continued to have minimal symptoms even after repeating the maneuver. He most likely had associated psychogenic vertigo. PRM was repeated in the second visit only for those who did not have complete relief of symptoms.

After the second maneuver, two patients had complete relief of symptoms while one patient continued to have Grade 2 symptoms. At the end of 6 months, one person (3 percentage) had

recurrence of symptoms (grade 3 symptom status) and one patient continued to have partial symptoms [Table 1, Figure 1].

Table 2: Neck Pain and BPPV

Neck Pain	Idiopathic BPPV	Others	Total
Present	10	2	12
Absent	18	5	23
Total	28	7	35

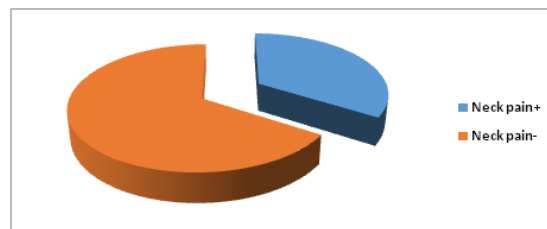


Figure 2: Neck Pain and BPPV.

p value – 0.54, chi square – 0.13

Of the total 35 patients studied, 12 patients (34 percentage) had pain in the neck while 23 (66 percentage) of them did not have similar symptoms. Of the 28 with idiopathic benign paroxysmal positional vertigo, 10 had neck pain (35 percentage) and of the 7 with benign paroxysmal positional vertigo of other causes, two had neck pain (28 percentage). There was no statistically significant association between neck pain and idiopathic benign paroxysmal positional vertigo in this study [Table 2, Figure 2].

Table 3: Cervical Spondylosis and BPPV.

Cervical Spondylosis	Idiopathic BPPV	Others	Total
Present	22	5	27
Absent	6	2	8
Total	28	7	35

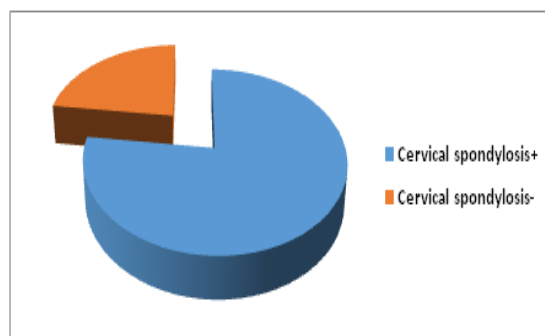


Figure 3: Cervical Spondylosis and BPPV.

p value – 0.26, chi square – 1.26

27 patients out of 35 had Cervical Spondylosis (77 percentage) while 8 (23 percentage) did not have Cervical Spondylosis on X-Ray. Of the 28 with idiopathic benign paroxysmal positional vertigo, 22 had Cervical Spondylosis (78 percentage) and of the 7 with benign paroxysmal positional vertigo of other causes, 5 had Cervical Spondylosis (72 percentage). There was no statistically significant

Balakrishnan & Anirudhan; Diagnosis and Treatment of Benign Paroxysmal Positional Vertigo

association between Cervical Spondylosis and idiopathic benign paroxysmal positional vertigo in this study [Table 3, Figure 3].

Table 4: Trigger Points and BPPV.

Trigger Points	Idiopathic BPPV	Others	Total
Present	12	1	13
Absent	16	6	22
Total	28	7	35

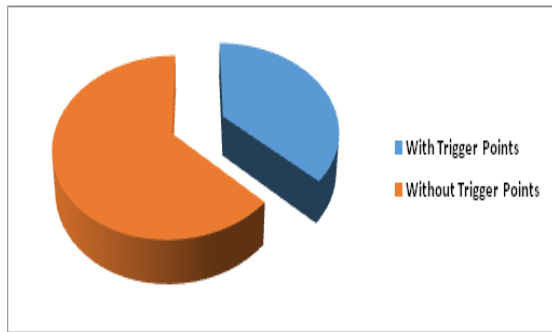


Figure 4: Trigger Points and BPPV

p value – 0.16, chi square – 1.96

13 patients out of 35 (37.1 percentage) had trigger points while 22 (62.8 percentage) did not have trigger points. Of the 28 with idiopathic benign paroxysmal positional vertigo, 12 had trigger points (42 percentage) and of the 7 with benign paroxysmal positional vertigo of other causes, one had trigger points. No statistically significant

association was found between trigger points and idiopathic benign paroxysmal positional vertigo in this study [Table 4, Figure 4].

Table 5: Nystagmus and BPPV.

Nystagmus	Idiopathic BPPV	Others	Total
Present	22	6	28
Absent	6	1	7
Total	28	7	35

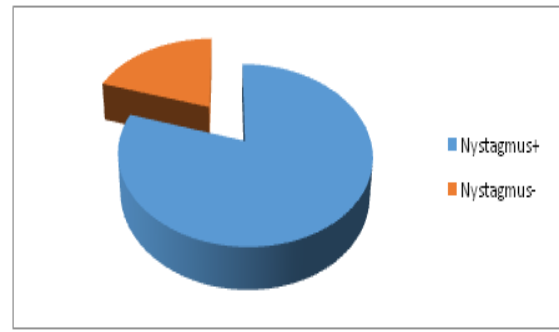


Figure 5: Nystagmus and BPPV.

p value – 0.67, chi square – 0.1

28 (80%) patients out of 35 had nystagmus while 7 (20%) did not have nystagmus. Latency of nystagmus was below ten seconds on subjecting to Dix Hallpike Maneuver in all subjects. All cases showed duration of nystagmus and vertigo lasting for less than half a minute [Table 5, Figure 5].

Table 6: Vertigo scales during follow up.

Before PRM	8	8	9	7	8	9	8	8	9	8	9	8	8	9	8	9	8	8	8	8	7	9	8	8	8	9	9	8	8	9	8	8	9	8	8
1 week after PRM	1	4	1	1	1	1	1	1	3	1	1	1	1	1	1	1	1	1	1	1	1	3	1	1	1	1	1	1	1	1	1	1	1	1	1
4 weeks after PRM	1	2	1	1	1	1	1	1	1	1	1	1	1	1	1	1	1	1	1	1	1	1	1	1	1	1	1	1	1	1	1	1	1	1	1
6 months after PRM	1	2	7	1	1	1	1	1	1	1	1	1	1	1	1	1	1	1	1	1	1	1	1	1	1	1	1	1	1	1	1	1	1	1	1

Efficacy of the PRM at first week - vertigo scales

At the end of first week t – 52.79; p value < 0.001. Paired t test was used to evaluate the changes in the

Balakrishnan & Anirudhan; Diagnosis and Treatment of Benign Paroxysmal Positional Vertigo

vertigo scales before the particle repositioning maneuver and at one week after the maneuver.

At the first visit, 11 patients (31.4 percentage) had a vertigo score of 9; 22 patients (62.8 percentage) had vertigo score of 8 and two patient (5.7 percentage) had score 7.

At the end of one week after the maneuver, 32 patients (91 percentage) had vertigo score of 1; two patients (5.7 percentage) had score of 3 and one patient (3 percentage) had score 4.

At the end of four weeks after the PRM, 34 patients (97 percentage) had score of one, only one patient (3 percentage) continued to have vertigo score of 2. This person continued to have vertigo score of 2 at six months also. One person had recurrence on follow up at 6 months with a vertigo scale of 7; on repeating PRM, he had complete symptom relief (Vertigo scale 1). Paired t test was used to evaluate the changes in vertigo the PRM and at one week after PRM, $t = 52.79$; p value - <0.001 . Thus, PRM resulted in statistically significant change in vertigo score [Table 6, Figure 6].

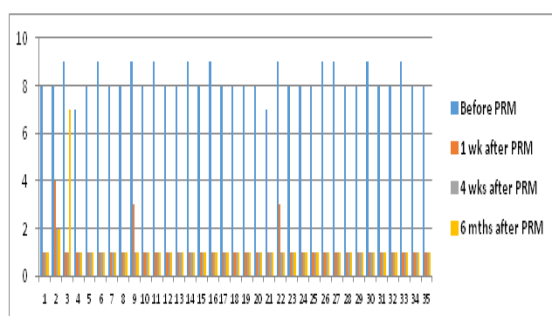


Figure 6: Efficacy of PRM at first week, 4 weeks and 6 months – Vertigo scale.

DISCUSSION

The association of BPPV with head trauma prior ear surgery, vestibular neuronitis, and migraine have previously been reported. Harada Y reported that 15 percent cases of benign paroxysmal positional vertigo followed neuro-labyrinthitis and 18 percent followed head trauma.^[16]

In a cross-sectional, nationally representative neurotological survey of the general adult population in Germany with a two stage sampling design: screening of 4869 participants from the German National Telephone Health Interview Survey 2003 (GNT-HIS) for moderate or severe dizziness or vertigo followed by validated neurotological interviews (n=1003; response rate 87%). BPPV accounted for 8% individuals with moderate or severe dizziness/vertigo. In 86% of affected individuals BPPV led to medical consultation, interruption of daily activities or sick leave. In total, only 8% of affected participants received effective treatment. On multivariate analysis, age, migraine, hypertension, hyper

lipidaemia and stroke were independently associated with BPPV.^[17]

This study also enrolled patients who had classic symptoms of Benign paroxysmal positional vertigo but no nystagmus on Dix Hallpike test. These patients were also included because it is known that some patients do not show nystagmus due to visual fixation. Such patients require the use of specialized Fresnell lenses or infrared videonystagmography to bring out their symptoms.^[17]

Even with this specialized equipment, some may not demonstrate the typical nystagmus. In one study, 61 percentage (26 patients out of 43) with a characteristic history but who failed to demonstrate the nystagmus on videonystagmography and Fresnell lenses were successfully treated with the Epley's maneuver.^[18,19]

Epley,^[11] in his study used mastoid vibrators for increasing the effectiveness of repositioning maneuver. Herdman SJ introduced head shaking to mastoid vibrator to achieve a high success rate.^[12] Controversy still lingers around the usage of vibrators.

Schuknecht HF,^[4] reported that in 52 patients Canalith Repositioning Procedure without use of vibration resulted in 66 per cent cure initially, and eventually 99 per cent cure rate with multiple treatments. This paper suggests vibration is not necessary for good results.

In our study, all patients underwent PRM without the usage of any additional equipment. The efficacy rate obtained questions the usage of vibrators, although a controlled study is required to confirm it.

CONCLUSION

- This study establishes the efficacy of Particle Repositioning Maneuver in the management of Benign Paroxysmal Positional Vertigo.
- Particle Repositioning Maneuver resulted in reversal of vertigo and associated disability. Vertigo scales showed marked improvement.
- Recurrence of vertigo following Particle Repositioning Maneuver can be successfully treated by repeating the maneuver, which is easy to perform, simple and cost effective.
- No statistically significant association was found between idiopathic Benign Paroxysmal Positional Vertigo and conditions like neck pain, trigger points and x-ray evidence of cervical spondylosis in this study.

REFERENCES

1. Von Brevern M, Radtke A, Lezius F, et al. . Epidemiology of benign paroxysmal positional vertigo: a population based study. *J Neurol Neurosurg Psychiatry*. 2007;78:710–715.

Balakrishnan & Anirudhan; Diagnosis and Treatment of Benign Paroxysmal Positional Vertigo

2. Oghalai JS Manolidis S Barth JL, et al. . Unrecognized benign paroxysmal positional vertigo in elderly patients. *Otolaryngol Head Neck Surg* . 2000;122:630–634.
3. Fife D FitzGerald JE. Do patients with benign paroxysmal positional vertigo receive prompt treatment? Analysis of waiting times and human and financial costs associated with current practice. *Int J Audiol* . 2005;44:50–57.
4. Schuknecht HF. Cupulolithiasis. *Arch Otolaryngol* . 1969;90:765–778.
5. Hall SF Ruby RR McClure JA. The mechanics of benign paroxysmal vertigo. *J Otolaryngol* . 1979;8:151–158.
6. Dix MR Hallpike CS. The pathology, symptomatology, and diagnosis of certain common disorders of the vestibular system. *Proc R Soc Med* . 1952;45:341–354.
7. Bhattacharyya N Baugh RF Orvidas L, et al. . Clinical practice guideline: benign paroxysmal positional vertigo. *Otolaryngol Head Neck Surg* . 2008;139(5 suppl 4):S47–S81.
8. Fife TD Iverson DJ Lempert T, et al. . Practice parameter: therapies for benign paroxysmal positional vertigo (an evidence-based review): report of the Quality Standards Subcommittee of the American Academy of Neurology. *Neurology* . 2008;70:2067–2074.
9. Aw ST Todd MJ Aw GE, et al. . Benign positional nystagmus: a study of its three-dimensional spatio-temporal characteristics. *Neurology* . 2005;64:1897–1905.
10. Brandt T Daroff RB. Physical therapy for benign paroxysmal positional vertigo. *Arch Otolaryngol* . 1980;106:484–485.
11. Epley JM. New dimensions of benign paroxysmal positional vertigo. *Otolaryngol Head Neck Surg* . 1980;88:599–605.
12. Herdman SJ. Treatment of benign paroxysmal positional vertigo. *Phys Ther* . 1990;70:381–388.
13. Baloh RW Jacobson K Honrubia V. Horizontal semicircular canal variant of benign positional vertigo. *Neurology* . 1993;43:2542–2549.
14. Halker RB Barrs DM Wellik KE, et al. . Establishing a diagnosis of benign paroxysmal positional vertigo through the Dix-Hallpike and side-lying maneuvers: a critically appraised topic. *Neurologist* . 2008;14:201–204.
15. Blau P Shoup A. Reliability of a rating scale used to distinguish direction of eye movement using infrared/video ENG recordings during repositioning maneuvers. *Int J Audiol* . 2007;46:427–432.
16. Harada Y. Metabolic disorder, absorption area and formation area of the statoconia. *J Clin Electron Microsc* . 1982;18:1–18.
17. Lim DJ. Formation and fate of the otoconia: scanning and transmission electron microscopy. *Ann Otol Rhinol Laryngol* . 1973;82:23–35.
18. Epley JM. The canalith repositioning procedure: for treatment of benign paroxysmal positional vertigo. *Otolaryngol Head Neck Surg* . 1992;107:399–404.
19. Faldon ME Bronstein AM. Head accelerations during particle repositioning manoeuvres. *Audiol Neurootol* . 2008;13:345–356.

How to cite this article: Balakrishnan D, Anirudhan D. The Diagnosis and Treatment of Benign Paroxysmal Positional Vertigo through Particle Repositioning Manoeuvre: An Observational and Prospective Study. *Ann. Int. Med. Den. Res.* 2018; 4(5): MC11-MC16.

Source of Support: Nil, **Conflict of Interest:** None declared