

# A Comparative Study to Compare the Outcomes of Myringoplasty (Endoscopic Versus Microscopic)

Samneet Saggu<sup>1</sup>, Vaibhav Kuchhal<sup>2</sup>, Aakanksha Rawat<sup>3</sup>

<sup>1</sup>Junior Resident IIIrd year, Department of ENT and head and neck surgery, Government Medical College Haldwani, Uttarakhand, India.

<sup>2</sup>Professor and head, Department of ENT and head and neck surgery, Government Medical College Haldwani, Uttarakhand, India.

<sup>3</sup>Junior Resident 1st year, Department of ENT and head and neck surgery, Government Medical College Haldwani, Uttarakhand, India.

Received: April 2018

Accepted: April 2018

**Copyright:** © the author(s), publisher. It is an open-access article distributed under the terms of the Creative Commons Attribution Non-Commercial License, which permits unrestricted non-commercial use, distribution, and reproduction in any medium, provided the original work is properly cited.

## ABSTRACT

**Background:** The aim of this study is to compare the outcomes of myringoplasty using the microscope and the endoscope. **Methods:** This was a prospective study carried out in the department of otorhinolaryngology of Dr Susheela Tiwari Government Hospital, Haldwani. **Results & Conclusion:** There was no statistical difference in both the groups in term of graft uptake and post operative hearing outcome, however the endoscopic approach took considerably less time, had less post operative pain and a better cosmetic result.

**Keywords:** Myringoplasty, endoscope versus microscopic.

## INTRODUCTION

The diagnosis of chronic otitis media (COM) implies a permanent abnormality of the pars tensa or flaccida, most likely a result of earlier acute otitis media, negative middle ear pressure or otitis media with effusion. COM equates with the classic term chronic 'suppurative' otitis media that is no longer advocated as COM is not necessarily a result of the gathering of pus.<sup>[1]</sup>

### Classification of Com

- Mucosal Type
- Squamous Type
- Healed Type

Mucosal and Squamous types are further subdivided into active and inactive types

### Aim

The aim of the study is to compare the outcomes of microscope versus endoscope assisted myringoplasties performed in Dr Susheela Tiwari Government Hospital in the department of otorhinolaryngology. The outcome will be compared in terms of:

- Graft take up
- Improvement of hearing
- Complications, if any

### Name & Address of Corresponding Author

Dr. Vaibhav Kuchhal,  
Professor and HOD,  
Department of ENT and Head & Neck Surgery,  
Government Medical College,  
Haldwani, Uttarakhand, India.

## MATERIALS AND METHODS

The following study is a comparative prospective study carried out on 60 patients in total having Chronic Otitis Media (inactive mucosal type) presenting in the OPD in the department of Otorhinolaryngology at Dr Susheela Tiwari Government Hospital, Haldwani.

The patients will be categorised into 2 groups of 30 patients each:

Patients in Group A will undergo microscope assisted myringoplasty.

Patients in Group B will undergo endoscope assisted myringoplasty.

Microscope assisted tympanoplasty was performed by a postaural approach via William Wilde's incision firstly temporalis fascia graft is harvested. Margins of the perforation are freshened and then tympanomeatal flap is elevated. Now a properly dried temporalis fascia graft of appropriate size is introduced through the ear canal. The graft is insinuated under the handle of malleus. The tympanomeatal flap is repositioned in such a way that it covers the free edge of the graft which has been introduced. Bits of gelfoam is placed around the edges of the raised flap.

Endoscope assisted myringoplasty was performed using 0° endoscope of 4 mm diameter. Transmeatal approach is used for surgery. The edges of the perforation are excised with a sickle knife. Tympanomeatal flap is elevated. Horizontal incision is given in temporal region and the Temporalis fascia graft is harvested. Temporalis fascia graft inserted to overlap the medial surface of the drum

remnant. The graft is kept in position by small gelfoam pieces soaked in antibiotic solution. The ear canal is then lightly packed with antibiotic gelfoam pack. All these steps will be performed under endoscopic vision.

**Inclusion Criteria**

- Patients with chronic otitis media (inactive mucosal type)

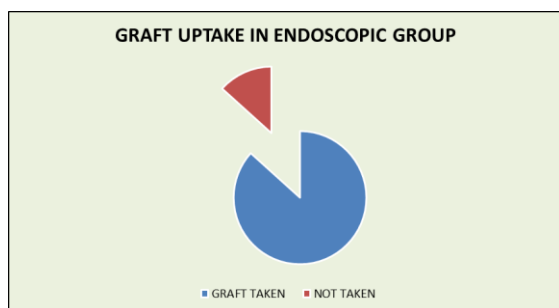
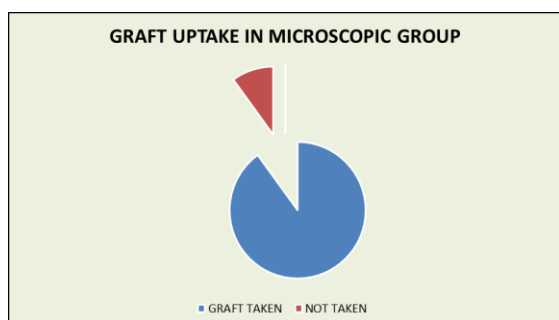
**Exclusion Criteria**

- Patients with sensorineural hearing loss(SNHL)
- Patients with only hearing ear.
- Patients with sinonasal pathology.
- Patients in the age group <6 years and >65 years.
- Patients not giving consent for surgery
- Patient unfit for surgery and general anesthesia.

**RESULTS**

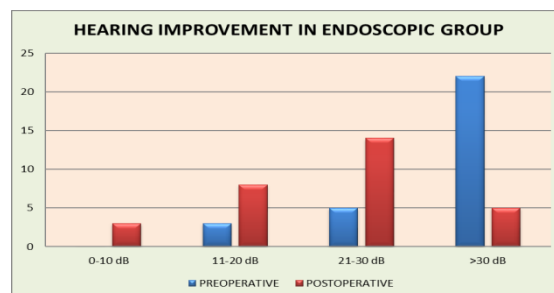
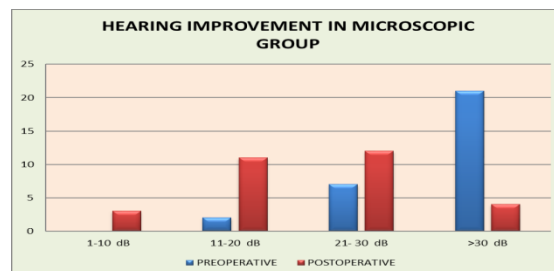
**GRAFT UPTAKE-** seen in total of 53 patients (88.3%) out of 60 patients.

Graft Uptake	Total	Microscopic	Endoscopic
	53	27	26



**Hearing Improvement**

Conductive Hearing Loss (In Db)	Preoperative In Total Patients	Postoperative In Total Patients	Preoperative In Microscopic Group	Postoperative In Microscopic Group	Preoperative In Endoscopic Group	Postoperative In Endoscopic Group
0-10	0	6	0	3	0	3
11-20	5	19	2	11	3	8
21-30	12	26	7	12	5	14
>30	43	9	21	4	22	5

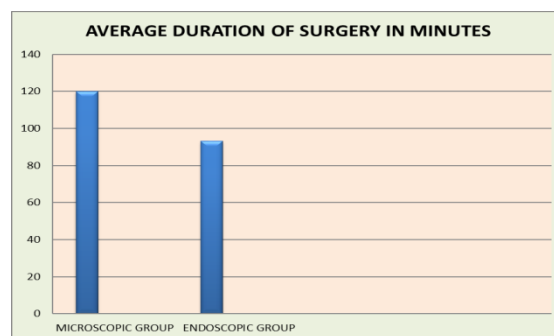


**Post Operative Complications**

There were no significant complications in either group. However grade I retraction of tympanic membrane was seen in 3 patients of the endoscopic group (10%). All the three patients had type A curve on the subsequent tympanogram.

**Average Duration of Surgery**

Average Duration Of Surgery	Microscopic Group	Endoscopic Group
	120 Minutes	93 Minutes



**Cosmetic Result**

Cosmetic Result	Microscopic Group	Endoscopic Group
Poor	0	0
Satisfactory	22	2
Excellent	8	28

**DISCUSSION**

Myringoplasty is a surgical procedure which is confined to the drum head without manipulation of the ossicles or middle ear. Tympanoplasty is the surgical procedure which includes the manipulation of tympanic membrane and eradication of disease from the middle ear if present. Specialized

instruments like the ocular magnifying loops and the operating microscope opened up a new dimension to otology surgery. The newest technique of performing tympanoplasty is the endoscopic tympanoplasty. This study was undertaken with the objective of determining the advantages & disadvantages of endoscope when compared to the conventional operating microscope in myringoplasty surgery.

### **Graft uptake**

In our study overall successful graft uptake was observed in a total of 53 out of 60 patients (88.3%). Graft uptake in the microscopic group was 90% and 86.6% in the endoscopic group. Similar results were observed in the study conducted by Harugop AS et al, in their study 41(82%) patients had a successful outcome in the endoscope group and 43 (86%) patients had a successful outcome in the microscope group.<sup>[2]</sup>

Similarly in the study conducted by Lakpathi G. et al, they found at 6 months, 26 (88 %) patients had a successful outcome in the endoscope group and 27(90 %) patients had a successful outcome in microscope group.<sup>[3]</sup>

In the study conducted by Kumar M. et al, graft uptake was 86% in the conventional microscopic group and 83% in the endoscopic group.<sup>[4]</sup>

Shoeb M. et al found the drum healing or graft uptake was 93.33% in both the groups (microscopic and endoscopic groups).<sup>[5]</sup>

In the study conducted by Patel J. et al, they observed that in endoscopic group 16 (72.72 %) patients while in microscopic group 20 (90%) patients showed complete graft uptake.<sup>[6]</sup>

Raj A and Meher R observed that in the endoscopic group, there was 90% uptake of graft and in microscopic group it was 85%.<sup>[7]</sup>

In the study by Gadag R et al, Out of 30 endoscopic tympanoplasty 22(74%) had good graft uptake, 8(26%) patients had residual perforation at 12 weeks. Out of 30 microscopic tympanoplasty 24 (80%) had good graft uptake, 6 (20%) patients had residual perforation at 12 weeks.<sup>[8]</sup>

Sinha M. et al found that graft was taken up in 21 patients (95%) in microscopic as opposed to 20 in endoscopic group (90%).<sup>[9]</sup>

According to Garcia et al, in terms of surgical outcome at postoperative otoscopy, complete closure of the perforation was observed in 86.4% of patients three months after intervention (endoscopic myringoplasty).<sup>[10]</sup>

In the study conducted by Yadav SPS, 40 out of the 50 patients had an intact tympanic membrane in the eighth postoperative week of endoscopic myringoplasty, accounting for an 80% success rate.<sup>[11]</sup>

### **Hearing improvement**

In our study, 51 out of 60 patients (85%) had a post operative hearing level within 30 dB. In the

microscopic group, 26 out of 30 patients (86.7%) had a post operative hearing level within 30 dB and in the endoscopic group 25 out of 30 (83.3%) patients had a post operative 30 dB hearing level in audiogram done 3 months after surgery.

Air bone gap closure in our study was seen within 20dB in 55 out of 60 patients (91.7%). In the microscopic group AB gap closure within 20 dB was seen in 28 of 30 patients (93.3%) and in the endoscopic group closure of AB gap within 20 dB was seen in 27 of 30 patients (90%). In the study conducted by Lakpathi G. et al almost 90 % of patients post operatively had an improvement in conductive hearing loss with average between 0 and 20 dB conductive hearing loss in both the microscopic as well as endoscopic groups.<sup>[3]</sup>

Harugop AS et al in their study found that almost all the patients in both the endoscopic as well as microscopic groups had a postoperative hearing threshold within 30 dB.<sup>[2]</sup>

Patel J et al in their found that at three months follow up in endoscopic group 10 (45.45%) patients had postop A-B gap in the range of 0 to 10 dB while 11 (50 %) patients had postop A-B gap in the range of 11 to 20 dB while in microscopic tympanoplasty 10 (45.45%) patients had postop A-B gap in the range of 0 to 10 dB while 8 (36.36 %) patients had postop A-B gap in the range of 11 to 20 dB.<sup>[6]</sup>

In the study conducted by Shoeb M. et al found that in the microscopic and endoscopic groups the pre-operative mean AB gap was 38.87±4.88 dB and 35.6±6.31 respectively and post-operative at 6months mean AB gap was 17.47±1.96 dB and 16.8±74.32 dB respectively.<sup>[5]</sup>

Kumar M. et al in their study observed that preoperative average AB gap in the microscopic group was 16.05dB and in the endoscopic group was 15dB. Average postoperative gain in the microscopic and endoscopic groups were 13.96 and 15.03 dB respectively.<sup>[4]</sup>

In the study by Ambani K. et al, postoperatively hearing loss in the endoscopic group was within 30 dB was found in 38 of 40 patients(95%).<sup>[12]</sup>

### **Complications**

There were no significant complications in either group. However grade I retraction of tympanic membrane was seen in 3 patients of the endoscopic group (10%). All the three patients had type A curve on the subsequent tympanogram.

There were no similar findings in the literature to correlate with our findings.

### **Post operative cosmesis**

In our study 28 out of 30 patients (93.3%) in the endoscopic group rated their cosmetic result as excellent and the remaining 2 patients were satisfied with their cosmetic result.

In the microscopic group, 22 patients out of 30 patients i.e. 73.3% were satisfied with the cosmetic

outcome and only 8 patients (26.7%) found their cosmetic result excellent.

Lakpathi G et al in their study, found that (100 %) patients in the endoscope group rated their cosmetic result as excellent, whereas in the microscope group 06 (20 %) patients rated their cosmetic result as poor, 15 (50 %) rated the cosmetic result as satisfactory and 9 (30 %) patients rated their cosmetic result as excellent.<sup>[3]</sup>

Their findings were echoed by Harugop AS et al in their study, they observed that at the end of six months all (100%) patients in the endoscope group rated their cosmetic result as excellent whereas in the microscope group 10 (20%) patients rated their cosmetic result as poor, 25 (50%) patients rated the cosmetic result as satisfactory and 15(30%) patients rated their cosmetic result as excellent.<sup>[2]</sup>

In the study conducted by Kumar M, et al, in the endoscopy group all the patients rated their cosmetic outcome as excellent, whereas in the microscopic group 10 patients (33.3%) rated their cosmetic result as excellent, 16(53.3%) and 4(13.3%) patients rated their cosmesis as satisfactory and poor respectively.<sup>[4]</sup>

In our study better cosmetic result in the microscopic groups as compared to these studies may be due to the fact that we used subcuticular continuous sutures for skin closure.

#### **Post operative Pain**

In the microscopic group, 12 out of 30 patients (40%) complained of post operative pain in the post aural region, whereas only 2 patients (6.6%) had similar complaints.

No similar findings were recorded in the forementioned studies.

However Gadag R. et al in their study found that postoperative recovery was better in the endoscopic group.<sup>[8]</sup>

#### **Operating time**

The average time duration for the microscopic surgery was 120 minutes (110-134 minutes) and that for the endoscopic group was 93 minutes (90-106 minutes).

Similar results were observed by Harugop AS et al, endoscope assisted myringoplasty required an average 128 mins (range 90–180 mins) and microscope assisted myringoplasty needed an average time of 106 mins (range 80–135 mins).<sup>[2]</sup>

In the study by Ambani K. et al, average time taken for endoscopic myringoplasty was around 1hour 30min with range of 70-140min.<sup>[12]</sup>

In the study by Alguadivel J. et al, the time taken for the endoscopic technique is an average of 120 minutes with a range 80-160 minutes.<sup>[13]</sup>

Patel J. et al found that the average time taken for endoscope assisted tympanoplasty was around 75 minutes, while the same time taken for microscopic tympanoplasty was around 90 minutes.<sup>[6]</sup>

In the study by Huang TY et al, the average operation time in microscopic group was 75.5±20.4 minutes, compared to 50.4±13.4 minutes in endoscopic group.<sup>[14]</sup>

The difference in the operating time may depend upon the surgeon and his/her expertise, however it is the general observation that time taken in the endoscopic group is significantly lower in comparison to the microscopic group.

### **CONCLUSION**

- Graft uptake in the microscopic group was 90% (27 of 30 patients) and in the endoscopic group it was 86.6% (26 of 30 patients).
- Post operative hearing threshold, in the microscopic group within 30 dB was seen in 86.6% of the patients (26 patients) and in the endoscopic group it was in 83.3% of the patients.
- There were no significant complications seen in either group, however grade I retraction of tympanic membrane was seen in 3 patients (10%) in the endoscopic group.
- The main advantages of endoscopic surgery we observed were
  1. took considerably less time
  2. reduced post operative pain
  3. better cosmetic result.
  4. It is easily transportable
  5. some of the difficult to see areas can be seen with the help of angled scopes like round window niche, Eustachian tube orifice, incudo-stapedial joint etc.
- The major disadvantage of endoscopic approach is
  1. It is a one handed technique and this becomes cumbersome when there is excessive bleeding.
  2. Depth perception is not as good as with a binocular microscope.

### **REFERENCES**

1. Browning GG, Chronic Otitis Media Scott- Brown's Otorhinolaryngology, and Head and Neck Surgery: 7th edition: Chapter 237c p-3396-3401.
2. Harugop AS, Mudhol RS, Godhi A. Comparative study of endoscope assisted myringoplasty and microscope assisted myringoplasty. Indian Journal of Otolaryngology and Head & Neck surgery. 2008;60(4):298-302.
3. Lakpathi G: Comparative Study of Endoscope Assisted Myringoplasty and Microscopic Myringoplasty: Indian J Otolaryngol Head Neck Surg (Apr-June 2016) 68(2):185-190.
4. Kumar M., Kanaujia S.K., Singh A. A comparative study of endoscopic myringoplasty vs conventional myringoplasty, Int J Otorhinolaryngol Clin 2015;7(3):132-137.
5. Shoeb M, Gite V, Bhargava S, Mhashal S. Comparison of surgical outcomes of tympanoplasty assisted by conventional microscopic method and endoscopic method. Int J Otorhinolaryngol Head Neck Surg 2016;2:184-8.
6. Patel J, Aiyer RG, Gajjar Y, Gupta R, Raval J, Suthar PP. Endoscopic tympanoplasty vs microscopic tympanoplasty in tubotympanic csom: a comparative study of 44 cases. Int J Res Med Sci 2015;3(8):1953-7.

7. Raj A, Meher R. Endoscopic transcanal myringoplasty-A study. *Indian J Otolaryngol Head Neck Surg.* 2001; 53:47-9.
8. Gadag R.: Comparative study of outcomes of microscopic versus endoscopic myringoplasty. *Medica Innovatica* July 2016, Volume 5 - Issue 1 p 3-6.
9. Sinha M, Hirani N, Khilnani AK. Comparison of endoscopic underlay and microscopic underlay tympanoplasty: a prospective research at a tertiary care centre in Gujarat. *Int J Otorhinolaryngol Head Neck Surg* 2017;3:874-7.
10. Garcia LB, Moussalem GF, de Andrade JSC, Mangussi-Gomes J, Cruz OLM, Penido NO, et al. Transcanal endoscopic myringoplasty: a case series in a university center. *Braz J Otorhinolaryngol.* 2016;82:321-5.
11. Yadav SPS, Agarwal N, Julaha M, Goel M. Endoscope assisted myringoplasty. *Singapore med J.*2009; 50(5):510-2.
12. Ambani KP, Bhavya BM, Vakharia SD, Khanna A, Katarkar AU. Merits and demerits of endoscopic tympanoplasty. *Int J Otorhinolaryngol Head Neck Surg* 2017;3:395-9.
13. Alaguvadivel J, Raj M, Retrospective study of outcome of endoscopic transcanal myringoplasty using 00 nasal endoscope. *MedPulse International Journal of ENT, Print ISSN: 2579-0854, Volume 3, Issue 1, July 2017 pp 05-09.*
14. Huang TY et al. A Comparative Study of Endoscopic and Microscopic Approach Type 1 Tympanoplasty for Simple Chronic Otitis Media. *J Int Adv Otol* 2016; 12(1): 28-31.

**How to cite this article:** Saggu S, Kuchhal V, Rawat A. A Comparative Study to Compare the Outcomes of Myringoplasty (Endoscopic Versus Microscopic). *Ann. Int. Med. Den. Res.* 2018; 4(4):EN16-EN20.

**Source of Support:** Nil, **Conflict of Interest:** None declared