

# Parry Romberg Syndrome: A Rare Entity with Possible Association with Periodontitis.

Houda Elghoulbzouri<sup>1</sup>, Samir Er-raji<sup>1</sup>, Oum Keltoum Ennibi<sup>1</sup>

<sup>1</sup>Department of Periodontology, Laboratory of Oral Biology and Biotechnology, Dental School, Mohammed V University, Rabat, Morocco.

Received: March 2018

Accepted: March 2018

**Copyright:** © the author(s), publisher. It is an open-access article distributed under the terms of the Creative Commons Attribution Non-Commercial License, which permits unrestricted non-commercial use, distribution, and reproduction in any medium, provided the original work is properly cited.

## ABSTRACT

**Background:** Parry Romberg syndrome (PRS) or progressive hemifacial atrophy is a rare entity uncommon, degenerative, poorly understood with unknown etiology, but possible factors that are involved in the pathogenesis in this disorder, like trophic malfunction of sympathetic system, disturbance of fat metabolism, trauma, viral infections, heredity, endocrine disturbances and auto-immunity. PRS is seen most generally unilateral, in facial tissues including muscles, bones and skin. This alteration is characterized by the “coup de sabre”; this is clear line of demarcation between the normal and abnormal structures, results in psychological disturbance and communication defects like speech defects, and also dental malformations. It needs multi-disciplinary approach including physician, dentist and psychiatric. The objective of this work is to report a rare case of PRS, concerning a young female patient, with persistence of moderate periodontal destruction with severe gingival inflammation. Extensive investigations and a multi-disciplinary approach are necessary for successful management of the case.

**Keywords:** Chronic periodontitis, En coup de sabre, Oral manifestations, Parry Romberg syndrome, Progressive hemifacial atrophy.

## INTRODUCTION

Parry Romberg syndrome is a degenerative condition characterized by a slow progressive unilateral atrophy of facial tissues including subcutaneous fat, muscles, bone and skin.<sup>[1-3]</sup> This syndrome seems to have higher incidence on Women.<sup>[4]</sup> It affects individuals who are morphologically normal at birth, Onset is usually in the first or second decade of life. More than an esthetic illness, it brings functional and psychological problems like trigeminal neuralgia, migraine, seizures, ocular problem and epilepsy.<sup>[3,4]</sup> The incidence and cause of this alteration is unknown. Some of the proposed etiologies include heredity, auto-immune disorders, trauma, hypo- or hyperactivity of the sympathetic nervous system, disorders of the trigeminal nerve and infectious diseases and cerebral disturbance on fat metabolism heredity are believed to be associated to the pathogenesis of the disease.<sup>[5,6]</sup> Diagnosis is based on history and clinical features. The presence of unilateral idiopathic facial atrophy,

typically involving the lower face, without significant epidermal change. Deeper involvement of bone, teeth, tongue, and gingiva may also be present. Histopathological evidence of epidermal atrophy and dermal fibrosis is akin to scleroderma. Imaging studies like cranial computed tomography (CT) and magnetic resonance images (MRI) show numerous neurological and vascular lesions.<sup>[7,8]</sup> There are no published trials of the treatment, however, after stabilization of PRS, the restorative plastic surgery which includes fat or silicone implants, flap/pedicle grafts or bone implants can be used.<sup>[9,10]</sup>

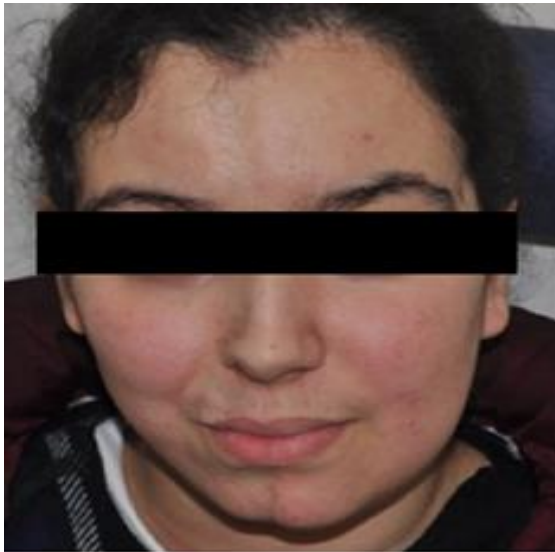## CASE REPORT

In April 2016, a 24 -years- old female patient reported to the department of periodontics of, dental faculty of Rabat, with chief complaint of severe gingival inflammation persistent, which showed minimal response to non-surgical and surgical periodontal treatment made in 2015 in private dental clinic. The medical history of the patient revealed that she is followed in department of dermatology of Ibn Sina Hospital, since 2014 for parry romberg syndrome (PRS). In addition, she was taking prednisone 50 mg/day and methotrexate MTX 15mg, 1 injection /week since 2015. The extraoral examination, showed gross facial asymmetry with marked hypoplasia, incompetency

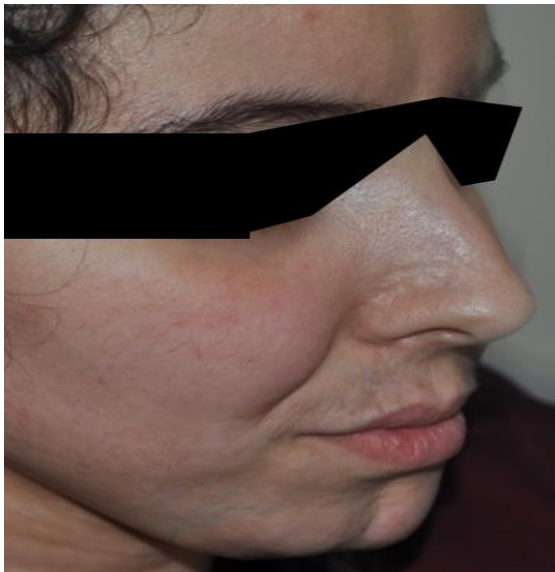### Name & Address of Corresponding Author

Dr. Elghoulbzouri Houda,  
Department of Periodontology,  
Laboratory of Oral Biology and Biotechnology,  
Dental School, Mohammed V University,  
Rabat, Morocco.

of lips and obliteration of nasolabial fold were seen on the right side. It was characterized by the presence of linear demarcation” en coup de sabre” [Figure 1, 2]



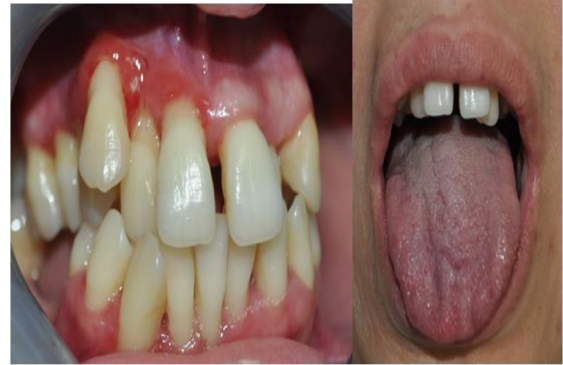**Figure 1: Extra-oral image showing facial asymmetry of the right side with deviation of the nose.**



**Figure 2: A linear scar (coup de sabre) in mandibular mentum region**

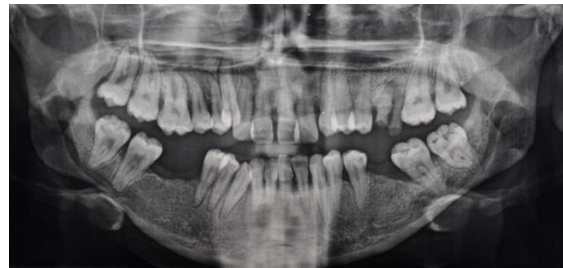
Intraoral examination revealed poor oral hygiene; plaque index (PI) was 2.9, important swelling and bleeding of the gums, with gigital index (GI) of 2.7 especially in the right side.

It was observed also gingival recessions with attachment loss of 2 to 3 mm. It shows also dental malocclusions, and an unilateral atrophy of tongue [Figure 3]



**Figure 3: An intra-oral image showing severe gingival inflammation and asymetry of the tongue**

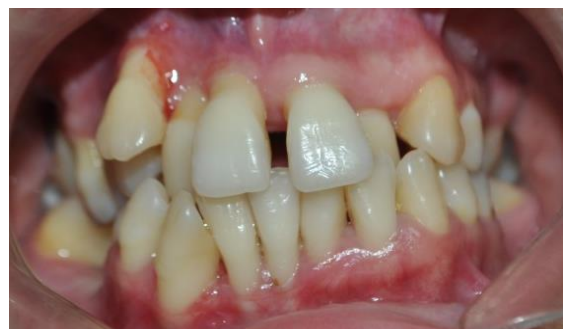Orthopantamogram showed prominent antegonial notch on the right side with decreased ramus height and a moderate bone loss especially in the same side [Figure 4]



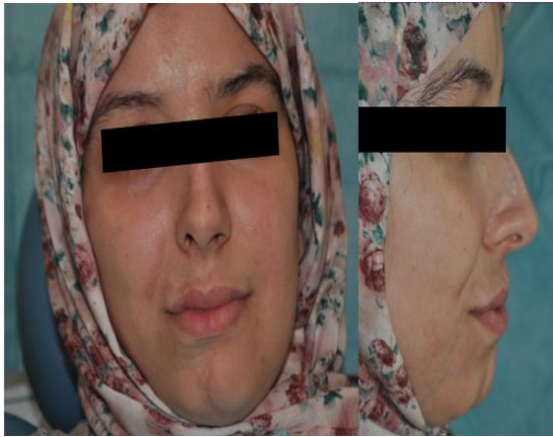**Figure 4: Orthopantamogram photograph showing moderate bone loss**

Based on clinical evaluation and radiographic features, a diagnosis of moderate chronic periodontitis was made. Periodontal therapy comprising mechanical and chemical removal of plaque and calculus, as well as patient instructions on oral hygiene maintenance was initiated, along with antibiotic prophylaxis (amoxicilline 2 g/ 1 hour before debridment).

Two months later, the patient was re-evaluated and a regression of gingival inflammation was observed [Figure 5]. This reason allowed to refer the patient to orthodontic department for correction of dental malpositions, with periodic visits. Unfortunately, the patient declined the treatment for financial difficulties.



**Figure 5: Regression of gingival inflammation after 2 months.**



**Figure 6: Stability of hemifacial atrophy after 18 months of medical treatment**

## DISCUSSION

Parry Romberg syndrome is rare pathology. It was first described by Parry (1825) and then Romberg (1846) and known as a trophoneurosis facialis.<sup>[11]</sup> The term “progressive hemifacial atrophy” was coined by Eulenberg in 1871 to describe a condition characterized by unilateral atrophy of facial structures.<sup>[3]</sup> This disorder can affect skin-soft tissue, muscles and bones, which were present in our case.<sup>[12]</sup> More strict definitions of the syndrome include contralateral jacksonian epilepsy, trigeminal neuralgia, and changes in the eyes and hair.<sup>[1]</sup> This rare entity is more commonly seen in women with a ratio of 3:2.<sup>[13]</sup> It affects the left side of the face though the present case showed involvement of the right side. The extension of the atrophy is frequently limited to one side of the face, and ipsilateral facial involvement is rare (10-20% of cases were reported bilaterally).<sup>[11]</sup> The incidence is not well-established, the average onset of disease is around 10 years of age. However, onset can be found as late as 40-50 years for some patients. Our patient was diagnosed at the age of a 22.

The exact etiology of hemifacial atrophy is unknown and not clear, although the primary cause appears to be a cerebral disturbance of fat metabolism lesion. Viral infections, endocrine disturbances, trauma, auto-immunity, and hereditary causes have also been suggested. Isolated cases have been observed with positive serology for Lyme disease.<sup>[3,5]</sup>

The clinical features are unilateral atrophy of the skin, subcutaneous fat and in some cases muscle and bone, resulting in facial asymmetry. Skin is tensed or fibrosed with loss or gain of pigmentation can be observed. Hair defects when present, manifests as focal baldness and facial hair loss. PRS can often affect eyes, ophthalmic involvement occurs in 10% to 35% of cases, with frequently reported progressive enophthalmos due to loss of periorbital fat.<sup>[11]</sup> Our case showed a clear line of

demarcation in the right side with no orbital changes.

Few oral findings have been reported in the literature.<sup>[11]</sup> Teeth abnormalities and involvement of the mandible and masticatory muscles is frequently seen in patients with PHA. The oral mucosa and tongue can be affected, as also are jaws and salivary glands. There is deviation of the mouth and nose toward the affected side. There may be also deviation and an unilateral reduction in tongue size on the affected side (as seen in the present case). In cases with dental involvement infection is frequent. Pain due to masticatory muscle spasm, temporomandibular joint pain and locking of the jaw has also been reported. Osseous defects are usually seen when the atrophy appears before 15 years of age. Fronto-maxillary defects are seen in before-5-year onsets; mandibular defects in 5–15 year onsets while later onsets (>15 years) have almost exclusively soft tissue changes. Jaws are smaller unilaterally in all dimensions, resulting in a midline shift towards the affected side, along with delay in mandibular angle development.<sup>[7,14]</sup> Concerning periodontal tissue, none of the reports published in the literature reported the association between PRS and periodontal disease, except Taylor in 2017, who described the case of a female patient with severe periodontitis resistant to treatment.<sup>[11]</sup>

Diagnosis of PRS is based on patient history and clinical examination if the patient is having facial asymmetry (physical signs). It can be supported by imaging studies like MRI and CT scan if the patient is having neurological symptoms.<sup>[4]</sup>

Parry Romberg Syndrome is self-limiting pathology and has no definite cure, which can be a challenge for physician. However, in the active stage of the disease various treatments have been proposed to stop the progression of the disorder. This includes administration of oral steroids, D-penicillamine, methotrexate, cyclophosphamide, interferons, antimalarials, cyclosporine and azathioprine.<sup>[3]</sup>

Currently, Methotrexate (MTX), in its oral or injectable form, is the best choice of treatment for active disease. MTX dosing is not standardized and ranges from 0.3-1 milligrams/ kilogram/week (mg/kg/wk) to a maximum dose of 25 mg weekly. It is often combined with oral prednisone, 1 mg/kg/day, over the first three months due to the fact that the methotrexate has a delayed effect on inflammation and fibrosis. The goal with this approach is to gain the anti-inflammatory effects of corticosteroids without the large side-effects.<sup>[8,15,16]</sup> After stabilisation of pathology process, various surgical treatments can be proposed to correct the appearance and function of involved facial structures, as fat grafting, lipoinjection and other soft tissue fillers. For more severe atrophy, a combined approach of skeletal and soft tissue

augmentation is often recommended, preferably, during the craniofacial growth period by stimulating those growth centres that are not directly involved in the wasting process with functional orthodontic appliance therapy in an attempt to maintain mandibular symmetry. The goal of those treatments is to create a better cosmetic outcome, to minimize psychosocial effects and to increase satisfaction and self-confidence of the patient.<sup>[8,17]</sup>

## CONCLUSION

Parry Romberg syndrome is a rare entity that manifests with facial hemi-atrophy and affects adipose and osseous structures of soft tissues. This may have aesthetic, functional and psychological sequelae. Origin of PRS is unknown and not clear. Moreover, this pathology is associated with ocular and dental features. Our case was diagnosed at 22 years of age and is undergoing treatment. It presented facial and mandibular defect with particularity of periodontitis persistent. More research is necessary to assess its possible association with periodontal diseases and to consider PRS as one of the varied systemic causes for recalcitrant periodontal lesions.

## REFERENCES

1. Regezi JA, Scuibba JJ, Jordan RC. Oral pathology. Clinical pathological correlations 4th ed USA: Saunders: Elsevier Science; 2003.
2. Balan P, Gogineni SB, Shetty SR, D'Souza D. Three-dimensional imaging of progressive facial hemiatrophy (parry-romberg syndrome) with unusual conjunctival findings. *Imaging Sci Dent* 2011;41(4):183-187
3. Nair M, Ajila V, Hedge S, Babu GS, Ghosh R. Clinical and radiographic features of Parry-Romberg syndrome. *J Istanbul Univ Fac Dent* 2017;51(3):45-49.
4. Patel H, Thakkar C, Patel K. Parry-Romberg Syndrome: A Rare Entity. *J. Maxillofac. Oral Surg.* (July-Sept 2010) 9(3):247-250
5. Da Pinheiro- Silva TP, da Camarinha-Silva C, da Limeira-Silveira CS, Ereno-Botelho PC, Rodrigues-Pinheiro MG, Viana-Pinheiro JJ. Progressive hemifacial atrophy—case report. *Med Oral Patol Oral Cir Bucal* 2006. 11(2):112-114
6. Kaya M, Sel Yilmaz C, Kurtaran H, Gunduz M. Chronologic presentation of a severe case of progressive hemifacial atrophy (parry-romberg syndrome) with the loss of an eye. *Case Rep Otolaryngol* 2014;:703017.
7. Madasamy R, Jayanandan M, Adhavan UR, Gopalakrishnan S, Mahendra L. Parry Romberg syndrome: A case report and discussion. *J Oral Maxillofac Pathol* 2012; 16:406-410.
8. Tolkachjov S, Patel N, Tollefson M. Progressive hemifacial atrophy: a review. *Orphanet Journal of Rare Diseases* 2015; 10:39
9. Stone J. Parry Romberg syndrome. *Practical Neurology* 2006; 6: 185-188.
10. Rangare RA, Babu GS, Thomas PS, Shetty RS. Parry-Romberg Syndrome: a Rare Case Report. *J Oral Maxillofac Res* 2011.
11. Taylor, G., Culshaw, S., Armas, J., Savarrio, L. and Goodall, C.), A case report of Parry Romberg Syndrome initially presenting as periodontitis. *Oral Surgery* 2017.
12. Aydin H, Yologlu Z, Sargin h, Rusen Metin M. Parry-Romberg syndrome Physical, clinical, and imaging features *Neurosciences* , 2015 Oct; 20(4): 368–371.
13. Khan M, Khan M, Negi R, Gupta N. Parry romberg syndrome with localized scleroderma: A case report. *J Clin Exp Dent* 2014;6(3):313-316.
14. Gómez-Diez S, Gallego-López L, López-Escobar M, Junquera-Gutiérrez L, Pérez-Oliva N. Progressive facial hemiatrophy with associated osseous lesions. *Med Oral Patol Oral Cir Bucal* 2007;12.
15. Zulian F, Cuffaro G, Sperotto F. Scleroderma in children: an update. *Curr Opin Rheumatol.* 2013;25(5):643–650.
16. Korkmaz C, Adapinar B, Uysal S. Beneficial effect of immunosuppressive drugs on Parry-Romberg syndrome: a case report and review of the literature. *South Med J.* 2005;98(9):940–942
17. Slack GC, Tabit CJ, Allam KA, Kawamoto HK, Bradley JP. Parry-Romberg reconstruction: optimal timing for hard and soft tissue procedures. *J Craniofac Surg.* 2012;23:1969–1973.

**How to cite this article:** Elghoulbzouri H, Er-raji S, Ennibi OK. Parry Romberg Syndrome: A Rare Entity With Possible Association With Periodontitis. *Ann. Int. Med. Den. Res.* 2018; 4(3):DE39-DE42.

**Source of Support:** Nil, **Conflict of Interest:** None declared