

# Assessment of Tooth Movement with Piezocision and Its Periodontal Transversal Effects in Class II Malocclusion Patients: A Clinical Study.

Vijayendra Pandey<sup>1</sup>, Subhash Chandra<sup>2</sup>, Nitubroto Biswas<sup>3</sup>, Santosh Kumar<sup>4</sup>, Shweta Singh<sup>5</sup>, Mukesh Kumar<sup>5</sup>

<sup>1</sup>Professor & HOD, Periodontology, Vananchal Dental College & Hospital, Garhwa, Jharkhand, India.

<sup>2</sup>Reader, Orthodontics, Dental Institute, RIMS, Ranchi, Jharkhand, India.

<sup>3</sup>Professor, Periodontology, Buddha Institute of Dental Sciences & Hospital, Patna, Bihar, India.

<sup>4</sup>Senior Lecturer, Orthodontics, Vananchal Dental College & Hospital, Garhwa, Jharkhand, India.

<sup>5</sup>Post Graduate Student, Periodontology, Vananchal Dental College & Hospital, Garhwa, Jharkhand, India.

<sup>5</sup>PG Student, Periodontology, Vananchal Dental College & Hospital, Garhwa, Jharkhand, India.

Received: July 2018

Accepted: August 2018

**Copyright:** © the author(s), publisher. It is an open-access article distributed under the terms of the Creative Commons Attribution Non-Commercial License, which permits unrestricted non-commercial use, distribution, and reproduction in any medium, provided the original work is properly cited.

## ABSTRACT

**Background:** There are considerable amount of population suffering from malocclusion. An increasing number of patients are demanding orthodontic treatment for improved esthetics and a better mastication system. The present study was conducted to assess tooth movement with piezocision and its periodontal transversal effects in class II malocclusion patients. **Methods:** The present study was conducted in the department of Orthodontics. It comprised of 120 patients with class II malocclusion. Before canine distalization and after the alignment and leveling phases, piezocision was performed on experimental side (Group I). Tooth mobility and gingival index was assessed on both sides. **Results:** In group I, there was  $3.56 \pm 1.4$  months and in group II there was  $5.61 \pm 1.2$  months for distalization. There was  $1.54 \pm 1.3$  mm and  $0.80 \pm 1.1$  mm distalization in group I and group II. The difference was significant ( $P < 0.05$ ). The mobility score was 1.2 and 1.4 before and after distalization in group I and 1.3 and 1.5 before and after distalization in group II. The difference was non-significant. Gingival index score was 1.4 and 1.3 before and after distalization in group I and 1.5 and 1.6 before and after distalization in group II. The difference was non-significant ( $P > 0.05$ ). **Conclusion:** Piezocision-assisted distalization accelerates tooth movement, decreases the anchorage loss for posterior teeth, and does not induce any maxillary transversal change. This technique does not have any adverse effects on periodontal health.

**Keywords:** Canine, Piezocision, Distalization.

## INTRODUCTION

There are considerable amount of population suffering from malocclusion. An increasing number of patients are demanding orthodontic treatment for improved esthetics and a better mastication system. One of the important challenges of orthodontic treatment faced by both patients and orthodontists is the treatment duration.<sup>[1]</sup>

The rate of biological orthodontic tooth movement is approximately 1 mm over 4 weeks. Accordingly, in cases of upper premolar extraction and maximum anchorage, distalization of canines can take almost 7 months, leading to total treatment

duration of 2 years. To face this challenge, several surgical techniques have been developed and attempted, including periodontal ligament distraction, micro-osteoperforations and piezopuncture.<sup>[2]</sup>

Among the various types of malocclusion found in human population, class II division 1 is one of the most common. Mandibular retrusion is the most common feature of class II division 1 malocclusion in growing children. Class II malocclusion is found in 15% of population in the world. Class II division 1 malocclusion is often complicated by the presence of underlying skeletal discrepancy between maxilla and mandible. It can be due to protrusive maxilla, retrusive mandible, or a combination of both. The treatment of class II division 1 depends upon the age of the patient, growth potential, severity of malocclusion, and compliance of patient for treatment.<sup>[3]</sup>

The insertion of a scalpel and mallet into the gingiva and the placement of incisions using an ultrasonic tool is called piezocision. These

### Name & Address of Corresponding Author

Dr. Vijayendra Pandey,  
Professor & HOD, Periodontology,  
Vananchal Dental College & Hospital,  
Garhwa, Jharkhand, India.

incisions or bone injuries are responsible for the initiation of a deciduous demineralization process called the regional acceleratory phenomenon (RAP).<sup>[4]</sup> The present study was conducted to assess tooth movement with piezocision and its periodontal transversal effects in class II malocclusion patients.

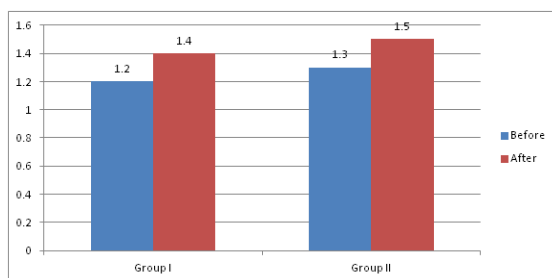
### MATERIALS AND METHODS

The present study was carried out in the Dept of orthodontics and dentofacial orthopedics, Buddha Institute of Dental Sciences and Hospital, Patna, during the period from July 2014 to January 2016. It comprised of 120 patients with class II malocclusion. All were required to undergo extraction of maxillary first molar extraction followed by distalization of canine. All had good periodontal status with minimal bone loss and attachment loss. All were informed regarding the study and written consent was obtained. Ethical clearance was obtained prior to the study. General information such as name, age, gender etc. was recorded. Before canine distalization and after the alignment and leveling phases, piezocision was performed on experimental side (Group I). The distalization phase was initiated after piezocision on the experimental side using elastomeric chains. For the control side (Group II), distalization was started at the same time with the same mechanics. Patients were examined at 2-week intervals, and the elastomeric chains were replaced at each appointment until ideal Class I canine relationships were established. Both canines of each patient were planned to be distalized in terms of millimeters. Tooth mobility and gingival index was assessed on both sides. Results thus obtained were subjected to statistical analysis. P value less than 0.05 was considered significant.

### RESULTS

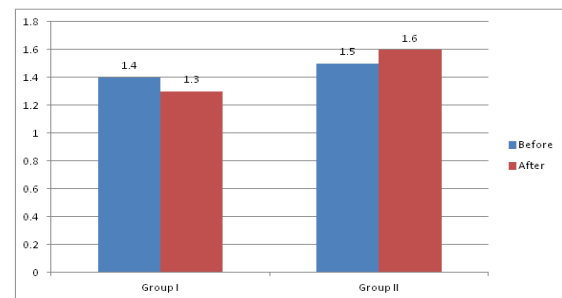
**Table 1: Period of canine distalization in both groups**

Groups	Group I	Group II	P value
Period (months)	3.56± 1.4	5.61± 1.2	0.05
Amount of distalization (mm)	1.54± 1.3	0.80± 1.1	0.01



**Figure 1: Mobility score in both groups**

[Table 1] shows that in group I, there was 3.56± 1.4 months and in group II there was 5.61± 1.2 months for distalization. There was 1.54± 1.3 mm and 0.80± 1.1 mm distalization in group I and group II. The difference was significant (P< 0.05). Graph I shows that mobility score was 1.2 and 1.4 before and after distalization in group I and 1.3 and 1.5 before and after distalization in group II. The difference was non- significant (P> 0.05). Graph II shows that gingival index score was 1.4 and 1.3 before and after distalization in group I and 1.5 and 1.6 before and after distalization in group II. The difference was non- significant (P> 0.05).



**Figure 2: Gingival index score**

### DISCUSSION

Piezocision can be used to accelerate orthodontic treatment in a generalized, localized or sequential manner, enhance the scope of tooth movement through grafting (i.e., posterior buccal expansion, decrowding without extractions due to the increased alveolar volume); achieve differential tooth movement by altering anchorage value through changing the bone density at certain areas; enhance the patient's profile in certain cases by altering the labiomental fold; repair the alveolar cortical bone fenestrations and dehiscences, and improve the periodontium strength by adding hard or soft tissue grafting and possibly enhance the stability of the orthodontic treatment through stronger alveolar cortices, when grafted.<sup>[5]</sup> The use of piezosurgery in conjunction with the conventional flap elevations is effective to create an environment conducive to rapid tooth movement. Although effective, these techniques require flap elevations. They have the potential to generate post-surgical discomfort as well as post-operative complications.<sup>[6]</sup>

In present study, in group I, there was 3.56± 1.4 months and in group II there was 5.61± 1.2 months for distalization. There was 1.54± 1.3 mm and 0.80± 1.1 mm distalization in group I and group II. The mobility score was 1.2 and 1.4 before and after distalization in group I and 1.3 and 1.5 before and after distalization in group II. This is in agreement with Akash et al.<sup>[7]</sup>

The major novelty is the one-sided approach only from the buccal side; there is no requirement for

intervention from the palatal or lingual side. Placement of incisions around the tooth is necessary when rapid movement is planned. Furthermore, RAP is a transient phenomenon; therefore, patients must be evaluated every 2 weeks during treatment. The effects of RAP can diminish with a decrease in tooth movement velocity over time, although the effects have been reported to last for approximately 4 months.<sup>[8]</sup>

A study by Hartik et al,<sup>[9]</sup> found that three-dimensional analysis of the models revealed significant differences in tooth movement (lesser anchorage loss and greater canine distalization) between the experimental and control groups. Furthermore, the distalization time was shortened in the experimental group. There were no differences in the transversal changes, pre- and postdistalization gingival indices, or mobility scores between groups.

Piezocision is performed 1 week after the placement of orthodontic appliances. The patient is anesthetized using Xylocaine 2% with 1/100 000 epinephrine in infiltration. Once complete anesthesia is achieved, a small vertical incision is performed buccally and interproximally in the attached gingiva or mucosa. The incision into the attached gingiva is preferable as it will give less visible postoperative scarring. A mid-level incision between the roots of the teeth involved is made, keeping in mind that the soft tissues and the periosteum need to be cut to create an opening that will allow for the insertion of the piezoelectric knife.<sup>[10]</sup> Aksakalli S et al compared the extent of canine distalization and the transversal changes, postdistalization gingival indices, and mobility scores between patients who were undergoing orthodontic treatment involving upper premolar extraction with (experimental group) or without piezocision. Twenty maxillary canines of 10 patients were evaluated with split mouth design. Pre- and postdistalization dental casts were prepared and scanned with an orthodontic scanner to compare the extent of distalization and transversal changes between the two groups. The pre- and postdistalization gingival indices and mobility scores were also calculated. Three-dimensional analysis of the models revealed significant differences in tooth movement (lesser anchorage loss and greater canine distalization) between the experimental and control groups. Furthermore, the distalization time was shortened in the experimental group. There were no differences in the transversal changes, pre- and postdistalization gingival indices, or mobility scores between groups. Piezocision-assisted distalization accelerates tooth movement, decreases the anchorage loss for posterior teeth, and does not induce any maxillary transversal change. Moreover, piezocision does not have any adverse effects on periodontal health.<sup>[11]</sup>

## CONCLUSION

Piezocision-assisted distalization accelerates tooth movement, decreases the anchorage loss for posterior teeth, and does not induce any maxillary transversal change. This technique does not have any adverse effects on periodontal health.

## REFERENCES

1. Alikhani M, Raptis M, Zoldan B, et al. Effect of microosteo perforations on the rate of tooth movement. *Am J Orthod Dentofacial Orthop.* 2013;144:639–648.
2. Kim YS, Kim SJ, Yoon HJ, Lee PJ, Moon W, Park YG. Effect of piezopuncture on tooth movement and bone remodeling in dogs. *Am J Orthod Dentofacial Orthop.* 2013;144:23–31.
3. Kim SJ, Moon SU, Kang SG, Park YG. Effects of low-level laser therapy after corticision on tooth movement and paradental remodeling. *Lasers Surg Med.* 2009;41:524–533.
4. Dibart S, Surmenian J, Sebaoun JD, Montesani L. Rapid treatment of Class II malocclusion with piezocision: two case reports. *Int J Periodontics Restorative Dent.* 2010;30:487–493.
5. Frost HM. The biology of fracture healing: an overview for clinicians. Part II. *Clin Orthop Relat Res.* 1989; 294–309.
6. Frost HM. The biology of fracture healing: an overview for clinicians. Part I. *Clin Orthop Relat Res.* 1989;283–293.
7. Dixon V, Read MJ, O'Brien KD, Worthington HV, Mandall NA. A randomized clinical trial to compare three methods of orthodontic space closure. *J Orthod.* 2002; 29:31–36.
8. Kanuru RK, Azaneen M, Narayana V, Kolasani B, Indukuri RR, Babu PF. Comparison of canine retraction by in vivo method using four brands of elastomeric power chain. *J Int Soc Prev Community Dent.* 2014;4:S32–S37.
9. Hoggan BR, Sadowsky C. The use of palatal rugae for the assessment of anteroposterior tooth movements. *Am J Orthod Dentofacial Orthop.* 2001;119:482–488.
10. Sukurica Y, Karaman A, Gurel HG, Dolanmaz D. Rapid canine distalization through segmental alveolar distraction osteogenesis. *Angle Orthod.* 2007;77:226–236.
11. Aksakalli S1, Calik B2, Kara B2, Ezirganli S3. Accelerated tooth movement with piezocision and its periodontal-transversal effects in patients with Class II malocclusion. *Angle Orthod.* 2016 Jan;86(1):59-65. doi: 10.2319/012215-49.1. Epub 2015 May 19.

**How to cite this article:** Pandey V, Chandra S, Biswas N, Kumar S, Singh S, Kumar M. Assessment of Tooth Movement with Piezocision and Its Periodontal Transversal Effects in Class II Malocclusion Patients: A Clinical Study. *Ann. Int. Med. Den. Res.* 2018; 4(5):DE24-DE26.

**Source of Support:** Nil, **Conflict of Interest:** None declared