

# Management of Single Rooted Mandibular First Molar A Rare Entity –A CBCT Analysis

C. K. Anil<sup>1</sup>, Harikumar Vemisetty<sup>1</sup>, Jayaprada Reddy Surakanti<sup>1</sup>, Jaya Nagendra Krishna Muppalla<sup>1</sup>, Navya poojitha Sajja<sup>1</sup>, Mahesh. M<sup>2</sup>

<sup>1</sup>Department of Conservative Dentistry and Endodontics, Kamineni Institute of Dental Sciences, Narketpally, Nalgonda-508254, Telangana.

<sup>2</sup>Consultant Oral and Maxillofacial Radiologist.

Received: October 2018

Accepted: October 2018

**Copyright:** © the author(s), publisher. It is an open-access article distributed under the terms of the Creative Commons Attribution Non-Commercial License, which permits unrestricted non-commercial use, distribution, and reproduction in any medium, provided the original work is properly cited.

## ABSTRACT

The case report here tries to describe the rare variation of root canal morphology in a mandibular first molar, which is rare in occurrence in literature. This case report presents a relatively rare case of mandibular first molar with single root and a single root canal in a 24-year-old female patient. Cone-beam computed tomography (CBCT) was employed to confirm the extension of the unusual anatomy. Ambiguity in the canal morphology of the first molar is quite common. Knowledge of variations in internal anatomy of teeth is important for success in endodontic treatment. Root canal morphology is limitless in its variability and clinicians must be aware that anatomic variations constitute a formidable challenge to endodontic success. Hence, clinicians have to take utmost care when these cases with single canal and single root come in our practice.

**Keywords:** Morphology, Single canal, Mandibular first molar, CBCT, Anatomical variations.

## INTRODUCTION

The mandibular first molar is the first permanent tooth that erupts and most often requires root canal treatment. Normally, the permanent mandibular first molar exhibits two roots and three root canals. Despite its several variations of single or double roots with multiple root canals in the mesial root, there have been very few literatures showing single root with single canal in mandibular first molars<sup>1</sup>. All these published reports discussed the cases with more number of roots or canals than normal.<sup>[2-5]</sup> In 2006, Gopikrishna et al.<sup>[6]</sup> reported a case of maxillary first molar having a single root with a single canal. Existence of a single root and single canal is an extremely a rare finding and only two cases have been reported in the existing literature.<sup>[7,8]</sup> The aim of this article is to present a case report of such rare entity of left mandibular first molar with a single root and root canal encompassing successful nonsurgical endodontic management.

### Name & Address of Corresponding Author

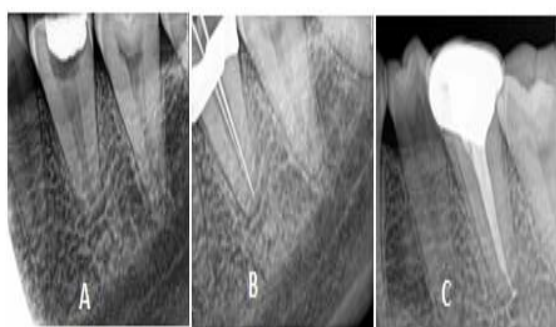
C. K. Anil,  
Department of Conservative Dentistry and Endodontics,  
Kamineni Institute of Dental Sciences,  
Narketpally, Nalgonda-508254,  
Telangana, India.

A 24-year-old female patient reported to department of conservative dentistry and endodontics with the chief complaint of spontaneous toothache in her left lower back region of the mouth since 2 days. Past medical and dental history was non contributory Clinical examination revealed a deep occlusal carious lesion involving left mandibular first molar (36 - FDI Nomenclature). The tooth was non mobile and periodontal probing around the tooth was within physiological limits. Vertical percussion test had a positive response on comparison with adjacent and contra lateral teeth. Sensitivity tests of the involved tooth with heated Gutta-percha (Dentsply Maillefer, Switzerland) and dry ice (R C Ice; Prime Dental Products, India) caused an intense lingering pain, whereas electronic pulp stimulation (Parkel Electronics Division, Farmingdale, New York, USA) caused an exaggerated response. A preoperative intraoral periapical radiograph revealed radiolucency approaching the pulp space, break in continuity of lamina dura and diffuse periapical radiolucency. Multiple angulated radiographs confirmed the presence of single root. CBCT (Carestream CS9300, 85kV, 8mA, 19.96s) was advised for further investigations to determine and confirm the root canal morphology. CBCT evaluation revealed that the left mandibular first molar showed single root with single canal. From the clinical and radiographic examination, a

## CASE REPORT

diagnosis of acute peri-radicular abscess with 36 was made. A nonsurgical endodontic treatment was suggested to the patient and written consent obtained.

The tooth was anesthetized with 1.8 ml of 2% lignocaine containing 1:200,000 epinephrine (Xylocaine; AstraZeneca Pharma India Ltd.). After rubber dam isolation, caries excavation was done using no. 4 round bur. Conventional endodontic access cavity was established using endo access bur (Dentsply Tulsa, Tulsa, OK) followed by flaring with the help of endo Z bur (Dentsply Tulsa, Tulsa, OK). A single large canal was present at the centre of the pulp chamber (named as central canal "Cn") which was confirmed by dental operating microscope.



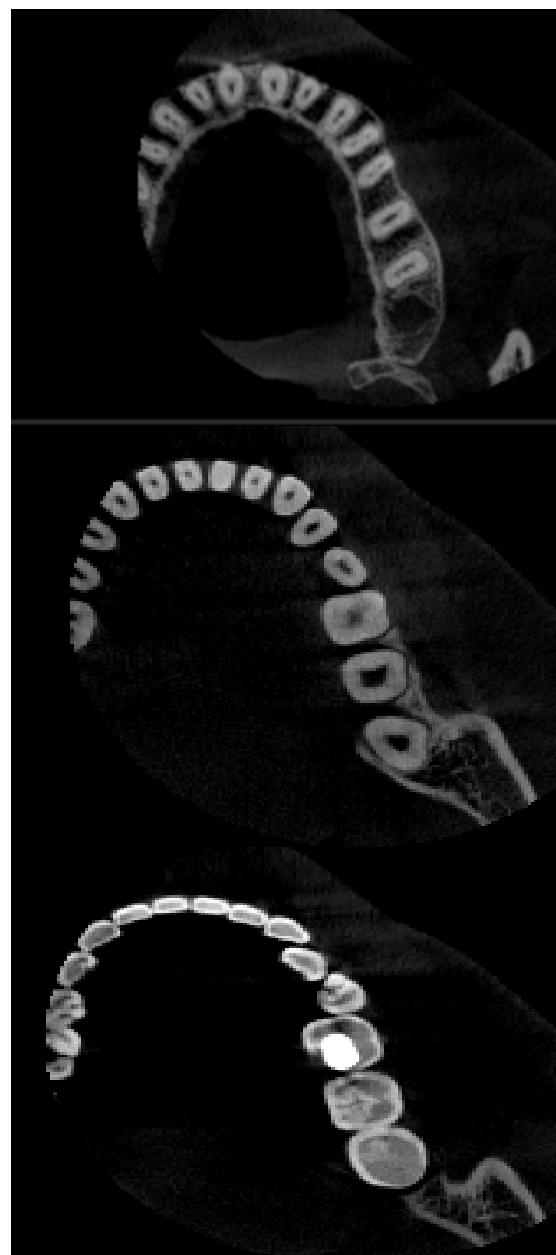
**Radiographs, A: Access Cavity Preparation Done, B: Working Length Determination, C: Post Obturation**

The working length was determined by apex locator (Root ZX II, Morita, Tokyo, Japan) and confirmed by using a no.15 K file (Mani Inc, Tochigi-Ken, Japan) on a radiograph. Cleaning and shaping was performed using step back technique and apical preparation was done with no.60 k file. Irrigation was performed using normal saline, 3% sodium hypochlorite solution, and 17% ethylenediaminetetraacetate; 2% chlorhexidine digluconate was used as the final irrigant. Calcium hydroxide paste was given as an intracanal medicament and access cavity was sealed with intermediate restorative material (Dentsply, Mumbai, India). Patient was reviewed after 2 weeks.

On recall, the root canal was irrigated using the same above irrigants and dried with absorbent points (Dentsply Maillefer). Obturation of the canal was done by thermoplasticized injectable gutta-percha technique (Obtura II, Obtura Corporation) and AH plus resin sealer (Maillefer Dentsply, Konstanz, Germany). After completion of root canal treatment, the tooth was restored using posterior resin composite (3M Dental Products, St. Paul, MN, USA). The patient was asymptomatic during the follow-up period of 3 months.

Later, CBCT was advised to determine the obturation of the single root canal morphology which showed a complete obturation with no

evidence of any pathology. The patient was advised a full-coverage porcelain crown.



**CBCT images**

## DISCUSSION

The mandibular first molar is a frequently treated tooth and has a wide variety of root canal configurations. Variations in the morphology of the dental pulp are caused by genetic and environmental influences, and there is very definite need for clinicians to be made aware of the frequency of racially determined form<sup>9</sup>. Until date, only three cases of mandibular first molar with single canal have been reported. Vakebcua De Pablo et al, in 2010 and Ballulaya et al,<sup>[10]</sup> in 2013 have done a systematic review of the literature on canal morphology of the mandibular first molar.<sup>[11]</sup>

But both of them have not recorded this rare morphology. Recently Sooriaprakas et al,<sup>[7]</sup> found a single rooted mandibular first molar in a 28-year-old male patient belonging to South India. From this fact, it is evident that future studies are highly essential to provide more knowledge on the existence of mandibular first molar with single root or canal in other ethnic groups, which is highly important from anthropologic as well as forensic point of view.<sup>[12]</sup>

Ramamurthy and Srinivasan,<sup>[13]</sup> Winkler and Ahmad found bilateral occurrence of three rooted primary mandibular first molars.<sup>[14]</sup> Acs et al.,<sup>[15]</sup> reported combination of three rooted primary second molars, talon cusp, shovel incisors and supernumerary tooth in a 7-year-old Hispanic male patient. Recently, Nagaveni et al.,<sup>[16]</sup> documented two cases of three rooted primary mandibular molar teeth in Indian patients. The present article shows presence of this unusual clinical entity in association with a single rooted permanent first molars and tooth agenesis.

Normally development of roots begins after enamel and dentin formation has reached the future cemento-enamel junction. Prior to root formation, the root sheath forms the epithelial diaphragm which will grow horizontally and cover the wide cervical opening into narrow apical foramen. In multi-rooted teeth the epithelial diaphragm undergoes differential growth, which causes the division of the root trunk into two or three roots. Depending on the number of divisions, number of the roots will be formed. In multi-rooted teeth, the epithelial diaphragm is genetically programmed to undergo differential growth, but under the rarest condition this differential growth may fail to take place and this may give rise to the formation of single rooted mandibular first molar. Genetically programmed differential growth has occurred in this patient leading to the development of single rooted permanent molars. This relatively harmless condition can provide a boon to future genetic research as there is a unique subset of single root in the permanent molar.<sup>[17-19]</sup>

Radiographic examination of the tooth is an important diagnostic tool for identification of any aberrations in the root or canal during root canal treatment. Radiographs taken from a 20° mesial or distal angulation enhances the chances of detecting unusual root canal configurations.<sup>[20]</sup> In this particular case, multiple horizontal angulations radiographs clearly indicated the presence of single root and single canal. However, use of cone-beam computed tomography, a new revolution in the endodontic field is more valuable diagnostic tool in detecting such aberrations as it provides a three-dimensional picture of the root and canals. In the present case, CBCT has been advocated before and after endodontic treatment. Kottoor et al,<sup>[21,22]</sup> and La et al.<sup>[23]</sup> have suggested the use of CBCT for the

purpose of determining the root canal morphology in cases with aberrations.

There were several factors, which were taken into consideration in the management of this single-rooted single canaled mandibular first molar for a better prognosis. Due to large root canal space, proper removal of entire bulky pulp tissue is necessary along with good biomechanical preparation and copious intracanal irrigation. Proper preoperative diagnosis using multiple angled radiographs and correlating them clinically is necessary. Another challenge was obturation of this large pulpal space. The advantage of using a thermoplastized injectable obturating technique is that it ensures compact obturation of the wide canals without voids. Mandibular molars bear a considerable amount of masticatory load which necessitates proper post endodontic management.

## CONCLUSION

The anomalies in the root canal morphology need not always be extra canals. It can also be in the form of fused or fewer canals. This case report highlights the uncommon anatomy of mandibular first molar with a single root and single canal. Careful inspection of the tooth under dental operating microscope and the correct choice of cleaning and shaping technique suitable for this uncommon root canal anatomy helps achieve success in such aberrant cases. In-depth knowledge and meticulous diagnosis of root variations are highly important to achieve success in the root canal treatment.

## REFERENCES

1. Ballullaya SV, Vemuri S, Kumar PR. Variable permanent mandibular first molar: Review of literature. *J Conserv Dent* 2013;16:99-110
2. Durack C, Patel S. Cone beam computed tomography in endodontics. *Braz Dent J*. 2012;23(3):179-91.
3. Martinez-Berna A, Badanelli P. Mandibular first molars with six root canals. *J Endod* 1985; 11:348-352.
4. Reeh ES. Seven canals in a lower first molar. *J Endod* 1998; 24:497-499.
5. Baugh D, Wallace J. Middle mesial canal of the mandibular first molar: A case report and literature review. *J Endod* 2004; 30: 185-186.
6. Gopikrishna V, Bhargavi N, Kandaswamy D. Endodontic management of a maxillary first molar with a single root and a single canal diagnosed with the aid of spiral CT: A case report. *J Endod* 2006;32:687-691
7. Sooriaprakas C, Ballal S, Velmurugan N. Mandibular first molar with a single root and single canal. *Case Rep Dent* 2014;159846.
8. Ioannidis K, Lambrianidis T, Beltes P, Besi E, Malliari M. Endodontic management and cone-beam computed tomography evaluation of seven maxillary and mandibular molars with single roots and single canals in a patient. *J Endod* 2011; 37:103-109.
9. Krithikadatta J, Kottoor J, Karumaran CS, Rajan G. Mandibular first molar having unusual mesial root canal

- morphology with contradictory cone-beam computed tomography findings: A case report. *J Endod* 2010; 36:1712-1716.
10. De Pablo OV, Estevez R, Péix Sánchez M, Heilborn C, Cohenca N. Root anatomy and canal configuration of the permanent mandibular first molar: A systematic review. *J Endod* 2010; 36:1919-1931.
  11. Ballullaya SV, Vemuri S, Kumar PR. Variable permanent mandibular first molar: Review of literature. *J Conserv Dent* 2013; 16:99-110.
  12. N.B. Nagaveni, M. Manoharan, Sneha Yadav, P. Poornima. Single rooted, single canal mandibular first molar in association with multiple anomalies: Report of a rare case with literature review *Nigerian Journal of Experimental and Clinical Biosciences* January-June 2015 Vol 3, Issue 1.
  13. Ramamurthy N, Srinivasan I. Bilateral three-rooted primary lower molars. *Indian J Dent Res* 2012;23:700
  14. Winkler MP, Ahmad R. Multitrooted anomalies in the primary dentition of Native Americans. *J Am Dent Assoc* 1997;128:1009-1011
  15. Acs G, Pokala P, Cozzi E. Shovel incisors, three-rooted molars, talon cusp, and supernumerary tooth in one patient. *Pediatr Dent* 1992; 14:263-264.
  16. Nagaveni NB, Bajaj M, Shruti AS, Poornima P. Radix paramolaris (supernumerary third root) in primary mandibular second molar: Report of two cases. *Niger J Exp Clin Biosci* 2014;2:134-137
  17. Stropko JJ. Canal morphology of maxillary molars: Clinical observations of canal configurations. *J Endod* 1999;25:446-450
  18. Baugh D, Wallace J. Middle mesial canal of the mandibular first molar: A case report and literature review. *J Endod* 2004;30: 185-186
  19. Kottoor J, Sudha R, Velmurugan N. Middle distal canal of the mandibular first molar: A case report and literature review. *Int Endod J* 2010; 43:714-722.
  20. Winkler MP, Ahmad R. Multitrooted anomalies in the primary dentition of Native Americans. *J Am Dent Assoc* 1997;128:1009-1011
  21. Kottoor J, Velmurugan N, Sudha R, Hemamalathi S. Maxillary first molar with seven root canals diagnosed with cone-beam computed tomography scanning: A case report. *J Endod* 2010; 36:915-921.
  22. Kottoor J, Velmurugan S, Surendran S. Endodontic management of a maxillary first molar with eight root canal systems evaluated using cone-beam computed tomography scanning: A case report. *J Endod* 2011; 37:715-719.
  23. La SH, Jung H, Kim EC, Min KS. Identification of independent middle mesial canal in mandibular first molar using cone-beam computed tomography imaging. *J Endod* 2010; 36:542-545.

**How to cite this article:** Anil CK, Vemisetty H, Surakanti JR, Muppalla JNK, Sajja NP, Mahesh M. Management Of Single Rooted Mandibular First Molar A Rare Entity –A CBCT Analysis. *Ann. Int. Med. Den. Res.* 2018; 4(6): DE16-DE19.

**Source of Support:** Nil, **Conflict of Interest:** None declared