

Prevalence of Oral Mucosal Lesions among Tobacco Chewers in North Indian Population.

Pradeep Kumar Jha¹, Md Asad Iqbal², Mobeen Khan³, Hanjala Shafi Rayeen⁴, Nazish Akhtar⁵, Wabi Shafi Rain⁶

¹Reader and Head, Department of Oral Medicine and Radiology, Patna Dental College and Hospital, Patna, Bihar, India.

²Senior Lecture, Department of Oral Medicine and Radiology, Patna Dental College and Hospital, Patna, Bihar, India.

³Senior lecturer, Department of Oral Medicine and Radiology, Chandra Dental College and Hospital Barabanki, Uttar Pradesh, India.

⁴Post Graduate Student, Department of Oral Pathology and Microbiology, Chandra Dental College and Hospital Barabanki, Uttar Pradesh, India.

⁵Senior Lecture, Department of Oral Medicine and Radiology, Seema Dental college and Hospital, Rishikesh, Uttarakhand, India.

⁶Owner of Awadh Dental Clinic Gonda, Uttar Pradesh, India. Ex-Practitioner Makka Hospital, Makka, City-Saudi Arabia.

Received: April 2018

Accepted: May 2018

Copyright: © the author(s), publisher. It is an open-access article distributed under the terms of the Creative Commons Attribution Non-Commercial License, which permits unrestricted non-commercial use, distribution, and reproduction in any medium, provided the original work is properly cited.

ABSTRACT

Background: The oral mucosa acts as a protective barrier against pathogens, and carcinoma causing agents. It can be affected by different lesions and conditions, few of which are harmless, while some may have harmful complications. **Objective:** To study the prevalence of oral mucosal variants & Lesions among tobacco users in North Indian population. **Methods:** A total of 640 subjects consisting of 492 males and 148 females reporting to the outpatient Department of Oral Medicine and Radiology were selected. The subjects were divided into two groups. The first group was control group with subjects not having tobacco chewing habit consisting of 320 subjects including 246 males and 74 females. Another group included tobacco with same no of subjects as that of control group. All subjects were examined for presence of oral mucosal variants in accordance with the WHO acknowledged coloured atlas, clinical examination and history. **Results:** Prevalence of oral mucosal variants was found to be 75.0% among tobacco chewers. Males were more affected (70.0%) than the females. The maximum no of cases reported were in the age group of 20-40 years. Leukoplakia was the most common oral mucosal lesion among tobacco chewers. **Conclusion:** Tobacco chewing can be considered to be a concerned habit and necessary public health programmes should be taken to eradicate this habit.

Keywords: Oral Mucosal Variants, Tobacco Chewers, Premalignant lesion.

INTRODUCTION

The oral mucosa acts as a protective barrier against pathogens, and carcinoma causing agents. It can be affected by different lesions and conditions, few of which are harmless, while some may have harmful complications. Diagnosis and treatment of these pathologies are an integral part of overall oral health care. Hence, oral mucosal tissue examination is important, and it should be done in a organized manner to include all parts of the oral cavity.^[1]

Tobacco consumption is one of the most important harmful factors for the origin of oral mucosal lesions including oral pre-cancer as well as cancer.^[2] In recent years, several commercial preparations in the form of pan masala and gutkha

are easily available in India as well as many other parts of Asia. Most brands of these products contain areca nut and tobacco, both of which have been found to play active role in occurrence of oral cancer. The researchers have also found that smoking and chewing of tobacco along with betel quid act concurrently in oral carcinogenesis and persons having mixed habits form a usually high-risk population.^[3]

Adequate management of a subject with an oral lesion begins with an accurate diagnosis. There are lesions which can be diagnosed on data gathered during the history and/or physical examination. However there are others which need further confirmation by specialized procedures. Among the several methods available for diagnosing oral mucosal lesions, the histopathological examination of a biopsy of tissue of the suspected lesion is regarded as the most suitable method.^[4] Various studies to assess the distribution of oral mucosal lesions are helpful and valuable in estimating the prevalence of a disease in the population. This help in identifying high risk sub-population and

Name & Address of Corresponding Author

Dr. Mobeen Khan
Senior lecturer,
Department of Oral Medicine and Radiology,
Chandra Dental College and Hospital Barabanki,
Uttar Pradesh, India.

guidance in carrying out preventive and curative services.^[5]

There have been less studies that inform about the prevalence of tobacco habits and associated oral changes in north India population. The purpose of this study was to investigate the prevalence of oral mucosal variants in individuals having habit of smoking and chewing tobacco and to assess the relative risk of oral mucosal lesions resulting from these habits in north Indian population.

MATERIALS AND METHODS

A total of 640 subjects consisting of 492 males and 148 females were involved in the study after obtaining their written informed consent. The participants were categorized into two groups. The first group acted as control group with 320 subjects including 246 males and 74 females who were not identified with the habit of tobacco use. The second group consisted of subjects with tobacco use. Before starting the study consent was obtained from the ethical committee.

The subjects who belonged to age between 15 to 65 years were included in the study. The subjects being included in tobacco user group consisted of subjects with habit of chewing and smoking tobacco for more than 5 years. Only those subjects were included who had habit with a frequency ≥ 5 times each day. The subjects in which intraoral examination was not possible due to reduced mouth opening were excluded from the study.

All subjects were examined for presence of oral mucosal variants. The diagnosis was made on the basis of proper history and clinical examination in accordance with the WHO acknowledged coloured atlas and criteria for different oral mucosal variants. The results achieved were analyzed with the help of SPSS (Statistical Package for Social Services) 18.0 version.

RESULTS

The control group consisted of 246 males and 74 females. Only 1.62% cases of Oral mucosal variants were noticed in male subjects [Table 1] while 2.76% cases of oral mucosal variant were detected in female subjects [Table 2].

The group consisting of tobacco users included 246 males and 74 females. In male subjects, 75.6% cases of oral mucosal variants were noticed. Leukoplakia was the most common oral mucosal lesion observed (27.95). It was found that maximum cases of oral mucosal variants were found in age group of 36-45 years contributing to 38.21% cases. It was then followed by 46-55 years of age having 18.69 % cases. It was reported that among subjects belonging to 15-35 years age group 10.6 % cases were reported. However, minimum no of cases (8.13%) was noticed among the subjects

belonging to the age group of 56-65 years. [Table 3 & Figure 1]

In female tobacco chewers subjects 70.27% cases of oral mucosal variants were noticed. Leukoplakia was the most common oral mucosal lesion noticed. It was found that maximum no of oral mucosal variants were found in age group of 36-45 years contributing to 27.02% cases. Then it was followed by 15-35 years age group in which 16.21 % findings of oral mucosal variants were observed. However 13.51% of oral mucosal variants were noticed in both the age groups of 46-55 years as well as 56-65 years. [Table 4 & Figure 2]

Table 1: Oral Mucosal Variants in Males in Control Group

S. No	Age Group	Oral Mucosal Variants (%)
1.	15-35	0.81
2.	36-45	00
3.	46-55	00
4.	56-65	0.81
Total	246	1.62

Table 2: Oral Mucosal Variants in Females in Control Group.

S. No	Age Group	Oral Mucosal Variants (%)
1.	15-35	2.76
2.	36-45	00
3.	46-55	00
4.	56-65	00
Total	74	2.76

Table 3: Distribution of Oral Mucosal Variants and Lesions in Tobacco Users

S. No	Oral Mucosal Variants & Lesions	Percentage (%)
1.	Leukoedema	10.75
2.	Fordyce Granules	7.52
3.	Lichen Planus	16.12
4.	OSMF	19.35
5.	Leukoplakia	27.95
6.	Candidiasis	10.75
7.	Traumatic Keratosis	7.52

Table 4: Oral Mucosal Variants & Lesions in Males in Tobacco Users

S. No	Age Group	Oral Mucosal Variants & Lesions (%)
1.	15-35	10.56
2.	36-45	38.21
3.	46-55	18.69
4.	56-65	8.13
Total	246	75.60

Table 5: Oral Mucosal Variants & Lesions in Females in tobacco users

S. No	Age Group	Oral Mucosal Variants & Lesions (%)
1.	15-35	16.21
2.	36-45	27.02
3.	46-55	13.51
4.	56-65	13.51
Total	74	70.27

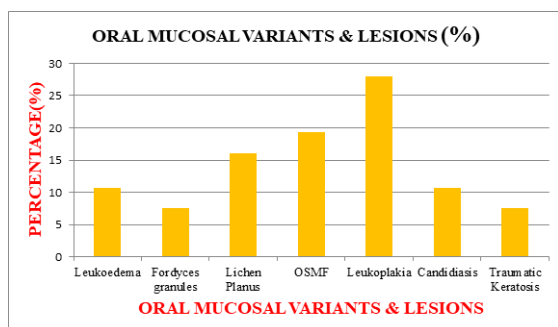


Figure 1: Distribution of Oral Mucosal Variants and Lesions In Tobacco Users

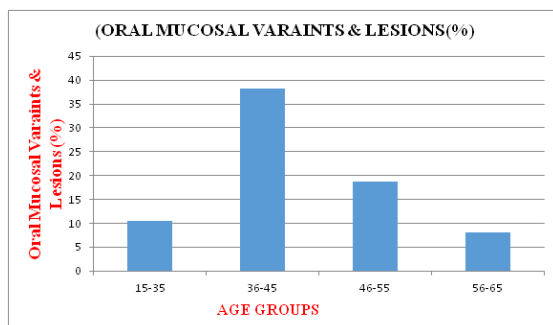


Figure 2: Oral Mucosal Variants & Lesions in Males in Tobacco Users

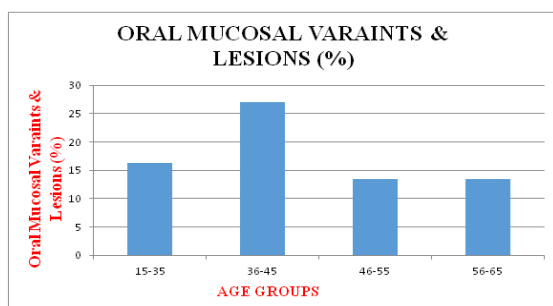


Figure 3: Oral Mucosal Variants & Lesions in Females in Tobacco Users

DISCUSSION

In our study, the prevalence of oral mucosal variants was 75.6%, which is similar to results of previous studies carried out by Cadugo et al,^[6] Kovac- Kovacic.^[7] The prevalence of oral mucosal variant was found out to be 83.6% in Thailand and 81.3% in Italy.^[8,9] It was slightly higher than that reported here. The reason can be attributed to fact that these studies were confined to populations of specific age and gender. The prevalence of oral mucosal variants was found in studies by Pentenero et al,^[10] to be 25.1% and Mehrotra et al.^[11] to be 8.4%, was found to be quite lower than that observed in our study. The reason for such observation can be exclusion of harmless oral mucosal conditions and inclusion of significant oral mucosal lesions only.

Similar to reports of previous studies, our study showed a higher prevalence of oral mucosal lesions

among age group of adults (36-45), which indicates the importance of routine examination of the oral mucosa, particularly adult age patients. We also observed a higher prevalence of oral mucosal lesions among tobacco users. Al-Shammari et al have found smoking tobacco to be a common habit among people of Kuwait and that they have significantly less knowledge regarding the negative effects of smoking over oral health than non smokers. Besides, most of them said that they would consider leaving the habit if an association between smoking and poor oral health is proven to them.^[12]

In the present study among the various oral mucosal variants the most prevalent lesion was found out to be Leukoplakia (27.95%). It was more than that reported in the previous studies.^[13] This difference can be explained on the basis of the difference in the study population as well as the difference in the tobacco habits of Indian and western populations.. In present study, leukoplakia was more commonly observed in men with smoking and mixed (smoking and chewing) habits as compared with females. This can be attributed to less number of women smokers. Findings of previous studies like our study also supports an association between tobacco use habits and leukoplakia.^[14]

The prevalence of oral lichen planus observed in the present study was 16.2% in subjects with tobacco habits and very few cases among subjects with no tobacco habits. This finding is similar to that observed in previous studies. Axell and Rundquist indicated that snuff users revealed a slightly higher prevalence of lichen planus than tobacco smokers.^[15] However, Mani observed no relationship between lichen planus and oral tobacco habits.^[16] Lichen planus in tobacco and betel users should not be ignored, even though malignant transformation potential of this lesion remains somewhat uncertain, because tobacco habits can influence the natural history of oral lichen planus.

As compared with previous studies the prevalence of Oral Submucous Fibrosis (OSMF) in the present study was quite high 19.3%.^[17] This should be attributed to the increased prevalent habit of chewing gutkha and betel quid in this region. The majority of subjects with OSMF were aged between 36 and 45 years, which should be related to the habit common in this age group of chewing gutkha and areca nut. Our study gives strong association between various oral mucosal variants and the tobacco habits in the north Indian population.

CONCLUSION

Tobacco chewing can be considered to be a concerned habit and necessary public health programmes should be taken to eradicate this habit.

Although most of oral mucosal variants are asymptomatic, the oral physician should be especially equipped with knowledge to identify and separate them from precancerous lesions posing danger in the future, and start to treat them with proper planning and prevention of tobacco use which in recent years has emerged as a important predisposing factor for such lesions.

Acknowledgement

Authors acknowledge the immense help received from the scholars whose articles are cited and included in reference of this manuscript. The authors are grateful to authors / editors / publishers of all those articles, journal and books from where the literature for this article has been reviewed and discussed.

REFERENCES

- Castellanos JL, Diaz-Guzman L. Lesions of the oral mucosa: an epidemiological study of 23785 Mexican patients. *Oral Surg. Oral Med. Oral Pathol. Oral Radiol. Endod.* 2008; 105, 79–85.
- Winn DM. Tobacco use and oral disease. *J Dent Educ.* 2001;65:306–12.
- Ko YC, Huang YL, Lee CH, Chen MJ, Lin LM, Tsai CC. Betel quid chewing, cigarette smoking and alcohol consumption related to oral cancer in Taiwan. *J Oral Pathol Med.* 1995;24:450–3.
- Malaovalla AM, Silverman S, Mani NJ, Bilimoria KF, Smith LW. Oral cancer in 57,518 industrial workers of Gujarat, India: a prevalence and follow-up study. *Cancer.* 1976;37:1882-6.
- Mikkonen M, Nyyssönen V, Paunio I, Rajala M. Prevalence of oral mucosal lesions associated with wearing removable dentures in Finnish adults. *Community Dent Oral Epidemiol.* 1984;12:191-4.
- Cadugo MA, Chua MG, Feliciano MA, Jimenez FC, Uy, HG. A preliminary clinical study on the oral lesions among the Dumagats. *J. Philipp. Dent. Assoc.* 1998;50:36–42.
- Kovac-Kovacic M, Skaleric U. The prevalence of oral mucosal lesions in a population in Ljubljana. *Slovenia J. Oral Pathol. Med.* 2000;29, 331–335.
- Jainkittivong, A., Aneksuk, V., Langlais, R.P., 2002. Oral mucosal conditions in elderly dental patients. *Oral Dis.* 8, 218–223.
- Campisi G, Margiotta V. Oral mucosal lesions and risk habits among men in an Italian study population. *J. Oral Pathol. Med.* 2001;30:22–28.
- Pentenero M, Broccoletti R, Carbone M, Conrotto D, Gandolfo S. The prevalence of oral mucosal lesions in adults from the Turin area. *Oral Dis* 2008.; 14: 356–366.
- Mehrotra R, Thomas S, Nair P, Pandya S, Singh M, Nigam NS, Shukla P. Prevalence of oral soft tissue lesions in Vidisha. *BMC Res. Notes* 2010; 3: 23.
- Al-Shammari KF, Moussa MA, Al-Ansari JM, Al-Duwairy YS, Honkala EJ. Dental patient awareness of smoking effects on oral health: comparison of smokers and non-smokers. *J. Dent.* 2006; 34: 173–178.
- Lay KM, Sein K, Myint A, Ko SK, Pindborg JJ. Epidemiologic study of 6000 villagers of oral precancerous lesions in Bilugyum: Preliminary report. *Commun Dent Oral Epidemiol.* 1982;10:152–5.
- Campisi G, Margiotta V. Oral mucosal lesions and risk habits among men in an Italian study population. *J Oral Pathol Med.* 2001;30:22–8.
- Axell T, Rundquist L. Oral lichen planus-A demographic study. *Community Dent Oral Epidemiol.* 1987;15:52–6.
- Mani NJ. Preliminary report on prevalence of oral cancer and precancerous lesions among dental patients in Saudi Arabia. *Commun Dent Oral Epidemiol.* 1985;13:247–8.
- Bhowate RR, Rao SP, Hariharan KK, Chinchkhede DH, Bharambe MS. New Delhi: Allied Publishers Limited; 1994. Oral mucosal lesions among tobacco chewers: A community based study. Preventive section in XVI International Cancer Congress, Abstract Book-1; p. 435.

How to cite this article: Jha PK, Iqbal MA, Khan M, Rayeen HS, Akhtar N, Rain WS. Prevalence of Oral Mucosal Lesions among Tobacco Chewers in North Indian Population. *Ann. Int. Med. Den. Res.* 2018; 4(4):DE17-DE20.

Source of Support: Nil, **Conflict of Interest:** None declared