

Prevalence and Distribution of Odontogenic Cysts in Kashmiri Population: A Retrospective Clinical Study of 152 Cases.

Mubashir Younis¹, Ajaz Ahmed Shah², Abina Rashid³, Muneet Kapoor¹, Imran Bhat⁴

¹Post Graduate, Department of Oral and Maxillofacial Surgery, Govt. Dental College, Srinagar, J&K, India.

²Professor, Department of Oral and Maxillofacial Surgery, Govt. Dental College, Srinagar, J&K, India.

³Post Graduate, Department of conservative Dentistry and Endodontics, AECS Maaruti Dental College, Bangalore, Karnataka, India.

⁴House Surgeon, Department of Oral and Maxillofacial Surgery, Govt. Dental College, Srinagar, J&K, India.

Received: April 2018

Accepted: April 2018

Copyright: © the author(s), publisher. It is an open-access article distributed under the terms of the Creative Commons Attribution Non-Commercial License, which permits unrestricted non-commercial use, distribution, and reproduction in any medium, provided the original work is properly cited.

ABSTRACT

Background: The main purpose of this study was to determine the prevalence of odontogenic cysts in Kashmiri population. **Methods:** The data on odontogenic cysts (OCs) treated in the department of Oral and Maxillofacial Surgery Government Dental College Srinagar from January 2011 to December 2016 was collected retrospectively. The information regarding patient's age, sex, location of the cyst and the type of the odontogenic cyst was recorded and analysis was done using descriptive statistics. **Results:** A total of 152 OCs were identified out of which 87 were male and 65 female with male to female ratio of 1.3:1. The OCs were seen to predominate in the second, third and fourth decades of life, the most common anatomic location being the mandibular posterior region (40.8%). Radicular cyst dominated among the OCs (50.6 %) followed by dentigerous cyst (23%), odontogenic keratocyst (10.5%), residual cyst (8.6 %), lateral periodontal cyst (5.3 %) and paradental cyst (1.9 %). Radicular cysts most frequently involved the maxillary anterior region (33.8%) while as dentigerous cysts and odontogenic keratocysts were more common in the mandibular posterior region (54.3% and 56.3% respectively). **Conclusion:** Radicular cyst and dentigerous cyst are the most prevalent odontogenic cysts in Kashmiri population; etiology being the dental decay (pulpal necrosis) and impacted teeth. In order to decrease the prevalence of radicular and dentigerous cysts, preventive measures need to be taken to diminish dental decay and programs of prophylactic extractions of impacted teeth need to be established.

Keywords: Odontogenic cysts, Benign swellings.

INTRODUCTION

A cyst is defined as a pathologic cavity containing fluid, semifluid or gaseous contents that are not created by the accumulation of pus; frequently but not always, is lined by epithelium. Based on their origin, Odontogenic cysts (OCs) are divided into two groups: developmental and inflammatory. Odontogenic cysts arise from odontogenic epithelium and its remnants and occur in the tooth-bearing regions of the jaws.^[1] The most commonly occurring odontogenic cysts are radicular and dentigerous cysts and their diagnosis is relatively easy.^[2] In 2005, World Health Organization (WHO) reclassified odontogenic keratocyst as a

classified as a tumor and was renamed calcifying Cystic Odontogenic Tumor.^[3] For this reason these classifications produced some changes in frequency and prevalence of odontogenic cysts and tumors.^[4] Most of these cysts resemble each other clinically and radiographically hence there is every possibility of clinical misdiagnosis. Some of the cysts are known for their aggressive behavior and tendency to recur, so correct diagnosis of these lesions is very essential.^[5] Therefore the surgically excised specimen should be subjected to histopathological examination to get a proper diagnosis which ensures an appropriate treatment. Thus the aim of the study was to determine the prevalence and distribution of OCs that were diagnosed by histopathological examination from January 2011 to December 2016 in Kashmiri population.

Name & Address of Corresponding Author

Dr. Mubashir Younis
Post Graduate, Department of Oral and Maxillofacial Surgery, Govt. Dental College,
Srinagar, J&K,
India.

tumor and renamed it keratocystic odontogenic tumor, while calcifying odontogenic cyst was also

MATERIALS AND METHODS

After obtaining ethical clearance from the Ethical Committee of Government Dental College Srinagar, data regarding patients diagnosed as cases of OCs between January 2011 and December 2016 was collected from the office records. The cases diagnosed as OCs were only included in the study. The data was analysed and the information regarding age, sex and anatomic location of all OCs was compiled along with the biopsy reports. Hematoxylin/eosin-stained slides of OCs or nonspecific cyst diagnoses were re-evaluated and selected according to the 2005 World Health Organization (WHO) histologic classification.^[6] Clinical and radiographic findings were taken into consideration whenever an accurate diagnosis could not be made through histopathologic examination alone. In cases of inadequacy of sample or when the original slides were not representative, new additional slides were prepared from paraffin blocks. The mean age, male: female ratio, anatomic location and the type of OC were determined for each case. The anatomic location was again sub classified as anterior (considered

from right upper canine to left upper canine in case of maxilla and from right lower canine to left lower canine in case of mandible) and posterior (considered the area from the first bicuspid to the third molar, irrespective of whether it was right or left) for each mandible and maxilla. Microsoft Excel TM software was used for data analysis and construction of the tables and graphs.

RESULTS

A total of 1235 cases were reviewed from January 2011 to December 2016, out of which 152 were diagnosed as OCs. Therefore, OCs represented 12.3% of all cases. Out of the 152 OC cases, 87 (57.2%) were males and 65 (42.8%) were females with male to female ratio of 1.3:1 [Table 1] and graphically represented by [Figures 1 and 2]. Majority of the cases were seen in the 3rd decade of life (29 cases= 19.1%) followed by 2nd and 4th decades (27 cases each=17.7%) and least number of cases were seen in first decade (5 cases=3.3%).

Table 1: Distribution of different OCs according to gender

Type Of Cyst	Total	Male Prevalence	Female Prevalence
Radicular Cyst	77 (50.6%)	42 (27.6%)	35 (23%)
Dentigerous Cyst	35 (23%)	21 (13.8%)	14 (9.2%)
Odontogenic Keratocyst	16 (10.5%)	10 (6.6%)	6 (3.9%)
Residual Cyst	13 (8.6%)	6 (3.9%)	7 (4.6%)
Lateral Periodontal Cyst	8 (5.3%)	6 (3.9%)	2 (1.3%)
Paradental Cyst	3 (1.9%)	2 (1.3%)	1 (0.7%)
Total	152 (100%)	87 (57.2%)	65 (42.8%)

Table 2: Distribution of different OCs in different age groups

Cyst	Ist Decade	2nd Decade	3rd Decade	4th Decade	5th Decade	6th Decade	7th Decade	Not Determined
Radicular (N = 77)	1 (1.3%)	6 (7.8%)	9 (11.7%)	16 (20.7%)	19 (24.6%)	15 (19.5%)	10 (13%)	1 (1.3%)
Dentigerous (N =35)	3 (8.6%)	13 (37.1%)	9 (25.7%)	5 (14.3%)	2 (5.7%)	2 (5.7%)	1 (2.9%)	0 (0%)
Odontogenic Keratocyst (N=16)	1 (6.25%)	5 (31.2%)	6 (37.5%)	2 (12.5%)	1 (6.25%)	1 (6.25%)	0 (0%)	0 (0%)
Residual (N = 13)	0 (0%)	0 (0%)	1 (7.7%)	2 (15.4%)	2 (15.4%)	4 (30.7%)	3 (23%)	1 (7.7%)
Lateral Periodontal (N = 8)	0 (0%)	3 (37.5%)	2 (25%)	1 (12.5%)	1 (12.5%)	1 (12.5%)	0 (0%)	0 (0%)
Paradental (N=3)	0 (0%)	0 (0%)	2 (66.7%)	1 (33.3%)	0 (0%)	0 (0%)	0 (0%)	0 (0%)
Cyst	Ist Decade	2nd Decade	3rd Decade	4th Decade	5th Decade	6th Decade	7th Decade	
Total (N=152)	5 (3.3%)	27 (17.7%)	29 (19.1%)	27 (17.7%)	25 (16.5%)	23 (15.1%)	14 (9.2%)	2 (1.3%)

Table 3: Distribution of different OCs according to anatomic location

Type of cyst	Anterior maxilla	Posterior maxilla	Anterior mandible	Posterior mandible
Radicular (N = 77)	26 (33.8%)	17 (22.1%)	13 (16.8%)	21 (27.3%)
Dentigerous (N =35)	5 (14.3%)	4 (11.4%)	7 (20%)	19 (54.3%)
Odontogenic Keratocyst (N=16)	3 (18.7%)	2 (12.5%)	2 (12.5%)	9 (56.3%)
Residual (N = 13)	1 (7.7%)	4 (30.7%)	2 (15.4%)	6 (46.2%)
Lateral Periodontal (N = 8)	0 (0%)	1 (12.5%)	2 (25%)	5 (62.5%)
Paradental (N=3)	0 (0%)	1 (33.3%)	0 (0%)	2 (66.7%)
Total (N=152)	35 (23%)	29 (19.1%)	26 (17.1%)	62 (40.8%)

Total case distribution according to age is shown in [Table 2]. Distribution of cases according to anatomic site is shown in Table 3 and graphically represented by Figure 3 with 64 cases occurring in maxilla and 88 cases affecting mandible. The anatomical location that was most frequently involved was the mandibular posterior region with 62 cases (40.8%), followed by the maxillary anterior region with 35 cases (23%) and the maxillary posterior region with 29 cases (19.1%) [Table 3, Figure 3]. Radicular cyst was the most prevalent histological type with 77 cases representing 6.2% of total number of cases (n = 1235), 50.6% of all OCs and having male to female ratio of 1.2:1 [Table 1]. Maxillary anterior region was most commonly affected (33.8%) followed by mandibular posterior region (27.3%). Dentigerous cyst was the second most common type of OC diagnosed with 35 cases (23 %) with a male to female ratio of 1.5:1. The majority of cases were seen in the second and third decades. Mandibular posterior region was the most frequent site affected (54.3 %). Odontogenic Keratocyst (OKC) was the third most common cyst with 16 cases (10.5 %) and male to female ratio of 1.6:1. Most of the cases were seen in the second and third decades of life. The most frequent site involved was the mandibular posterior region (56.3 %). Residual cyst was the fourth most common OC with total of 13 cases representing 8.6% of all OCs most frequently involving the mandibular posterior region (46.2%), predominantly occurring in 6th decade of life. 8 cases of lateral periodontal cyst (5.3%) were reported out of which six were found in males and 2 cases in females and mainly affected the posterior mandible. 3 cases of paradental cysts (1.9%) were diagnosed, 2 males and one female; 2 out of 3 cases occurring in third decade of life, with most frequent location in the posterior mandibular region. Table 1 shows overall and gender wise distribution of all OCs, graphically shown in [Figure 1 and Figure 2]; [Table 2] shows prevalence of different OCs in different age groups while the anatomic location of OCs is shown in [Table 3] and graphically represented in [Figure 3].

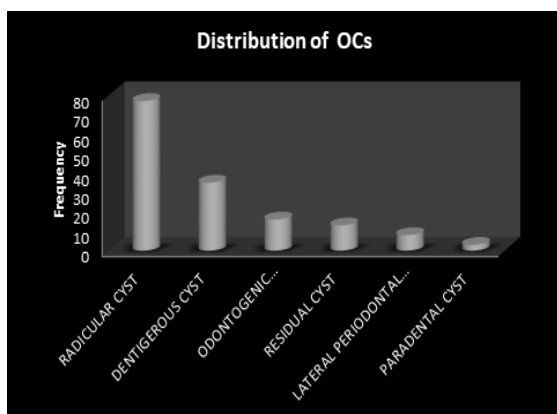


Figure 1: Distribution of OCs.

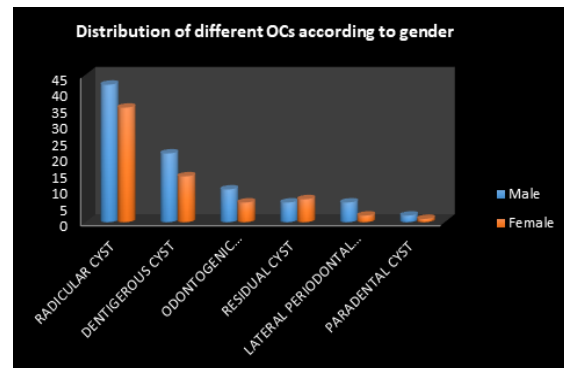


Figure 2: Distribution of different OCs according to gender.

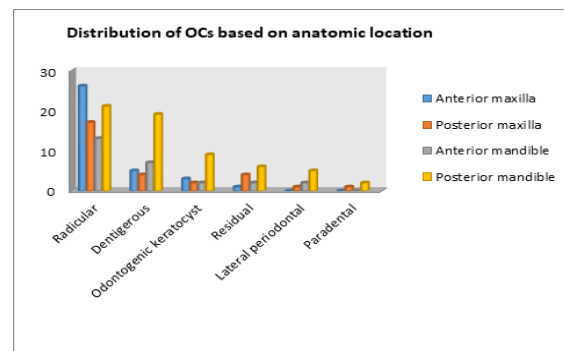


Figure 3: Distribution of OCs based on anatomic location.

DISCUSSION

The human jaw bones, main hard tissue of orofacial region can be the sites for development of various conditions such as cysts, neoplasms, or systemic bone diseases. Some of them, such as odontogenic cysts and tumors, are originated from tissue remnants of the tooth forming apparatus or are the result of inflammation. Most of the OCs affecting the jaws resemble each other clinically and radiographically.^[2] Therefore, clinical and radiographic evaluation should be supported by histopathological examination to ensure proper diagnosis of OCs which in turn will ensure proper treatment. A total of 152 cases of OCs were identified in the present study which accounted for 12.3 % of all cases. Similar results have been reported in other parts of India,^[7] in UK,^[2] Jordan,^[8] Iran,^[9] Brazil and Sicily.^[10,11] However lower frequencies of OCs (7.8 to 8.4 %) have been reported in Mexican populations.^[12] In our study the OCs showed higher frequency in males (57.2%) than females (42.8%) which is in accordance with studies conducted in other countries with frequencies ranging from 52.5 to 65.0 %.^[2,11-13] Patients in the second, third and fourth decades were most commonly afflicted by OCs. Based on anatomic location, mandible was affected more than maxilla, posterior mandible was the most common site involved (40.8%), followed by maxillary anterior region (23%); similar results

have been reported in other studies also.^[2] In contrast, a higher frequency of OCs was reported in the maxilla in a study carried out in Lithuania, with a proportion of 1.5:1.^[14] Radicular cysts were found to be the most frequent type of OCs and accounted for 50.6 % of all OCs. This is in accordance with other studies which have reported a relative frequency between 47 and 58 %.^[2,14,15] In our study, radicular cysts predominated in third, fourth and fifth decades of life which is in agreement with other studies.^[2,11,16] In contrast, studies involving other Indian populations,^[7] populations from Jordan and Chile,^[8,15] have shown a peak incidence between the second and third decades of life. The higher frequency of radicular cysts especially in males (50.6 %) can be attributed to lack of oral hygiene as well as to a higher frequency of trauma in the maxillary anterior region (33.8 %).^[11] Most of other studies have also reported similar results with radicular cysts being more prevalent among males than females.^[2,8,14,17] In our study, male to female ratio of 1.2:1 was obtained for radicular cysts. This is in contrast with studies involving other Brazilian,^[10] and Latin American populations which have shown a slightly higher frequency for females. In our study,^[2,8] dentigerous cyst was found to be the second most common OC with a frequency of 23 %. Other studies have also reported similar results with frequencies ranging from 11.4 to 33.0 %.^[2,6,15] Dentigerous cyst showed higher frequency in men in the present study with posterior mandible being the most common site affected. Similar results were reported in other studies also.^[2,10,11] Jones et al,^[2] attributed the high frequency of dentigerous cysts in the mandibular posterior region to the fact that the lower third molars are the teeth most commonly impacted. Dentigerous cysts mostly predominate in the second decade of life,^[5,8,15] a fact also observed in the present study. In contrast, a peak incidence between the fifth and sixth decades was reported by Jones et al.^[2] Male predilection with male to female ratio of 1.5:1 was noted in our study. This was in accordance with studies carried out by Bataineh et al.^[8] Tortorici et al.^[11] Mosqueda et al.^[13], Meningaud et al.^[17] OKC was found to be the third most common among the OCs with a frequency of 10.5 % which is in agreement with other studies with frequencies ranging from 1.3 to 21.5 %^[2,10,13,15,17] Although WHO reclassified these cysts as keratocystic odontogenic tumors,^[18] for comparison purpose we maintained previous classification.^[5] OKCs are mostly diagnosed between the second and third decades of life with slight male predilection. However,^[13,17,19-21] a higher frequency of OKCs was reported in females in a study conducted on a Turkish population.^[20] OKCs showed a higher predilection for the mandibular posterior area in our study with a frequency of 56.3 % which is in agreement with other studies

also.^[2,10,13,15,17,21] One of the main problems associated with OKC is relatively high recurrence rates ranging from 18 to 58.3 %.^[22] Gorlin syndrome has been reported to be associated with multiple OKCs. However, this study was mainly focused on OCs as separate entities not associated with other diseases or syndromes. The fourth most common cyst observed in the present study was the residual cyst with a frequency of 8.6 % and occurs due to inadequate removal of the infected tissue during tooth extraction. Similar studies have reported frequencies ranging from 5.9 % to 13 %.^[12,15,19] These were more common in the sixth and seventh decades which is in contrast to some studies which have reported higher prevalence in the third and fourth decades. In the present study,^[1,2,8,12,17] posterior mandible (46.2 %) was most common site affected followed by posterior maxilla (30.7 %). Similar results were seen in a study carried out by Luis et al,^[16] in Mexican population. However younger patients may also be affected when the teeth are lost prematurely.^[1] Lateral periodontal cysts develop in the alveolar bone along the lateral surface of a vital and erupted tooth. LPC are most common in males at 5th to 7th decades of life (mean age of 50.8 years).^[23] A frequency of 6.2 % was obtained in our study which is higher than what other studies have reported.^[16] In our study, out of 8 cases, 6 were reported in males and 2 in females. Most of LPC are located in the mandibular-premolar area, followed by the anterior region of maxilla.^[23] Four cases of paradental cyst were identified. The paradental cyst or inflammatory paradental cyst is defined as “a cyst occurring near to the cervical margin of the lateral aspect of a root as a consequence of an inflammatory process in the periodontal pocket. These are mostly (61.4 %) associated with partially or fully erupted third vital mandibular molars.^[24] 3 paradental cysts (1.9 % of all OCs) were found in the present study out of which 2 were located in mandible and 1 in maxilla. Data on incidence and prevalence of paradental cyst is scarce and limited to isolated case reports, however, frequency rates varying from 0.9 to 4.7% have been reported.^[24] Paradental cysts usually exhibit a male preponderance and in our study,^[24] 2 out of 3 paradental cyst cases were reported in males. These cysts are usually diagnosed in the third decade of life and our study revealed two cases in the third decade and one case in the fourth decade.^[2] Gingival cysts of adults are thought to arise from the epithelial remnants within gingival connective tissue. They are usually seen in the fifth and sixth decades,^[2] of life but in our study we did not encounter any such case. Mandible is more commonly affected especially in females than in males (3:1) as reported by most studies.^[2,7] The gingival cyst of infants is rarely subjected to histopathological examination as these lesions

usually undergo spontaneous involution within 3 months of birth.^[2] No case of COC was found in our study. COC has been reclassified as Calcifying Cystic Odontogenic Tumor (CCOT), an odontogenic tumor in the new classification.^[18] It usually occurs in third, fifth and seventh decade, predominantly in mandibular posterior region and has slight male predilection.^[1, 2, 5, 7]

CONCLUSION

OCs are the most frequent intraosseous lesions of the jaws and therefore acknowledging and addressing their demographical and clinical characteristics becomes necessary. Radicular and dentigerous cysts are the two most frequent of all OCs. Since, radicular cyst which is the most common OC occurs as a sequel of dental caries (pulpal necrosis), therefore, preventive strategies need to be established to diminish dental decay and in consequence decrease the prevalence of radicular cyst. On the other hand, dentigerous cysts are associated with impacted teeth, hence programs of prophylactic extractions of impacted teeth need to be established. Our study showed that some OCs have a predilection for certain ages, sex and sites and also some of these cysts have a tendency to recur and may show locally aggressive behavior (eg; OKCs). Therefore, these lesions need to be detected as early as possible to minimize any necessary surgery. Regular follow up and monitoring of patients is necessary to minimize chances of recurrence. It is emphasized that collecting adequate clinical, radiographic and histopathological details is necessary to establish final diagnosis of these lesions and performing routine follow-up is of utmost importance.

REFERENCES

1. Avelar RL, Antunes AA, Carvalho RWF, Bezerra PGC, Neto PJO, Andrade ESS. Odontogenic cysts: a clinicopathological study of 507 cases. *J Oral Sci* 2009;51:581–586
2. Jones AV, Craig GT, Franklin CD. Range and demographics of odontogenic cysts diagnosed in a UK population over a 30-year period. *J Oral Pathol Med* 2006;35:500–507
3. Barnes L, Eveson J, Reichart P, Sidransky D. Pathology and genetics of head and neck tumours. Lyon: WHO, IARC Press, 2005.
4. Gaitán-Cepeda LA, Quezada-Rivera D, Tenorio-Rocha F, Leyva-Huerta ER. Reclassification of odontogenic keratocyst as tumour. Impact on the odontogenic tumours prevalence. *Oral Dis*. 2010;16:185-7.
5. Kaplan I, Gal G, Anavi Y, Manor R, Calderon S. Glandular odontogenic cyst: treatment and recurrence. *J Oral Maxillofac Surg* 2005;63:435–441
6. Kramer IR, Pindborg JJ, Shear M. The WHO histological typing of odontogenic tumours. A commentary on the second edition. *Cancer* 1992;70:2988–2994
7. Kambalimath DH, Kambalimath HV, Agrawal SM, Singh M, Jain N, Anurag B, Michael P. Prevalence and Distribution of Odontogenic Cyst in Indian Population: A 10 Year Retrospective Study. *Med Oral* 7:89–96.
8. Bataineh AB, Rawashdeh MA, Al Qudah MA (2004) The prevalence of inflammatory and developmental odontogenic cysts in a Jordanian population: a clinicopathologic study. *Quintessence Int* 35:815–819.
9. Sharifian MJ, Khalili M. Odontogenic cyst: a retrospective study of 1,227 cases in an Iranian population from 1987 to 2007. *J Oral Sci* 2011;53:361–367.
10. Batista de Souza L, Gordo'n-Nu'n'ez MA, Weege Nonaka CF, Costa de Medeiros M, Fernandes Torres T, Guedes Emiliano GB. Odontogenic cysts: demographic profile in a Brazilian population over a 38-year period. *Med Oral Patol Oral Cir Bucal* 2010;15:e583–e590.
11. Tortorici S, Amodio E, Massenti MF, Buzzanca, Burruano F, Vitale F. Prevalence and distribution of odontogenic cyst in Sicily: 1986–2005. *J Oral Sci* 2008;50:15–18.
12. Ledesma-Montes C, Hernandez-Guerrero JC, Garce's-Ortiz M (2000) Clinico-pathologic study of odontogenic cysts in a Mexican sample population. *Arch Med Res* 31:373–376
13. Mosqueda-Taylor A, Irigoyen-Camacho ME, Diaz-Franco MA, Torres-Tejero MA (2002) Odontogenic cysts. Analysis of 856 cases. *Med Oral* 7:89–96.
14. Varinauskas V, Gervickas A, Kavoliu'niene O (2006) Analysis of odontogenic cysts of the jaws. *Medicina (Kaunas)* 42:201–207
15. Ochsenius G, Escobar E, Godoy L, Penafiel C (2007) Odontogenic cysts: analysis of 2,944 cases in Chile. *Med Oral Patol Cir Bucal* 12:E85–E91
16. Prevalence and distribution of odontogenic cysts in a Mexican sample. A 753 cases study Luis Villasis-Sarmiento 1, Javier Portilla-Robertson 1, Arcelia Melendez-Ocampo 2, Luis-Alberto Gaitan- Cepeda 1, Elba-Rosa Leyva-Huerta
17. Meningaud JP, Oprean N, Pitak-Arnop P, Bertrand JC. Odontogenic cysts: a clinical study of 695 cases. *J Oral Sci* 2006;23:59–62
18. Madras J, Lapointe H. Keratocystic odontogenic tumour: reclassification of the odontogenic keratocyst from cyst to tumour. *J Can Dent Assoc* 2008;74:165–165h
19. Urrutia SN, Figueiredo R, Gay-Escoda C. Retrospective clinicopathological study of 418 odontogenic cysts. *Med Oral Patol Oral Cir Bucal* 2010;15:e767–e773
20. Koseoglu BG, Atalay B, Erdem MA. Odontogenic cysts: a clinical study of 90 cases. *J Oral Sci* 2004;46:253–257
21. Selvamani M, Donoghue M, Basandi PS. Analysis of 153 cases of odontogenic cysts in a South Indian sample population: a retrospective study over a decade. *Braz Oral Res* 2012;26:330–334
22. Chirapathomsakul D, Sastravaja P, Jansisyant P. A review of odontogenic keratocysts and the behavior of recurrences. *Oral Surg Oral Med Oral Pathol Oral Radiol Endod* 2006;101:5–9
23. De Andrade M, Silva APP, de Moraes Ramos-Perez FM, Silva-Sousa YT, da Cruz Perez DE. Lateral periodontal cyst: report of case and review of the literature. *Oral Maxillofac Surg*. 2012;16:83-7.
24. Philipsen HP, Reichart PA, Ogawa I, Sueti Y, Takata T. The inflammatory paradental cyst: a critical review of 342 cases from a literature survey, including 17 new cases from the author's files. *J Oral Pathol Med*. 2004;33:147-55.

How to cite this article: Younis M, Shah AA, Rashid A, Kapoor M, Bhat I. Prevalence and Distribution of Odontogenic Cysts in Kashmiri Population: A Retrospective Clinical Study of 152 Cases. *Ann. Int. Med. Den. Res.* 2018; 4:4:DE06-DE10.

Source of Support: Nil, **Conflict of Interest:** None declared