

Diagnosis of Hyperparathyroidism after Surgical Treatment of Osteolytic Lesion.

Agnone A¹, Ciccarelli E², Giordano Lu¹, Abbona G³, Saracco R⁴

¹Department of Dentistry and Maxillo-Facial Surgery SC Chief M. Giordano Martini Hospital, Turin, Italy.

²Department of Endocrinology, SS Dr Ciccarelli Martini Hospital, Turin, Italy.

³Department of Pathology SC Chief Dr Taraglio, Martini Hospital, Turin, Italy.

⁴Department of General Surgery, SC Chief Dr Saracco R, Martini Hospital, Turin, Italy.

Received: July 2018

Accepted: July 2018

Copyright: © the author(s), publisher. It is an open-access article distributed under the terms of the Creative Commons Attribution Non-Commercial License, which permits unrestricted non-commercial use, distribution, and reproduction in any medium, provided the original work is properly cited.

ABSTRACT

Several metabolic diseases can affect normal process of osteogenesis, involving the formation of a collagen matrix, where the salts that form the bone are deposited. The homeostasis of calcium and phosphate metabolism is regulated by the activity of the parathyroid glands, whose alterations are associated with bone modifications. Parathyroid hormone (PTH) exerts profound effects on skeletal homeostasis through several cellular and molecular mechanisms. Chronic hyperparathyroidism causes net loss of bone mass, despite accelerating bone formation by osteoblasts. An increased secretion of PTH, caused for example by an adenoma of the parathyroid glands, can induce the formation of a central giant cellular lesion of the jaws known as Brown's Tumour of the jaws, that may lead to evident osteolysis and gross deformity in the maxillofacial region. This may be the first presentation of this disease. The authors report a 79-years-old male patient who presented with an asymptomatic osteolytic lesion in the right maxilla as the first manifestation of primary hyperparathyroidism, caused by a parathyroid adenoma. The authors describe the surgical treatment of the maxillary lesion, the procedure that led to the diagnosis of hyperparathyroidism and its treatment.

Keywords: Brown's Tumour, Jaw, Osteolytic lesion, Parathyroid hormone (PTH).

INTRODUCTION

Parathyroid hormone 1-84 (PTH [1-84]) is the biologically active hormone produced by the parathyroid glands and secreted into the systemic circulation.

The parathyroid glands are unique organs responsible for maintaining calcium homeostasis. There are commonly four parathyroid glands that weigh approximately 40 grams each and are generally located posteriorly and inferiorly to the thyroid in the neck.^[1]

Secretion of PTH is modulated not only by serum calcium but also phosphorus and vitamin D through negative and positive feedback loops.

In the bone, PTH binds to PTH type 1 receptors (PTH1R) to assist with calcium resorption. In the kidney, PTH acts to increase renal calcium, decrease phosphate reabsorption, and activate metabolism of vitamin D. In the intestine, PTH transcriptionally upregulates 1 alpha hydroxylase,

leading to increased production of 1,25-dihydroxyvitamin D, which in turn enhances calcium and phosphorus reabsorption

These actions of PTH on the bones, kidneys, and intestine are a careful orchestration of interrelated processes driven by feedback loops. Subsequently, excessive or insufficient secretion of PTH can lead to disruption of these loops and, in turn, alterations in calcium homeostasis.^[2]

Calcium homeostasis is also important for cardiac function, besides kidney stones and osteoporosis, patients with parathyroid gland disorders have a higher incidence of hypertension, arrhythmias, left ventricular hypertrophy, heart failure and calcific disease that result in increased cardiac morbidity and mortality.^[8]

Primary hyperparathyroidism (PHP) is the third most common endocrine disorder after diabetes mellitus and thyroid illnesses, the case studies showing an estimated prevalence in general population of 0,5-1% and an annual incidence of 28 cases per 100000 people . Single gland sporadic parathyroid adenoma (PA) represents the most frequent cause (85-90%) of PHP cases.^[3]

The treatment for parathyroid adenoma is parathyroidectomy;^[7-10] calcium channel blockers such as cinacalcet may only be used in unoperable patients.

Name & Address of Corresponding Author

Dr. Agnone A,
Department of Dentistry and Maxillo-Facial Surgery
SC Chief M.
Giordano Martini Hospital, Turin, Italy.

Parathyroid hormone (PTH) exerts profound effects on skeletal homeostasis through multiple cellular and molecular mechanisms. Continuous hyperparathyroidism causes net loss of bone mass, despite accelerating bone formation by osteoblasts. Bone and joint disorders include joint pains, subperiosteal resorption, systemic osteopenia, osteitis fibrosa cystica, bone calcifications, cyst and sequels of pathological fractures fracture sequelae.^[3]

The Authors describe a case of asymptomatic primary hyperparathyroidism diagnosed after enucleation of osteolytic lesion of the maxillary bones.

CASE REPORT

A 79-year-old man was referred to our department sent by his dentist with the main complaint of a big osteolytic and asymptomatic lesion in the maxillary right side observed in his orthopantomograph.

The patient's history included depression; hepatitis C found around 8 years ago.

The oral examination showed chronic periodontitis, associated with mobility of the right permanent maxillary teeth, mucosal examination was normal.

The lesion was considered as an inflammatory cyst, involving the maxillary sinus and extended from 15 to 18 impacted, for its enucleation, the surgeon asked for execution of a cone beam CT of the maxillary bone to plan the surgery.

CT cone beam reported the presence of a gross osteolytic lesion in region 18, 17, 16, 15 which exteriorised with a thin bone wall in the inferior cavity of the right maxillary sinus and caused extensive wear of the buccal and alveolar cortical bone. The maximum extension of the lesion on the coronal plane was about 30 mm. [Figure 1]

The patient was then subjected to the surgical removal of the osteolytic lesion, executing a flap from 13 to 18, after the extracting of the elements 18 and 15, the lesion was enucleated and the anatomical piece was sent for the histological examination. The surgery ended with placement of fibrillar absorbable haemostat and the suture of the part affected by the intervention.

The macroscopic description of the anatomical piece is brownish fragments, 3 cm in size.

Microscopically the pathologist described spindle cells, giant-cell elements, in relation to trabecular bone tissue, partly dissociated with signs of recent and previous haemorrhage. [Figure 2]

Unexpectedly the histological diagnosis of the lesion was central giant-cell granuloma (CGCG).

Following the visit with the endocrinologist, the patient underwent to some biochemical testing.

Detailed biochemical tests showed hypercalcemia (total serum calcium: 11.9 mg/dL), $Ca^{++}1.5mEq/L$, hyperalkalinephosphatasemia (serum alkaline phosphatase: 70 U/L), hypophosphatemia

(inorganic phosphorus: 1.9 mg/mL), a high level of intact PTH (678 pg/mL), increased urinary calcium excretion (fractional calcium excretion: 5mEq/24h), and decreased urinary phosphate reabsorption (300 mg/24h). Thyroid function was normal. The provisional diagnosis, based on these findings, was PHP.

The patient was then submitted to investigations for localization of an adenoma of the parathyroid gland cause of primary hyperparathyroidism.

Ultrasonography showed a 27x10 mm hypoechoic mass with a smooth margin and poor blood flow.

Tc 99m sestamibi scintigraphy showed accumulation in the same region as the hypoechoic area. The results of these imaging studies confirmed the diagnosis of PHP.

The patient underwent also to bone densitometry and bone mineral density values of femur and rachis resulted reduced by osteoporosis.

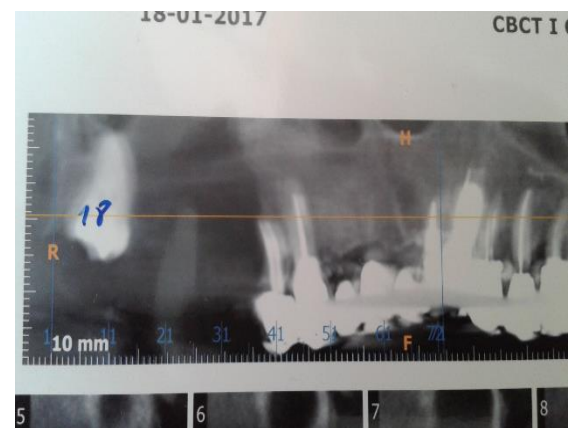


Figure 1: Panorex Tc cone beam showing maxillary Osteolytic lesion of the jaw

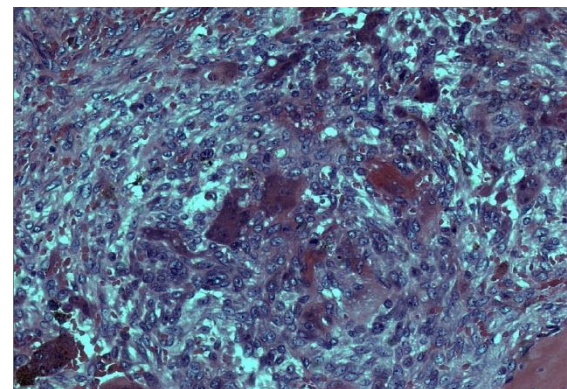


Figure 2: Maxillary lesion (250x) spindle cells, giant-cell elements, in relation to trabecular bone tissue, partly dissociated with signs of recent and previous haemorrhage.

The final diagnosis of the maxillary lesion was brown tumors in primary hyperparathyroidism.

Primary hyperparathyroidism treatment required surgical resection of the abnormal glands.

Immediately after surgery, the patient received a calcium and vit D therapy given by the endocrinologist to avoid a hungry bone syndrome.

General surgeons proceeded to remove the parathyroid lesion, which had a histopathological diagnosis of parathyroid adenoma.

The anatomical piece measured 5 cm in its larger side. [Figure 3]

During the surgery rapid measurement of PTH levels was used intra-operatively to confirm that an adenoma was been successfully removed.

Effects of successful surgery materialized in stable endocrine equilibrium, control of hypercalcemic features through disappearance or at least enhancing of most clinical features and normalization of biological constants.

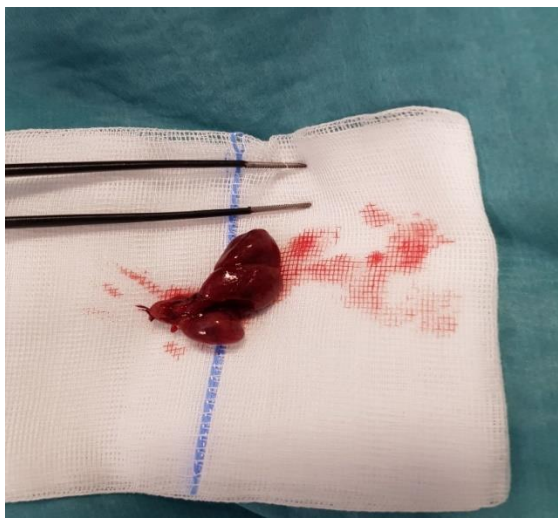

Figure 3: Parathyroid adenoma.

DISCUSSION

Brown tumor is a uni-focal or multi-focal bone lesion, which represents a terminal stage of hyperparathyroidism dependent bone pathology. In localized regions where bone loss is particularly rapid, hemorrhage, reparative granulation tissue, and active, vascular, proliferating fibrous tissue may replace the normal marrow contents, resulting in a brown tumor. The brown coloration is due to hemosiderin deposition.^[9] Brown tumors commonly affect the jaws, skull, pelvis, clavicle, ribs, femurs, and spine.^[4]

Because of the similarity of radiological features (e.g., cyst-like radiolucency) characteristic of other lesions, the diagnosis can be difficult.

Brown tumors contain giant cells and spindle-shaped cells, intermixed with fibrous tissue and poorly mineralized woven bone.

Brown tumors is histologically indistinguishable by other lesions that show similar macroscopical and microscopical features, because some conditions like for example cherubism, the central giant cell

granuloma, the giant cell tumor and the aneurysmal bone cyst contain giant-cell.^[6]

CONCLUSION

A correct diagnosis in a patient with primary hyperparathyroidism may not be is easy. The dental surgeon must be aware of the existence of these metabolic bone diseases, which can also affect the maxillary bones and that, as in this case report, can lead to the diagnosis of a systemic disease that had not yet been diagnosed because asymptomatic but that could have led to serious consequences for the patient.

REFERENCES

1. Shoback D, Sellmeyer D, Bikle DD. Metabolic bone disease. In: Gardner DG, Shoback D, editors. Greenspan's basic & clinical endocrinology. 9th ed. New York, NY: The McGraw-Hill Companies; 2011. p. 227-284.
2. Pyram R, Mahajan G, Gliwa A. Primary hyperparathyroidism: Skeletal and non-skeletal effects, diagnosis and management. *Maturitas*. 2011 Nov;70(3):246-55.
3. Mihai Radu Diaconescu1, Ioan Costea1, Mihai Glod1, Radu Terinte1, Smaranda Diaconescu Parathyroid Adenomas in Adults and Adolescents. *Critical Appraisal and Surgical Strategy in 18 Cases Chirurgia*(2017)112:18-24No.1, January-February Copyright© Celsius <http://dx.doi.org/10.21614/chirurgia.112.1.18>
4. Osteitis fibrosa cystica—a forgotten radiological feature of primary hyperparathyroidism
5. Waldemar Misiorowski, Izabela Czajka-Oraniec1 Magdalena Kochman, Wojciech Zgliczyński,John P. Bilezikian, *Endocrine* (2017) 58:380–385 DOI 10.1007/s12020-017-1414-2
6. J.V Soames, J.C Southam. *Patologia Orale III edizione 2001 EMSI-Roma pag 328*
7. Manchil P. Redwin D., Kannan S. K., Joy E. Tatu, Sherubin J. Eugenia . *Hyper Parathyroidisim Jaw Tumor Syndrome: A Rare Condition of Incongruous Features. Ethiop J Health Sci* 2017;27(3):309. doi: <http://dx.doi.org/10.4314/ejhs.v27i3.14>
8. S.J. Brown, M.D.; M.D. Ruppe, M.D.; L. S. Tabatabai, *The Parathyroid Gland and Heart Disease M.D. MDCVJ | XIII* (2) 2017
9. L. Azzi, L. Cimetti, M. Annoni, D. Anselmi, L.Tettamanti, A. Tagliabue. A Giant-Cell Lesion with Cellular Cannibalism in the Mandible: Case Report and Review of Brown Tumors in Hyperparathyroidism. *Hindawi Publishing Corporation Case Reports in Dentistry Volume 2017, Article ID 9604570, 8 pages* <http://dx.doi.org/10.1155/2017/9604570>
10. Jill C. Rubinstein, S K. Majumdar, W. Laskin, F. Lazaga, M. L. Prasad,T. Carling, S. A. Khan *Hyperparathyroidism-Jaw Tumor Syndrome Associated With Large-Scale Iq31 Deletion. July 2017 | Vol. 1, Iss. 7 doi: 10.1210/js.2016-1089 | Journal of the Endocrine Society | 926–930.*

How to cite this article: Agnone A, Ciccarelli E, Giordano Lu, Abbona G, Saracco R. Diagnosis of Hyperparathyroidism after Surgical Treatment of Osteolytic Lesion. *Ann. Int. Med. Den. Res.* 2018; 4(5): DE05-DE07.

Source of Support: Nil, **Conflict of Interest:** None declared