

Surgical Extrusion With Immediate Aesthetics Of Crown - Root Fractured Anterior Teeth.

Ab. Wahid Zargar¹, Omer Hussain Misgar², Aamir Rashid Purra³, Riyaz Farooq⁴, Fayaz Ahmad Ahanger⁵, Jasira Gani⁶

¹PG student, Department of Conservative Dentistry & Endodontics, Govt. Dental College and Hospital, Shireen Bagh, Srinagar, India

²Senior resident, Department of Conservative Dentistry & Endodontics, Govt. Dental College and Hospital, Shireen Bagh, Srinagar, India

³Associate Professor, Department of Conservative Dentistry & Endodontics, Govt. Dental College and Hospital, Shireen Bagh, Srinagar, India.

⁴Professor and Head, Department of Conservative Dentistry & Endodontics, Govt. Dental College and Hospital, Shireen Bagh, Srinagar, India

⁵Assistant Professor, Department of Conservative Dentistry & Endodontics, Govt. Dental College and Hospital, Shireen Bagh, Srinagar, India.

⁶B.D.S, Institute of Dental Sciences, Sehora Jammu, J&K.

Received: September 2018

Accepted: September 2018

Copyright: © the author(s), publisher. It is an open-access article distributed under the terms of the Creative Commons Attribution Non-Commercial License, which permits unrestricted non-commercial use, distribution, and reproduction in any medium, provided the original work is properly cited.

ABSTRACT

Background: Aim: To study the outcome of single visit surgical extrusion and immediate aesthetic restoration of 15 cases of crown root fracture. **Methods:** Involved a conventional surgical extrusion method with elevators and stabilization with semi rigid fiber splint followed by immediate aesthetic composite buildup for restoration of aesthetics. Root canal treatment was completed after 3 weeks of Calcium hydroxide intracanal medicament. **Results:** Follow up examinations varying between 6 and 18 months, revealed no evident radiographic and clinical signs of root resorption, periapical disease and more important, marginal bone loss/gingival recession in any case. **Conclusion:** Highly favorable results of this clinical study reveal that single visit surgical extrusion with immediate aesthetics of crown root fractures may be an alternative to time consuming orthodontic extrusion which may create severe esthetic and emotional problems to patient.

Keywords: Surgical Extrusion, Immediate Esthetics, Crown Root Fractures, Calcium Hydroxide.

INTRODUCTION

Face is regarded as most salient characteristic of one's beauty. Traumatic dental injuries alter facial appearance. Their relevance to present day aesthetic dentistry is because of their frequency, the functional and aesthetic disturbances. There is evidence of an increased incidence of traumatic injuries to anterior teeth with the most common injuries being crown fractures.^[1,2] Loss of tooth tissue in the anterior region in a young patient may create severe aesthetic and emotional problems.^[3] Depending on the location of fracture line different treatment modalities are indicated, however, in complicated fractures where fracture line extends below marginal bone level immediate esthetic restoration as well as final coronal restoration presents lot of problems to clinician in terms of the

moisture control and maintenance of biological width. To save such teeth orthodontic/surgical extrusion have been recommended.^[4,5] Although orthodontic extrusion provides more biological way of extruding teeth, it is time consuming and requires multiple visits which is cumbersome to the patient and esthetics remain compromised during the time of extrusion. Surgical extrusion on the other hand is one step procedure, simpler and less time consuming.

The purpose of this study is to introduce a new method to achieve immediate esthetics in one step conventional surgical extrusion and also evaluate the results of such surgical extrusion cases treated endodontically with calcium hydroxide as intracanal medicament.

MATERIALS AND METHODS

15 patients (11 males, 4 females) with crown root fractured permanent incisors who attended the department of conservative dentistry and endodontics at Govt Dental College and Hospital Srinagar, Kashmir between 2015 and 2017 were included in the study. Patients aged between 15 to

Name & Address of Corresponding Author

Dr. Ab. Wahid Zargar
Room No.601
Department of Conservative Dentistry & Endodontics
Govt. Dental College and Hospital
Shireen Bagh, Srinagar, India.

35 years. The cause of fracture was traumatic injury in all cases. All the patients were healthy with no previous conservative or endodontic treatment. All teeth were maxillary central incisors, with fully developed roots. Out of 15 cases six had non vital pulp and nine with vital pulp. In all teeth primary endodontic treatment was initiated before surgical repositioning except in two cases where endodontic treatment was initiated after surgical repositioning as teeth were covered with gingival overgrowth. After anaesthetizing the area, surgical procedure involved incising of marginal periodontal fibers using B.P blade (no 12) and careful mobilization of roots with elevators. In five patients roots were extruded and rotated 180 degrees and repositioned achieving increased extrusion and more favorable positioning of fracture line (fig1). Amount of extrusion varied between 3 to 6 mm (table 1). After surgical extrusion was completed rubber dam was applied and isolation achieved from canine to canine. After isolation, composite buildup of the extruded root was done to restore the aesthetics and stabilized using fiber splint palatally. No antibiotic coverage was prescribed, however, patients were motivated to maintain oral hygiene. Fiber splint was removed after 2 weeks. Calcium hydroxide dressing was maintained for 3 weeks. After 3 weeks repositioned roots had achieved adequate stabilization. Working length was established at 0.5mm short of the radiographic apex. Hand instrumentation with k-type files and 5.25% NaOCl as irrigating solution. Root canals were dried and obturated with AHplus and gutta purcha using cold lateral condensation obturation technique. After clinical/radiographic signs of healing, a permanent restoration was placed using porcelain jacket crown. In 5 cases fiber post and core restorations were needed before fabrication of crown.

In clinical examination; assessment of mobility, gingival pocket depth, periapical tenderness and radiographic examination at 1, 2 and 3 weeks and 3,6,8,12&18 months was done.

RESULTS

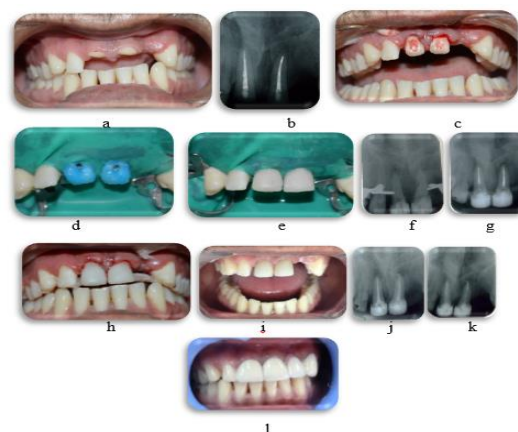


Figure 1: (a) Photograph showing a cervical root fracture of teeth 11,21. Note that the tooth crowns were absent. (b) Pre-operative radiograph of the same teeth. Note that endodontic treatment was started before repositioning and Ca(OH)₂ medicament placed (c) Position of the tooth immediately after surgical extrusion of 4 mm and 180° rotation. (d) isolation achieved and etching of extruded tooth done. (e) esthetic buildup done. (f&g) working length established after buildup and Ca (OH)₂ medicament placed. (h) immediate post op with fiber splint lingually (i) Appearance of the tooth 2 weeks after surgical extrusion. (j) completion of endodontic treatment. (k) Radiograph taken 8 months after endodontic treatment & Fiber post placement. Note the resolution of periapical radiolucency and that there are no signs of root resorption. (l) appearance after final restoration

Table 1: Details of the surgical extrusion cases.

Case no.	Age	Sex	Location	180 degree rotation	Amount of extrusion	Follow-up period
1	17	M	21	Yes	5	8
2	24	M	11,21	Yes	4	6
3	21	F	11	No	3	6
4	25	M	21	No	4	8
5	19	F	12	No	3.5	12
6	28	M	11,21	No	4	18
7	32	M	11	Yes	5	6
8	34	M	11	No	6	6
9	16	F	21	No	4	8
10	22	M	11	No	3	18
11	18	M	21	Yes	5	12
12	24	M	21	No	4	12
13	22	F	21	No	4.5	8
14	18	M	11	No	4	6
15	20	M	11	Yes	4	18

Table 1 summarizes the results as per age, gender tooth type and follow-up period. The average extrusion was 4.2 mm with range of 3 – 6 mm. there were no post-operative complications and appearance was normal and entirely asymptomatic in all repositioned teeth. No post-operative

infection developed in any of the cases. Roots were stable enough at 3-4 weeks post-operative period to permit root canal therapy. At 3-month recall all of the repositioned roots showed normal mobility, normal attachment of marginal gingiva, normal percussion sound compared to adjacent teeth,

indicating no ankyloses. Radiographically signs of decrease in periapical radiolucency appeared at 6-month post obturation recall.

Radiographic signs of root resorption were not observed in any of the cases. Slight loss of marginal alveolar bone loss was observed in three cases which did not progress. There were no radiographic signs of root resorption, marginal bone loss or periapical disease in any tooth after completion of coronal restoration.

DISCUSSION

In the present study surgical technique of intra alveolar repositioning was found to be successful in extruding crown root fractures obtaining an average of 4.2 mm extrusion which was sufficient to allow subsequent placement of coronal restoration.

Previous clinical studies have shown that surgical extrusion may be successful to extrude and save the root which may be an alternative to orthodontic extrusion.^[6,7] As the bone support around the root is lost due to surgical extrusion, the apical segment should be of sufficient length.^[8] In this study the adequacy of apical segment was confirmed on pre operative apical radiographs. Different stabilization techniques for repositioned root have been reported in literature which include stabilization by transplanting bone above the root after extrusion or the tooth extrusion achieved by careful marginal luxation and stabilization by interdental suturing and surgical dressing.^[9] In the present study later technique was slightly modified to achieve desired extrusion. After marginal luxation and extrusion, the root was stabilized using fiber splint (semi rigid) and in some cases the root was rotated by 180 degrees to achieve favorable position and stabilization of the extruded root.

Surgical extrusion can be compared to extrusive luxation in these cases because the extruded roots were at no time completely removed from the socket. According to Andreasen extrusive luxation has a comparably favorable prognosis with a low incidence of root resorption.^[10,11] The viability of the cementoblast is very important for the healing of the socket and formation of a new functioning periodontal membrane.^[9] Dehydration of the root surface cells can lead to ankylosis and root resorption.^[12] In this clinical study, during surgical extrusion all of the teeth remained moist in their alveolar housing, the periodontal ligament was kept intact, and the teeth were gradually repositioned towards the occlusal plane and splinted.

Splinting has been advocated after repositioning of a tooth/teeth to stabilize the tooth/teeth and to optimize healing outcomes for the periodontal ligament.^[13] Historically, splinting of teeth utilized the principles of jaw bone fracture with rigid, long-term immobilization for a few months.^[14] The validity of this approach was questioned when studies showed rigid immobilization increased the

incidence of pulp necrosis and external root resorption.^[15,16] Splints are now used primarily to maintain the tooth in their socket during initial healing.^[17] In the present study, according to current IADT recommendations for splinting time for extrusive luxation, splinting of the root with fiber splint for 2 weeks was found to be very effective.

It has been shown that untreated dental injury has a negative impact on quality of life regarding social, functional, and emotional aspects. However, treated injured teeth appear to improve social and emotional aspects of the OHRQoL.^[18] In this clinical study esthetics were restored immediately after surgical repositioning using composites. Rubber dam was applied to control the moisture contamination. splinting was done lingually to improve the aesthetics. In this study all patients responded positively to the social, functional and emotional aspects with improvement in aesthetics.

Traditionally Calcium hydroxide paste proved to be efficient in arresting external inflammatory resorption.^[19,20] On the other hand, some authors speculated that resorption was caused by calcium hydroxide passing through the apical foramen, which led to damage to the periodontal ligament.^[21] A potential harmful effect on the periodontal ligament might lead to localized ankylosis and replacement resorption.^[22] However, reviews of existing clinical investigations that have studied the long-term prognosis of avulsed teeth treated with calcium hydroxide following replantation do not support this theory.^[23,24] In this clinical study calcium hydroxide was maintained for 3 weeks after which root canals were obturated. All patients were kept on observation period of 3 months following obturation before prosthetic rehabilitation during which no clinical signs, such as mobility, tenderness or pain, indicating underlying pathology, and no pathological signs could be observed radiographically. After 3 months of followup period tooth were restored permanently with crown.

CONCLUSION

The immediate esthetic restoration & high frequency of clinical healing in this study appears to justify recommending a surgical repositioning technique with immediate aesthetics as a treatment regime in teeth with crown root fractures with fracture line extending subgingivally.

REFERENCES

1. Blatz MB (2001) Comprehensive treatment of traumatic fracture and luxation injuries in the anterior permanent dentition. Practical Proceedings of Aesthetic Dentistry 13, 273-9.
2. Villat C, Machtou P, Naulin-Ifi C (2004) Multidisciplinary approach to the immediate esthetic repair and long-term

- treatment of an oblique crown-root fracture. *Endodontics and Dental Traumatology* 20, 6–60.
3. Callskan MK (1999) Surgical extrusion of a cervically root fractured tooth after apexification treatment. *Journal of Endodontics* 25, 509–13
 4. CË alisËkan, MK (1998) Surgical extrusion of a completely intruded permanent incisor. *Journal Of Endodontics*, 24, 381±4.
 5. Goldson, L, Malmgren, O (1981) Orthodontic treatment of traumatized teeth. In: Andreasen JO, ed. *Traumatic Injuries of the Teeth*. Copenhagen: Munksgaard, pp. 385±411.
 6. Saad, AY, Abdellatif, E-SM (1996) Surgical repositioning of unerupted anterior teeth. *Journal of Endodontics* 22, 376±9.
 7. Kahnberg, K-E (1988) Surgical extrusion of root-fractured teeth a follow-up study of two surgical methods. *Endodontics and Dental Traumatology* 4, 8 5±9.
 8. Feiglin, B (1995) Clinical management of transverse root fractures. *Dental Clinics of North America* 39, 53±78..
 9. Kahnberg, K-E (1985) Intraalveolar transplantation of teeth with crown-root fractures. *Journal of Oral Maxillofacial Surgery* 43, 38±42
 10. Andreasen, JO (1970) Luxation of permanent teeth due to trauma. A clinical and radiographical follow-up study of 189 injured teeth. *Scandinavian Journal of Dental Research* 78, 273±86.
 11. Andreasen, JO (1981) *Traumatic Injuries of the Teeth*. Copenhagen: Munksgaard, pp. 151±95.
 12. SoËder, POË, Ottoskog, P, Andreasen, JO, Modeer, T (1977) The effect of drying on the viability of periodontal membrane. *Scandinavian Journal of Dental Research* 84, 164±8.
 13. Oikarinen KS. Splinting of traumatized teeth. In: Andreasen JO, Andreasen FM, Andersson L, eds. *Textbook and Color Atlas of Traumatic Injuries to the Teeth*. 4th edn. Copenhagen: Blackwell Publishing, 2007:842–851.
 14. Kehoe JC. Splinting and replantation after traumatic avulsion. *J Am Dent Assoc* 1986;112:224–230.
 15. Kristerson L, Andreasen JO. The effect of splinting upon periodontal and pulpal healing after autotransplantation of mature and immature permanent incisors in monkeys. *Int J Oral Surg* 1983;12:239–249.
 16. Nasjleti CE, Castelli WA, Caffesse RG. The effects of different splinting times on replantation of teeth in monkeys. *Oral Surg Oral Pathol Oral Med* 1982;53:557–566.
 17. Berude, JA, Hicks, ML, Sauber, JJ, Li, SH (1990) Resorption after physiological and rigid splinting of replanted permanent incisors in monkeys. *Journal of Endodontics* 14,592±600.
 18. El-Kalla IH, Shalan HM, Bakr RA Impact of Dental Trauma on Quality of Life Among 11-14 Years Schoolchildren.
 19. Tronstad, L, Andreasen, JO, Hasselgren, G, Kristerson, L, Riis,J (1981) pH changes in dental tissues after root canal filling with calcium hydroxide. *Journal of Endodontics* 7, 17±21.
 20. Tronstad, L (1988) Root resorption etiology, terminology and clinical manifestations. *Endodontics an Dental Traumatology* 4, 241±52.
 21. Vanderas, AP (1993) Effect of intracanal medicaments on inflammatory resorption or occurrence of ankylosis in mature traumatized teeth: a review. *Endodontics and Dental Traumatology* 9, 175±84.
 22. Hammarstrom, LE, Blomlof, LB, Feiglin, B, Lindskog, SF (1986) Effect of calcium hydroxide treatment on periodontal repair and root resorption. *Endodontics and Dental Traumatology* 2, 184±9.
 23. Cvek, M (1973) Treatment of non-vital permanent incisors with calcium hydroxide II. Effect of an external root resorption in luxated teeth compared with effect of root canal filling with gutta-percha. *Odontologisk Revy* 24, 343±54.
 24. Cvek, M (1992) Prognosis of luxated non-vital maxillary incisors treated with calcium hydroxide and filled with gutta-percha. A retrospective clinical study. *Endodontics and Dental Traumatology* 8, 44±55.

How to cite this article: Zargar AW, Misgar OH, Purra AR, Farooq R, Ahanger FA, Gani J. Surgical Extrusion With Immediate Aesthetics Of Crown -Root Fractured Anterior Teeth. *Ann. Int. Med. Den. Res.* 2018; 4(6):DE01-DE04.

Source of Support: Nil, **Conflict of Interest:** None declared