

Sexual Dimorphism in the Dimensions of Spleen in the Population of North-West Ethiopia – An Observational Radiographic Study.

Yared Tekle¹, Sanket Dadarao Hiware², Sneha Plamoovil John³, Mueez Abreha⁴, Abebe Mucbe⁵, Zerubabel Tegegne⁶

¹Lecturer in department of Anatomy, College of Medicine and health sciences, Dire Dawa university, Ethiopia.

²Assistant professor in department of Anatomy, College of Medicine and health sciences, Dire Dawa university, Ethiopia.

³Registrar in department of Anatomy, HBT Medical College, Mumbai, Maharashtra, India.

⁴Assistant professor in department of Anatomy, University of Gondar, Ethiopia.

⁵Assistant professor in department of Neurosciences, University of Gondar, Ethiopia.

⁶Associate professor in department of Radiology, University of Gondar, Ethiopia.

Received: April 2018

Accepted: June 2018

Copyright: © the author(s), publisher. It is an open-access article distributed under the terms of the Creative Commons Attribution Non-Commercial License, which permits unrestricted non-commercial use, distribution, and reproduction in any medium, provided the original work is properly cited.

ABSTRACT

Background: An observational study was done on 380 patients (180 male and 200 female) whose abdominal USG was found normal and no disorder was diagnosed which alters the size of spleen to estimate normal linear dimensions of spleen in North-west Ethiopia adult population. **Methods:** The study was conducted between October 2017 and February, 2018 in the University of Gondar Hospital, Ethiopia. Informed verbal consent was taken. The sonographic measurements of spleen length, width and thickness were performed on both genders. **Results:** Two – tailed t-test analysis indicated a statistically significant difference ($p < 0.0001$) between mean splenic dimensions (length, width, thickness, and volume) of male and female subjects. In all measurements, the mean spleen dimensions of male were greater than female. **Conclusion:** The present study provided the normal reference value and range of adult spleen size in both genders for the adults of Northwest Ethiopia, which will be useful for clinical assessment of spleen under any pathological conditions.

Keywords: Ultrasonography, Spleen, Sexual dimorphism.

INTRODUCTION

The spleen is an intra-abdominal organ that may undergo enlargement in pathological condition. Splenomegaly is a clinically important finding that is associated with a number of diseases. A change in splenic size may be due to its own involvement in a disease process or it can be a manifestation of a disease process elsewhere in the body. Therefore, it is important to assess spleen size when physicians evaluate patients.^[1] Assessment of organ size helps in the diagnosis of a disease process or determining its prognosis.^[2]

Haematological disorders include lymphomas and lymphatic leukaemia, haemolytic anaemia, chronic anaemia, congenital spherocytosis and myeloproliferative diseases such as polycythaemia Vera and myelofibrosis. Conditions causing portal hypertension such as cirrhosis or malignancy of

liver invariably involve and cause enlargement of the spleen. Congestive heart failure with ascites and hepatosplenomegaly, lymphoid tissue and haematological malignancies, glycogen storage disorders, sarcoidosis and amyloidosis are other important causes of splenic involvement.^[3-5] The splenic parenchyma consists of lymphatic follicles and reticuloendothelial cells, surrounding the arteries ('white pulp') and an interspersed network of vascular sinusoids ('red pulp').^[3] The ratio of white to red pulp increases with age due to accumulated antigenic exposure and stimulation. There are two circulatory routes through the splenic pulp: open and closed circulation. The closed 'fast flow' circulation drains blood directly into the venous sinusoids, flowing together to become trabecular veins.^[2] In the open 'slow flow' circulation, blood flows into a reticular fibrous framework of the red pulp and/or via the marginal zone of the lymphatic tissue before reaching the sinusoids.^[4] These variable circulatory routes through the splenic pulp may explain the unique inhomogeneous early enhancement pattern of the spleen on computed tomography (CT) and magnetic resonance (MR) imaging.^[1]

Name & Address of Corresponding Author

Dr. Sanket Dadarao Hiware,
Assistant professor
Department of Anatomy,
College of Medicine and health sciences,
Dire Dawa University, Ethiopia.

Spleen is a reticulo-endothelial and lymphoid organ and sometimes works as haemopoietic organ. Otherwise this organ is graveyard of RBCs. Spleen is enlarged in various clinical disorders e.g. infection, metabolism or storage disorder and haematological abnormalities.^[3] Spleen is never palpable till it is enlarged two-three times of its own size. There are many modes of investigation to identify the enlarged spleen e.g. – plane radiograph, sonography, computed tomography, MRI and radionuclide scan. Out of these modalities sonography and computed tomography are most reliable for intra-abdominal organs.^[6] Various studies were done by sonography to study the linear dimension of spleen – length, width, and thickness. Unfortunately, dimensions determined by 2-D USG are limited predominantly by the variable, irregular contour of spleen but also by the difficulty in completely scanning the entire organ or visualizing complete contours as because of the presence of overlying structures such as bone, bowel gas or kidney.^[7]

Ultrasonography is routinely used to evaluate the abdominal organs in the absence of ionizing radiation and invasive intervention. Moreover, it is safe and provides real time images without administration of anaesthesia. Furthermore, during the follow up examination, repeated sonography examination can be safely performed.^[6]

Compared to imaging evaluation of other upper abdominal organs, requests for imaging of the spleen are relatively rare in daily clinical practice. However, the spleen may be involved in a large variety of congenital and acquired disorders. Significant overlap in imaging features among these various conditions is seen; therefore, clinical information is important. The purpose of this paper is to give a comprehensive overview of splenic imaging.

Our study was aimed to give USG-based linear dimension of spleen in population of North-west Ethiopia which was missing till date and to generate the normative data. Ethiopia is a malarial endemic zone and its presence in this large geographical area, makes it difficult to get normal data due to splenomegaly. We tried here to observe the sexual dimorphism in the dimension of spleen in this population.

MATERIALS AND METHODS

The cross-sectional and observational ultrasonic assessment of splenic sizes was done on 380 adult subjects (180 males and 200 females), who came for abdominal ultrasound examination in University of Gondar Hospital. Only those individuals had normal homogenous echo pattern of the spleen, without evidence of any abnormality were included in the study. All subjects involved in this study had normal complete blood count, white

blood cell with differential, red blood cells and normal range of haemoglobin levels 12-18 gram/deciliter.

Following parameters were measured in both the genders:

Spleen length: Measured in longitudinal plane at hilum the maximum distance between the dome of the spleen and the splenic tip.

Spleen width: Measured in a plane perpendicular to the length at hilum the maximum distance between the medial and lateral borders of the spleen.

Spleen thickness: The maximum AP dimension measured on the transverse section.

The patients selected for the present study were examined using a Sonoscape SSI 8000 ultrasound machine (Soonchunhyang University Medical center, China) for abdominal and/or pelvic problems not related to the spleen, mostly due to abdominal pain and urinary tract infection. The study subjects had no history of disease related to the spleen and hematologic, oncologic or traumatic conditions.

Following confirmation of the normal appearance of spleen by physical examination, the study subjects were recruited to the study. For the purpose of ultrasound examination of the spleen, first the subjects were placed in supine position and coupling gel was applied on the abdominal wall in the left hypochondriac region to allow optimal transmission of energy between the patient and the probe. Then, the study participants were asked to lie in the right lateral position with the left side elevated. In order to minimize masking by the lung, the splenic measurements were taken during deep inspiration. Splenic length was measured in the longitudinal section maximum distance between the domes of the spleen and the splenic tip. The splenic width defined as the maximum distance between the medial and lateral borders of the spleen was measured in a plane perpendicular to the length through the hilum. Transverse scans were obtained with the transducer rotated through 90° splenic thickness defined as the maximum AP dimension was measured on the transverse section.

To maintain reproducibility, each measurement was repeated at least 3 times and most repeated value was recorded according to the guidelines of the American Institute of Ultrasound in Medicine and as described by lamp and collaborators.⁸

The volume of the spleen was calculated manually from the formula for a prolate ellipsoid formula (length × width × depth × 0.524) (27). The formula is frequently used for estimation of the volume of many irregularly shaped organs.

The data were entered into a spreadsheet and analysed using the IBM SPSS Statistics, version 20. The means (± standard deviation), ranges, minimum, maximum, and the 95% confidence

intervals for the mean (in order to include the true population mean in 95% of the cases) were all calculated. P- Value less than 0.05 is considered as statistically significant.

RESULTS

A total of 380 adults comprising 180 (47%) males and 200 (53%) females were recruited.

Different linear dimensions and volume of the spleen among males and females in the Northwest Ethiopian population were shown in the above

table [Table 1]. Two – tailed t-test analysis indicated a statistically significant difference ($p < 0.0001$) between mean splenic dimensions (length, width, thickness, and volume) of male and female subjects. In all measurements, the mean spleen dimensions of male were greater than female.

From the above table the maximum measurement obtained for the spleen length, width, and thickness were 13.6 cm, 7.3 cm, 6.2cm, and volume 248.64 cm³, respectively [Table 2, Figure 1,2].

Table 1: Independent sample test for mean difference of spleen dimensions by sex, sonographic study of spleen, Northwest Ethiopia.

Variables	Male		Female		Independent Sample Test	P value (P<0.05)	95% Confidence interval of the difference	
	Mean	SD	Mean	SD			Lower	Upper
	Spleen length	10.56	1.06	9.40				
Spleen width	4.60	0.69	4.07	0.68	7.476	0.000	0.390	0.668
Spleen thickness	4.08	0.83	3.67	0.87	4.633	0.000	0.234	0.579
Spleen volume	107.7	37.42	78.02	33.7	8.13	0.000	22.506	36.854

Table 2: Maximum and minimum dimensions of spleen.

Physical data	Range		Male		Female	
	Minimum	Maximum	Minimum	Maximum	Minimum	Maximum
Spleen Length(cm)	7	13.6	7.7	13.6	7	13
Spleen Width(cm)	2.4	7.3	2.8	7.3	2.4	6
Splenic thickness (cm)	2.1	6.2	2.3	6.2	2.1	5.7
Splenic Volume (cm ³)	23.5	248.64	37.17	248.64	23.5	180.6

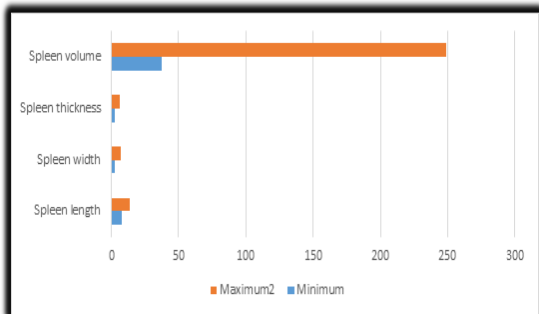


Figure 1: Range of spleen dimensions in male population of Northwest Ethiopia.

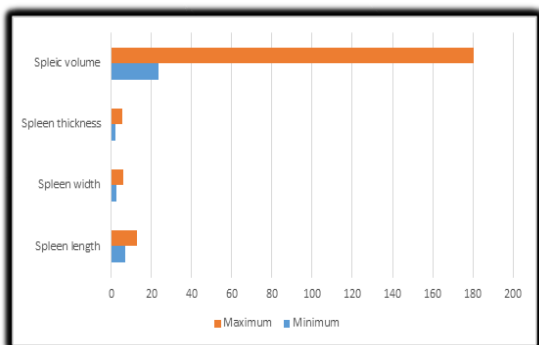


Figure 2: Range of spleen dimensions in female population of Northwest Ethiopia.

DISCUSSION

Gross splenomegaly can be detected both clinically and sonographically. But, the clinical examination is far from accurate to detect a small increase in spleen size. It must be two to three times enlarged before it is palpable. The precise measurement of spleen by palpation is not reliable, as in cases a normal sized spleen is palpable and a non-palpable spleen may not be normal sized. Ultrasonography is a good modality for the detection of splenomegaly even when it is not clinically palpable.^[2,8]

The spleen varies considerably in size. But, on average it is 2.5 cm thick, 7.5 cm wide and 12.5 cm long.^[4] A sonographic study of adult spleen showed that spleen size decreased with increasing age. And, as it is reported from autopsy findings, the size of spleen was smaller in females than male study subjects.^[7]

Very recent retrospective study done on 495 patients in the western region of Nigeria reported the mean scores of spleen in coronal view (9.48±1.61 cm), sagittal view (8.63±1.77 cm), axial view (9.72±2.0 cm) and the spleen volume (445.1±238.6).^[8]

A recent cross sectional report of Tripura revealed that the mean spleen length of male adult were 8.85 ± 1.54 cm and the mean spleen length of female

adult were 8.72 ± 0.89 cm. The range of spleen length in adults varied from 4.41 cm to 12.33 cm and in most of the cases (95.2%) the spleen length was below 11 cm. It was reported that with increased age, the spleen length was decreased.^[9]

A prospective study conducted among adult Nepalese people in Western Nepal revealed that the splenic dimensions for males were greater than females. They found that the mean spleen length and thickness of male were 9.67 ± 0.59 cm and 3.65 ± 0.45 cm, respectively, whereas the mean spleen length and thickness of female were 9.35 ± 0.53 cm and 3.37 ± 0.38 cm, respectively. They found that the splenic length and thickness decreased with increase in age of both males and females. However, all splenic dimensional measurements were greater in males than females.^[10] Similarly, report from Eastern Nepal indicated that the mean spleen length, width and thickness of male were 9.8 ± 1.18 cm, 4.9 ± 0.9 cm and 3.89 ± 0.62 cm respectively; however, the mean spleen length, width and thickness of female were 9.2 ± 1.26 cm, 4.43 ± 0.6 cm, respectively. The length, width and thickness of spleen were larger in male as compared to that of the female and decreased as age increased ($P < 0.05$).^[11]

A study done in North India reported that the mean splenic length, width and thickness in male were 9.97 ± 1.24 cm, 4.83 ± 0.19 cm and 3.79 ± 0.62 cm, respectively; on the other hand, in female study subjects the mean splenic length was 9.24 ± 1.3 cm, width was 4.34 ± 0.99 cm and thickness of 3.39 ± 0.64 cm. They concluded that the spleen dimension of male were greater than in females. In both male and female, the splenic length decreased at a slow rate up to the age of 50 years after which it decreased rapidly and thickness in both male and female was constant up to the age of 50 years after which it falls rapidly but the width slightly decreases with age up to 30 years and remained constant up to 50 years then decreased rapidly.^[12] Study conducted in adult Manipur, where 200 subjects were scanned male 84 and female 116 age ranges 21-70yrs reported that the splenic length decreased with increase of age of individual. They reported also the males had longer spleen than females.^[13]

A study conducted in Turkish population in a total of 2179 volunteers, healthy men aged 17-42 years were scanned. Mean spleen length was 10.76 ± 1.84 cm. However, the spleen length had no statistically significant correlations ($p < 0.01$) with body height, weight and BMI. Pearson correlation coefficients between spleen length and body height, body weight and BMI were 0.76, 0.73 and 0.34, respectively. In 95% of the study participants, the length of the spleen was less than 12.80 cm.^[14] Moreover, recent report from Turkish adults study participants revealed that male splenic dimension measurements are greater than corresponding

female subjects. Accordingly, male mean spleen dimensions (length, width and thickness) were 11.01 ± 1.186 cm, 8.75 ± 1.84 cm and 4.12 ± 1.09 cm, respectively; nonetheless, in female mean spleen dimension (length, width and thickness) were 9.87 ± 1.28 cm, 7.58 ± 1.56 cm and 3.34 ± 0.79 cm, respectively.^[15]

A study conducted in china revealed that 783 patients not known to have any condition likely to be associated with splenic enlargement were scanned. They suggested that spleen grows rapid in splenic length up to age 20 years, followed by a mild decrease. They reported statistically significant difference between male and female subjects. Male mean spleen length being 0.5 cm longer than female.^[16]

Another study done on adult Bihar subjects, age range from 20- 60yrs reported that the spleen width increased with increase in the height in both males and the females. The spleen width was greater in males than in females. In the males ($r=0.03$, $t=2.78$, $P < 0.01$) as well as the females ($r=0.23$, $t=2.13$, $P < 0.05$) a positive statistically significant correlation of the spleen width with the height was reported.^[17]

CONCLUSION

In the present study, an attempt has been made to determine and compare the normal range of the length, width, thickness and volume of the spleen in both the genders. All the dimensions of spleen (length, width, thickness and volume) were found to be significantly (< 0.05) greater in male than in female.

REFERENCES

1. Kardel T, Holm HH, Rasmussen SN: Ultrasonic determination of liver and spleen volumes. *Scand J clin lab Invest* (1971); 27:123.
2. Rosenberg HK, Morkowitz RI, Kolberg H, Park C, Hubbard A, Bellah RD: Normal splenic size in infants and children: sonographic measurements. *AJR* (1991); 157:119-121.
3. De Odorico I, Spaulding KA, Pretorius DH, Lev-Toaff AS, Baily TB and Nelson TR et al.: Normal splenic volumes estimated using three dimensional ultrasonography. *J ultrasound Med* (1999); 18:231-236.
4. Prassopoulos P, Daskalogiannaki M, Raissaki M, Hatjidakis N, Gourtsoyiannis N: Determination of normal splenic volume on computed tomography in relation to age, gender and body habitus. *Eur. Radiol.* (1997); 7:246-48.
5. Ishibashi H, Higuchi N, Shimamura R, et al: Sonographic assessment and grading of spleen size. *J clin ultrasound* (1991); 19:21.
6. Brieman RS, Beck JW, Korobin M: Volume determinations using computed tomography. *AJR* (1982); 138:329.
7. Lamb PM, Lund A., Kanagasabay RR, Martin A, webb JA and Reznik RH et al.: Spleen size: How well do linear ultrasound measurements correlate with three dimension CT volume assessments? *Br J Radiol.* (2002); 75:573-77.
8. Ezeofor SN, Obikili EN, Anyanwu GE, Onuh AC, Mgbor S. Sonographic assessment of the normal limits of the spleen in

- healthy school children in South east Nigeria. Niger J Clin, Pr. 2014;17(4):484–6.
9. Chakraborti S, Saha N, Debbarma B, Das S, Leishram D. Normal Spleen Length by Ultrasonography in Adults of Tripura. IOSR J Dent Med Sci. 2016;15(1):55–60.
 10. Sharma K, Lamichhane PS, Sharma B, Sharma BK. Sonographic Measurement of Spleen in Relation to Age. A Prospective Study among Adult Nepalese People in Western Nepal. J Gandaki Med Coll Nepal. 2017;10(1):11–6.
 11. Yadav BK, Sharma LK, Yadav SR, Chakradhar S, Neupane I. sonographic measurements of the spleen in relation to age; a prospective study in eastern Nepalese adults. J Biomed Pharm Res. 2013;2(3):118–21.
 12. Arora N, Sharma PK, Sahai A, Singh R. Sonographic measurements of the spleen in relation to age; a prospective study in north Indian adults. J Anatsoc India. 2010;59(2):177–81.
 13. Gangte SD, Singh NS, Singh MM, Singh WJ. Ultrasonographic Measurement of Splenic Length In Relation To Age of Adult ' s in Manipur. IOSR J Dent Med Sci. 2015;14(10):43–5.
 14. Serter S, Ceylan C, Tuncyurek O, Orguc S, Pabuccu Y. Sonographic evaluation of spleen size and prevalence of accessory spleen in a healthy male Turkish population. Turk J Hematol. 2010;27(2):25–8.
 15. Celiktas M, Ozandac S, Goker P, Bozkir M. Sonographic Determination of Normal Spleen Size in Turkish Adults. IntJMorphol. 2015;33(4):1401–5.
 16. Loftus WK, Metreweli C. Normal splenic size in a Chinese population. J Ultrasound Med. 1997;16(5):345–7.
 17. Singh A, Chandra N, Ansari H, Das JK. Measurement of spleen width in relation with the height in the adults of Bahir. Anat Sci. 2016;24(1):13–7.

How to cite this article: Tekle Y, Hiware SD, John SP, Abreha M, Muche A, Tegegne Z. Sexual Dimorphism in the Dimensions of Spleen in the Population of North-West Ethiopia –An Observational Radiographic Study.. Ann. Int. Med. Den. Res. 2018; 4(4):AT38-AT42.

Source of Support: Nil, **Conflict of Interest:** None declared