

# Broken Airway Exchange Catheter- A Rare and Serious Complication.

Pardeep Kumar, SK Singhal, Naveen Malhotra, Nitu Yadav

<sup>1</sup>Senior Resident, Deptt of Anaesthesiology, PGIMS, Rohtak.

<sup>2</sup>Senior Professor, Deptt of Anaesthesiology, PGIMS, Rohtak.

<sup>3</sup>Professor, Deptt of Anaesthesiology, PGIMS, Rohtak.

<sup>4</sup>PG student, Deptt of Anaesthesiology, PGIMS, Rohtak.

Received: October 2018

Accepted: October 2018

**Copyright:** © the author(s), publisher. It is an open-access article distributed under the terms of the Creative Commons Attribution Non-Commercial License, which permits unrestricted non-commercial use, distribution, and reproduction in any medium, provided the original work is properly cited.

## ABSTRACT

An airway exchange catheter is also called a guiding catheter, stylet catheter and tube changer or exchanger. It is used for exchanging an endotracheal tube in a patient who was difficult to intubate. It decreases the risk of airway difficulties in patients with an uncompromised laryngeal view during direct laryngoscopy. We present a case report in which an endotracheal tube exchange was planned in a 21 years old female patient with post burn neck contractures, but failed.

**Keywords:** Airway, Airway Exchange Catheter.

## INTRODUCTION

An airway exchange catheter is also called a guiding catheter, stylet catheter and tube changer or exchanger. It is used for exchanging an endotracheal tube in a patient who was difficult to intubate. It decreases the risk of airway difficulties in patients with an uncompromised laryngeal view during direct laryngoscopy.<sup>[1]</sup>

## Case Report

A 21 year old female patient, weighing 47kgs was scheduled to undergo postburn neck contracture release surgery in the elective operation theatre. Patient had history of burns of face and neck 2 years back while cooking. No other positive history or associated comorbidity was present. On examination patient had difficult airway with mouth opening of 1 finger and no extension and flexion of neck. All other investigations were within normal limits. So fiberoptic guided nasal intubation was planned. Nasal preparation of the patient was done with xylometazoline nasal drops on the day of the surgery. Fiberoptic guided nasal intubation was done through right nostril using endotracheal tube of internal diameter (ID) 7mm. But when cuff was

inflated, leak was detected. So it was decided to exchange the tube using airway exchange catheter. The endotracheal tube which was in situ was replaced with airway exchange catheter (AEC). But replacing this AEC with new endotracheal tube of ID 7mm failed even after multiple attempts. So AEC was taken out and it was planned to intubate again with fiberoptic endoscope. On examination with fiberoptic endoscope a small AEC part was found just above the vocal cords [Figure 1]. When AEC was examined, a small part was found missing. Luckily no broken part was pushed further into trachea or esophagus. Patient was intubated using fiberoptic endoscope. Surgery started thereafter. Maintenance of anaesthesia was done using sevoflurane and usig inj. atracurium as a muscle relaxant. Analgesia was given in the form of inj. fentanyl 120µg and inj. paracetamol 100ml iv. Surgery completed uneventfully and patient was extubated successfully. After extubation patient was shifted to the recovery room and monitored for 2-3 hours before shifting to ward.

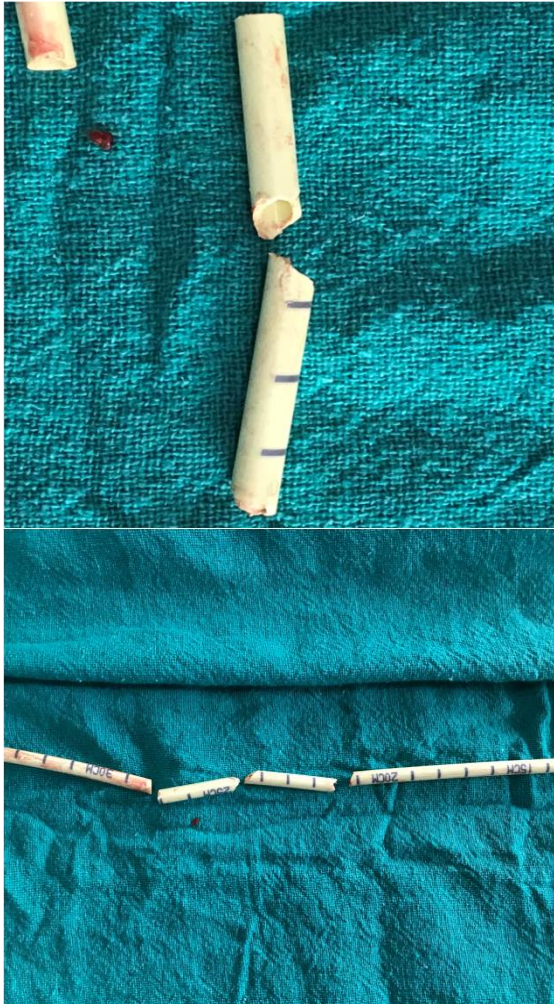
## DISCUSSION

Airway exchange catheters have been used to change ETT more safely as well as to maintain access to the airway after extubation, so reversible extubation if needed can be allowed.<sup>[2-4]</sup> Successful reintubation of the trachea with an AEC for a difficult extubation is not a new concept.<sup>[5]</sup> Other use of AEC is to provide ventilation during microlaryngeal surgery. It is useful to re-establish an airway if a problem occurs while tracheostomy is being performed, and may

### Name & Address of Corresponding Author

Dr Pardeep Kumar,  
Senior Resident,  
Deptt of Anaesthesiology,  
PGIMS  
Rohtak.

guide the surgeon to the tracheal lumen. Another use if AEC is during retrograde intubation. It can be used for ventilating the patient during management of intraoperative tracheal injury, facilitating passage of a tracheal tube over a fibroscope.



**Figure 1: Broken Airway Exchange Catheter with recovered parts**

There are a number of complications associated with AEC, the breaking off part of the catheter is one of them. It is possible but uncommon. So expiry of the AEC should be checked beforehand to avoid this. In case of doubt airway should be examined using fiberoptic endoscope. Other complications are airway perforation, barotraumas due to jet ventilation. The channel in the exchange catheter may become occluded with secretions or the mucous plug may dislodge leading to airway obstruction.<sup>[1]</sup> The catheter may exit through side hole in the tracheal tube. McLean et al studied AEC failure and its complications in 1177 cases in a single cohort study in 2013. Among 1177 cases, failed intubation during attempted tube exchange was noted in 73/527 (13.8%).

## CONCLUSION

Airway exchange catheters has been used in difficult airway cart since years. It is also associated with complications and failures. So be ready for next option. Breaking off AEC is uncommon but possible complication, so expiry of the catheter should be checked beforehand along with visual inspection.

## REFERENCES

1. Dorsch JA, Dorsch SE. Tracheal Tubes And Associated Equipment. Understanding Anesthesia Equipment. 5<sup>th</sup> Ed. Philadelphia: Wolters Kluwer; 2008.p.606-9.
2. Dosemeci L, Yilmaz M, Yegin A, Cengiz M, Ramazanoglu A. The routine use of pediatric airway exchange catheter after extubation of adult patients who have undergone maxillofacial or major neck surgery: a clinical observational study. Critical Care 2004;8:385-9.
3. Loudermilk EP, Hartmanngruber M, Stoltfus DP, Langevin PB. A prospective study of the safety of tracheal extubation using a pediatric airway exchange catheter for patients with a known difficult airway. Chest 1997;111:1660-5.
4. Cooper RM. The use of an endotracheal ventilation catheter in the management of difficult extubations. Can J Anaesth 1996;43:90-3.
5. Mort TC. Continuous Airway Access for the Difficult Extubation: The Efficacy of the Airway Exchange Catheter. Anesth Analg 2007;105:1357-62.

**How to cite this article:** Kumar P, Singhal SK, Malhotra N, Yadav N. Broken Airway Exchange Catheter- A Rare and Serious Complication. Ann. Int. Med. Den. Res. 2018; 4(6):AN25-AN26.

**Source of Support:** Nil, **Conflict of Interest:** None declared