

A Comparative Study On Post-Operative Analgesia With Clonidine And Dexmedetomidine As An Adjuvant To Ropivacaine Under Ultrasound Guided Fascia Iliaca Compartment Block In Patients Scheduled For Hip And Femur Surgeries: A Randomized, Double Blind, Control Trial.

Shyam Bhandari¹, Jai Singh², Versha Verma¹, Gopal Singh³, Manju⁴, Chittra⁵

¹Assistant Professor, Department of Anaesthesia, Dr. RPGMC Tanda at Kangra, Himachal Pradesh.

²Professor, Department of Anaesthesia, Dr. RPGMC Tanda at Kangra, Himachal Pradesh.

³Junior Resident, Department of Anaesthesia, Dr. RPGMC Tanda at Kangra, Himachal Pradesh.

⁴Senior Resident, Department of Medicine, Dr. RPGMC Tanda at Kangra, Himachal Pradesh.

⁵Senior Resident, Department of Anaesthesia, Dr. RPGMC Tanda at Kangra, Himachal Pradesh.

Received: June 2018

Accepted: July 2018

Copyright: © the author(s), publisher. It is an open-access article distributed under the terms of the Creative Commons Attribution Non-Commercial License, which permits unrestricted non-commercial use, distribution, and reproduction in any medium, provided the original work is properly cited.

ABSTRACT

Background: Fascia iliaca is one of the most commonly performed and safest block. Local anaesthetic diffuses under the fascia iliaca to block femoral nerve, lateral cutaneous femoral nerve, and obturator nerves. Clonidine, α_2 -adrenergic receptor agonist, has potent central and peripheral antinociceptive properties. Dexmedetomidine, is a potent α_2 -adrenoceptor agonist with dose dependent α_2 receptor sensitivity. Receptors for α_2 are found in the peripheral and central nervous system, platelets, and a variety of organs, such as the liver, pancreas, kidney, and eye. It exhibited dose dependent protection against brain matter loss in vivo and improved the neurologic functional deficit induced by the hypoxic ischemic insult. Aim: To compare clonidine and dexmedetomidine as an adjuvant to ropivacaine under ultrasound guided fascia iliaca for post-operative analgesia scheduled for hip and femur surgeries under subarachnoid block. **Methods:** It was a Randomized controlled trial study. The patients were allocated one of the three groups which are group R (n=30), Control group – 40 ml of 0.25% Ropivacaine in fascia iliaca compartment block, group RC (n=30) Clonidine group– 40ml of 0.25% Ropivacaine+ 0.5 μ g/kg Clonidine in fascia iliaca compartment block and group RD (n=30) Dexmedetomidine group – 40ml of 0.25% Ropivacaine + 0.5 μ g/kg Dexmedetomidine in fascia iliaca block by random number chart. 90 patients of both sexes in the age group of 20-60 years were taken in the study. This study was conducted in the department of Anesthesiology, Dr. R.P.G.M.C, Tanda at Kangra, Himachal Pradesh. **Results:** Time to first rescue analgesia was maximum in RD group as compared to RC group followed by R group and it was statistically significant amongst groups. Mean of total number of rescue analgesic i.e. inj. diclofenac required was 2.60 ± 0.50 (dose) in R group as compared to 1.50 ± 0.51 in RC group and 1.03 ± 0.18 in (RD) group. There was statistically significant difference in need for analgesia amongst R, RC and RD groups ($P < .001$). **Conclusion:** It is recommended that dexmedetomidine in a dose of 0.5 μ g/kg can be used as an adjunct to ropivacaine (less cardio toxic) under ultrasound guided fascia iliaca compartment block, for better postoperative pain relief and prolonged duration of postoperative analgesia. It reduces the postoperative rescue analgesic requirement with arousable sedation and without any adverse effect.

Keywords: postoperative analgesia, Clonidine, Dexmedetomidine, ropivacaine, Fascia iliaca.

INTRODUCTION

As we know that, pain is a subjective and multidimensional experience, which is ignored by healthcare providers. local anaesthetic diffuses

under the fascia iliaca to block femoral nerve, lateral cutaneous femoral nerve, and obturator nerves.^[1] Fascia iliaca block is a safe and effective technique for postoperative analgesia after hip fracture surgery, making it an option for pain management in hip fractures.^[2] Clonidine, α_2 -adrenergic receptor agonist, has powerful focal and fringe antinociceptive properties. Dexmedetomidine, is a powerful α_2 -adrenoceptor against with measurements subordinate α_2 receptor affectability. Receptors for α_2 are found in the fringe

Name & Address of Corresponding Author

Dr. Gopal Singh,
Junior Resident,
Department of Anaesthesia,
Dr. RPGMC Tanda at Kangra,
Himachal Pradesh, India.

and focal sensory system, platelets, and an assortment of organs, for example, the liver, pancreas, kidney, and eye.^[3-5]

Ropivacaine is a long-acting amide local anaesthetic agent and first local anaesthetic produced as a pure enantiomer. It produces effects similar to other local anaesthetics via reversible inhibition of sodium ion influx in nerve fibres.

Regional anaesthesia techniques provide important advantages compared with general anaesthesia and systemic analgesia, including excellent pain control, reduced side-effects, and shortened stay in the post-anaesthesia care unit.^[6] Being described in 1989, it was performed initially in children and later on in adults. It was used for post operative pain relief for surgeries around hip, femur and knee..

Bernard et al used clonidine in axillary nerve block and suggested that small dose of clonidine enhances the quality of the peripheral blocks with lidocaine and limits the classical α_2 agonist side effects of sedation. They concluded that the best dose of clonidine to use is between 30 and 90 μg along with lidocaine in axillary nerve block.^[7]

Lopez S, Gros T, et al conducted a study to evaluate the effectiveness of fascia iliaca compartment block for analgesia after a femoral bone fracture in pre-hospital care. They used 20 mL of lidocaine 1.5 % with epinephrine for fascia iliaca block. The intensity of pain was measured using a simplified verbal scale (SVS) from 0 (no pain) to 4 (extreme pain). They concluded that fascia iliaca compartment block is a simple, inexpensive and effective method of prehospital analgesia for femoral shaft fractures and a sensory block of the internal part of the thigh is an early predictive sign of optimal pain relief.^[8]

YaDeau et al in a randomized, double-blind, placebo-controlled trial tested ninety-nine patients scheduled for foot or ankle surgery. In this study, patients received a popliteal nerve block with 30 ml of bupivacaine (0.375%) with epinephrine. Patients were randomized to receive no clonidine, 100 μg clonidine intramuscular or 100 μg clonidine with bupivacaine through popliteal nerve block. Analgesia in the group that received clonidine mixed with bupivacaine lasted for a mean of 18.3 h (95% confidence intervals of 17.3 through 19.3 h). Analgesia in the control group lasted for a mean of 14.8 h (95% confidence intervals of 13.5 through 16.0 h).^[9]

Recent development in the field of peripheral nerve blocks is use of Dexmedetomidine, potent α_2 adrenoceptor agonist. These agents are attractive alternative for patients who require potent postoperative analgesia and reduced opioid induced systemic side effects.^[10]

We aimed to compare duration of post-operative analgesia with clonidine and dexmedetomidine as an adjuvant to ropivacaine under ultrasound guided fascia iliaca compartment block (FICB) in patients

scheduled for hip and femur surgeries after subarachnoid block. The block characteristics were compared in terms of duration of analgesia, postoperative pain scores, number of demands for rescue analgesics and sedation scores.

MATERIALS AND METHODS

It was a randomised control trial study. The study was conducted for a period of one year including data collection, data organization, presentation, data analysis and data interpretation. The patients were allocated one of the three groups (R, RC and RD) by computer generated block randomisation. The study drug solution was prepared and given to the investigator by a nonparticipant staff. The study was conducted in the department of Anesthesiology, Dr. R.P.G.M.C, Tanda at Kangra, Himachal Pradesh. 90 patients were allocated one of the three groups (R, RC and RD) by random number chart. The drug solution was prepared and given to the investigator by a nonparticipant staff. 90 patients of both gender in the age group of 20-60 years were taken in the study. Patients belonging to ASA grade 1&2 were scheduled for surgeries of hip and femur respectively. All patients within this duration and fulfilling our Inclusion criteria i.e. males and females between the age group 20-60 years, ASA class I-II, BMI between 18.5 to 29.9 and those undergoing for surgeries of hip and femur. Exclusion criteria were patient's refusal for block, history of cardiac, renal or hepatic disease, neuropathy, hypersensitivity to local anesthetics, local infection at the site, allergy to study drugs, patients in whom the block effect was partial and required supplementary anesthesia in the study. The enrolled patients after fulfilling all the inclusion and exclusion criteria were divided into 3 groups which are:

Group R (n=30) Control group – 40 ml of 0.25% Ropivacaine in FICB

Group RC (n=30) Clonidine group– 40ml of 0.25% Ropivacaine+ 0.5 $\mu\text{g}/\text{kg}$ Clonidine FICB

Group RD (n=30) Dexmedetomidine group – 40ml of 0.25% Ropivacaine + 0.5 $\mu\text{g}/\text{kg}$ Dexmedetomidine in FICB

Pain level was quantified with visual analog scale (VAS) pain score, with 0 representing no pain and 10 representing the worst imaginable pain. Patient were evaluated for sedation using modified Ramsay sedation Score (Awake as score 1, drowsy as score 2, Asleep but arousable as score 3, Arousable with mild physical stimulus as score 4 and Not arousable with mild physical stimulus as score 5 respectively) The study was commenced after obtaining institutional scientific review, protocol committee and ethical committee approval and written informed patient consent.

All patients were kept nil orally for eight hours before the surgery. Premedication were given in the form of tablet alprazolam 0.5mg and tablet ranitidine

150mg HS and 6:00 am on the day of surgery. On arrival to operation theatre, standard monitoring (i.e. five lead ECG, NIBP, Spo2) was established along with starting of peripheral I.V. line with 18G I V cannula with normal saline.

All patients included in study were given subarachnoid block (SAB) after cleaning and draping in lateral position using 26G Quincke's spinal needle in L3-L4 interspinous space with 3 mL of 0.5% hyperbaric bupivacaine. After confirmation of adequate level (T8), surgeon was allowed to proceed with the surgery, intraoperative blood pressure, pulse, spo2 were measured every 15 minutes. After completion of surgery and regression of level to T12, FICB was given under USG guidance.

The patient was placed in supine position. A line was drawn on the skin connecting anterior superior iliac spine (ASIS) and pubic tubercle and at the junction of the lateral 1/3rd and medial 2/3rd and a second line was drawn perpendicular to and intersecting the previous line joining anterior superior iliac spine and pubic tubercle. After cleaning and draping and covering ultrasound probe with aseptic cover, 6 to13 MHZ linear USG probe was kept at the intersection line in cephalo-caudal direction. A blunt sterile 50mm of 22G insulated needle was inserted in caudo-cephalic direction in plane and as the needle passed through fascia iliaca, a pop up felt and fascia was seen to snap back on the ultrasound image. After negative aspiration, 1to 2ml of study local anesthetics was injected to confirm the proper injection plane between the fascia and the iliopsoas muscle. If the local anesthetic was spread above the fascia or within the substance of muscle itself, additional needle repositioned and injection was necessary. A proper injection resulted in the separation of the fascia iliaca by the local anesthetic in the medial to lateral direction from the point of injection. After confirmation, drug was injected as per group of the patients.

Statistical analysis: Data was collected and entered in MS Excel 2007. Statistical analysis was performed using SPSS software 15. Normally distributed data was analyzed using a repeat-measures general linear model analysis of variance (ANOVA), whereas categorical data was analyzed using the Chi-square test. For comparison between two groups unpaired t test was applied in normally distributed data. The Bonferroni correction was used to correct for multiple testing at different time points.

RESULTS

There was no statistically significant difference in demographic profile of patients in three groups [Table 1]. There was no clinically significant difference in baseline hemodynamic parameters of patients in three groups. Systolic Blood Pressure (SBP), Diastolic Blood Pressure (DBP), Mean Blood

pressure and Heart Rate (HR) showed statistically significant in postoperative period in Group R as compare to Group RD and Group RC though clinically insignificant. [Figure 1 & Figure 2]

Table 1: Group wise distribution of patients on the basis of Clinico-demographic factors.

	Group RC	Group RD	Group R	P-value
Male	22 (24.4)	24 (26.7)	25 (27.8)	0.628
Female	8 (8.9)	6 (6.7)	5 (5.6)	
Mean Age (years)± SD	41.70 ± 14.61	39.17 ± 15.74	42.30 ± 11.64	0.660
Mean weight (Kg) ± SD	57.27 ± 5.64	58.13 ± 3.92	59.30 ± 5.32	0.360
Mean height (Cm) ± SD	158.77 ± 7.30	157.87 ± 6.20	164.93 ± 7.14	0.053
Mean BMI (Kg/Cm2) ± SD	22.67 ± 1.58	23.48 ± 1.67	21.73 ± 1.11	0.213
Mean duration of surgery (Minutes) ± SD	177.17 ± 24.02	170.10 ± 29.80	172.33 ± 18.70	0.096

Table 2: Group wise distribution with time to first rescue analgesia and total number of rescue analgesia in 24 hrs

	Group RC	Group RD	Group R	P-value
Time to first rescue analgesia (Min) (Mean ± SD)	712.00 ± 117.63	885.52 ± 144.90	238.00 ± 10.95	F = 288.704 df = 2 p value = < 0.001
Total number of rescue analgesic (Mean ± SD)	1.50 ± 0.51	1.03 ± 0.18	2.60 ± 0.50	F = 107.794 df = 2 p value = < 0.001

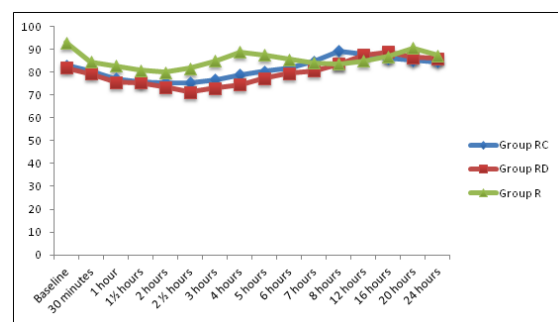


Figure 1. Comparison of Mean Blood Pressure among three study groups in first 24 hours

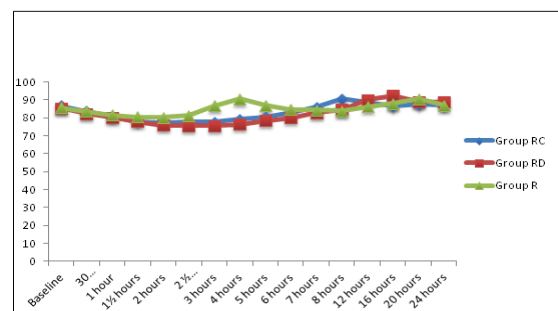
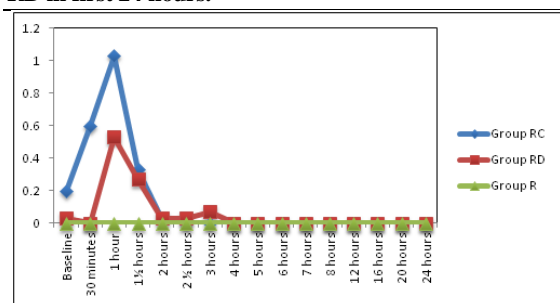


Figure 2: Mean HR in Group R, Group RC and Group RD in first 24 hours.**Figure 3. Sedation Score among three groups in first 24 hours**

Time to first rescue analgesic was maximum in RD group as compared to RC group followed by R group. It was statistically significant amongst groups. Mean of total number of rescue analgesic i.e. inj. diclofenac required was 2.60 ± 0.50 (dose) in R group as compared to 1.50 ± 0.51 in RC group and 1.03 ± 0.18 in (RD) group. There was statistically significant difference in need for analgesia amongst R, RC and RD groups ($P < .001$).

Statistically significant difference in mean sedation scores were found in Group RD and Group RC as compared to Group R group at 30 minutes to 1.5 hour. Sedation scores were comparable after two hours.[Figure 2]

DISCUSSION

In this study, we compare the efficacy of equi-doses of clonidine and dexmedetomidine as an adjuvant to ropivacaine in USG guided fascia iliaca compartment block for postoperative analgesia in hip and femur surgeries. In the present study, mean duration of analgesia was significantly prolonged in dexmedetomidine group (15.39 ± 1.38 hours) and clonidine group (12.54 ± 0.815 hours) as compared to control group (6.55 ± 0.37 hours) and found statistically highly significant relationship in group (P value = 0.00). Similarly current study also shows significantly lower VAS scores with the use of both dexmedetomidine and clonidine. But statistically significant difference was observed after 2.30 hour up to 20 hour among clonidine and dexmedetomidine group with control group. The total doses (no.) of rescue analgesics required was minimum in RD group (23.70) followed by RC group (40.50) and maximum in R group (72.30). All patients were comfortable, responded to commands and awake in postoperative period in all the three groups as evaluated for sedation by using modified ramsay sedation score and found statistically significant relationship amongst all the group at 0 hour to 1.5 hour and maximum patients were found very satisfied in RD group followed by RC group but no patient was found very satisfied in R group.

Monzon DG, et al,^[11] tested the efficacy of using fascia iliaca blocks (FICB), by adding clonidine with bupivacaine and found no need of any rescue analgesia required. There is prolongation of analgesic action of bupivacaine by clonidine in vivo is unclear and not mediated by an alpha adrenergic mechanism but attributed to its direct inhibitory effect on peripheral nerve conduction by A and C fibers. In our study, we also found by adding clonidine with ropivacaine increase the analgesic action and rapid, safe and excellent control on pain by using USG guided (FICB) in comparison to control group.

Ya Deau JT et al,^[12] in a randomized, double-blind, placebo-controlled trial tested ninety-nine patients scheduled for foot or ankle surgery. The patients received a popliteal nerve block with 30 ml of bupivacaine (0.375%) with epinephrine. Patients were randomized to receive no clonidine, 100 µg clonidine intramuscular (IM) or 100 µg clonidine with bupivacaine through popliteal nerve block. Duration of analgesia was statistically longer in the block clonidine group (18 ± 6 h for clonidine with bupivacaine vs 14 ± 7 h for IM clonidine and 15 ± 7 h for control, $P = 0.016$ for control vs clonidine with bupivacaine). Pain scores, analgesic use, and side effects attributable to pain management were similar among groups.

Yoshitomi T, et al,^[13] in 2008 conducted a study to evaluate the effect of dexmedetomidine and other alpha-2 adrenoceptor agonists on the local anesthetic action of lidocaine at the periphery and explored the mechanism involved. They injected alpha-2 adrenoceptor agonists, including dexmedetomidine, clonidine, and oxymetazoline, combined with lidocaine intracutaneously into the back of male guinea pigs. They concluded that by adding dexmedetomidine increase the duration of analgesia which is consistent with our findings.

Esmaoglu Aitkin, et al,^[14] concluded that dexmedetomidine added to levobupivacaine for axillary brachial plexus block shortens the onset time and prolongs the duration of the block and the duration of postoperative analgesia. Bradycardia was noticed in some patients. These findings were consistent with our current study that showed that adding the dexmedetomidine and clonidine was potent and effective for longer analgesia and blockage. Among dexmedetomidine and clonidine, dexmedetomidine has more prolonged effect.

In our study, we didn't notice any episode of clinically significant bradycardia in contrast to other studies. It may be attributed to relatively smaller doses of dexmedetomidine and clonidine used in our study.

CONCLUSION

We concluded that the use of $0.5 \mu\text{g}/\text{kg}$ clonidine and $0.5 \mu\text{g}/\text{kg}$ dexmedetomidine as an adjuvant to ropivacaine under ultrasound guided fascia iliaca

compartment block in patients scheduled for hip and femur surgeries after subarachnoid block reduces postoperative pain scores, prolongs the duration of analgesia, decreases demands for rescue analgesia and produce arousable sedation without causing any serious adverse effects. The duration of analgesia was maximally prolonged in RD group.

So it is recommended that dexmedetomidine in a dose of 0.5µgm/kg can be used as an adjunct to ropivacaine (less cardiotoxic) under ultrasound guided fascia iliaca compartment block, for better postoperative pain relief and prolonged duration of postoperative analgesia. It can reduce the rescue analgesic requirement with arousable sedation without any adverse effect.

Limitation

Major limitation of this study could be that it was conducted on small scale by taking smaller sample sizes. If it was carried out by taking larger sample sizes, then the results and conclusions would be more generalised and implacable. Another limitation of our study was that it was not possible to evaluate the onset of sensory and motor blockade due to residual spinal anaesthesia. We could study pain scores at 12 and 24 postoperatively and total analgesia requirement in first 24 hrs only.

REFERENCES

1. Gray at. Ultrasound guided regional anesthesia current state of art. *Anesthesiology*. 2006; 104:368-73
2. Olivier C, Jean P, Jenna B, Diane D. The efficacy of continuous fascia iliaca compartment block for pain management in burn patients undergoing skin grafting procedures. *2004*; 98(4):1077-81.
3. H Nie, Y-X Yang, Y Wang, Y Liu, B Zhao, B Luan. Effects of continuous fascia iliaca compartment blocks for postoperative analgesia in patients with hip fracture. *Pain Res Manag* 2015;20 (4):210-212.
4. Carollo DS, Nossaman BD. Dexmedetomidine: a review of Applications. *Curr Opin Anesthesiol* 2008; 21:457.
5. Memis D, Turan A, Karamanlioglu B, Pamuku Z, Kurt I. Adding dexmedetomidine to Lidocaine for intravenous regional anesthesia. *Anesth Analg* 2004;98:835-40
6. Ma D. Dexmedetomidine produces its neuroprotective effect via the alpha 2Adrenoceptor subtype. *Eur J Pharmacol*. 2004 Oct 11;502 (12): 87-97
7. Bernard JM, Macaire P. Dose-range effects of clonidine added to lidocaine for brachial plexus block. *Anesthesiology* 1997; 87; 277-84
8. Oberndorfer U, Marhofer P, Bo'senberg A, Willschke H., Felfernig M, Weintraud M, et al Ultrasonography guidance for sciatic and femoral nerve blocks in children. *Br J Anaesth* 2007; 98: 797-801.
9. Lopez S, Gros T, Bernard N, Plasse C, Capdevila X. Fascia iliaca compartment block for femoral bone fractures in prehospital care. *Reg Anesth Pain Med*. 2003 May-Jun; 28(3):203-7.
10. De Wolf AM, Fragen RJ, Avram MJ, Fitzgerald PC, Rahimi Danesh F. The pharmacokinetics of dexmedetomidine in volunteers with severe renal impairment. *Anesth Analg* 2001;93:1205-9.
11. Monzon DG, Iserson KV, Vazquez JA. Single fascia iliaca compartment block for post-hip fracture pain relief. *J Emerg Med*. 2007; 32(3):257-62
12. YaDeau JT, LaSala VR, Paroli L, Richard L, Kethy M, Jules-Elyse'e, et al Clonidine and analgesic duration after popliteal fossa nerve block: Randomized, double-blind, placebo controlled study. *Anesth Analg* 2008; 106: 1916-20.
13. Yoshitomi T, Kohjitani A, Maeda S, Higuchi H, Shimada M, Miyawaki T. Dexmedetomidine enhances the local anesthetic action of lidocaine via an alpha-2A adrenoceptor 2008; 107: 96-101.
14. Esmaoglu A, Yegenoglu F, Akin A, Turk C. Dexmedetomidine added to levobupivacaine prolongs axillary brachial plexus block. *Anesth Analg* 2010; 111:1548-51

How to cite this article: Bhandari S, Singh J, Verma V, Singh G, Manju, Chitra. A Comparative Study On Post-Operative Analgesia With Clonidine And Dexmedetomidine As An Adjuvant To Ropivacaine Under Ultrasound Guided Fascia Iliaca Compartment Block In Patients Scheduled For Hip And Femur Surgeries: A Randomized, Double Blind, Control Trial. *Ann. Int. Med. Den. Res.* 2018; 4(5):AN08-AN12.

Source of Support: Nil, **Conflict of Interest:** None declared