

Anesthetic Management of Sacrococcygeal Teratoma- A Case Report

Anish Singh¹, Mamta Jain¹, Mrinmoy Majumdar², Bharat Bhushan Jain³

¹Assistant Professor, Department of Anaesthesiology and Critical Care, Pt. BDS PGIMS, Rohtak, Haryana, India.

²Senior Consultant, Department of Anaesthesia, Max Hospital Patparganj, Delhi, India.

³Senior Consultant, Department of Anaesthesia, Max Hospital Vaishali, Ghaziabad, U.P., India.

Received: June 2018

Accepted: June 2018

Copyright:© the author(s), publisher. It is an open-access article distributed under the terms of the Creative Commons Attribution Non-Commercial License, which permits unrestricted non-commercial use, distribution, and reproduction in any medium, provided the original work is properly cited.

ABSTRACT

Sacrococcygeal teratoma is a tumour of new born which is derived from germ cells. It is mostly found in female child and has good prognosis if complete resection of the tumour along with coccyx done early. Recurrence or turning into malignant form is uncommon if careful resection is done early. Here we describe anesthetic management of a suspected case of sacrococcygeal teratoma in a new born baby.

Keywords: Sacrococcygeal teratoma, coccyx, presacral mass.

INTRODUCTION

Sacrococcygeal teratoma is a commonest neoplasm of new born which arises from germ cells and has multiple tissue types.^[1,2] It may cause preterm labour and difficulty during delivery. It can be benign or malignant on the basis of mature and immature tissue types.^[3] It is usually benign but the risk of turning malignant increases with age, so early surgical resection is mandatory. The time of presentation is also important because the tumours appearing in late infancy have more malignant potential while those presenting in early fetal period have more complications during delivery.^[3] The risks during anesthesia and surgery are mainly due to large size and highly vascular nature of the tumour.

CASE REPORT

A new born baby admitted to NICU in our institution at nine hours of life after full term caesarean delivery for evaluation of right gluteal mass. The caesarean was done in view of gestational diabetes mellitus, pregnancy induced hypertension, previous caesarean and scar tenderness. The baby cried immediately after birth with a birth weight of 2.5 kg and normal apgar score. At the time of admission heart rate was 136 per minute, respiratory rate 62 per minute, capillary refill time <2 seconds, SPO2-97% on room

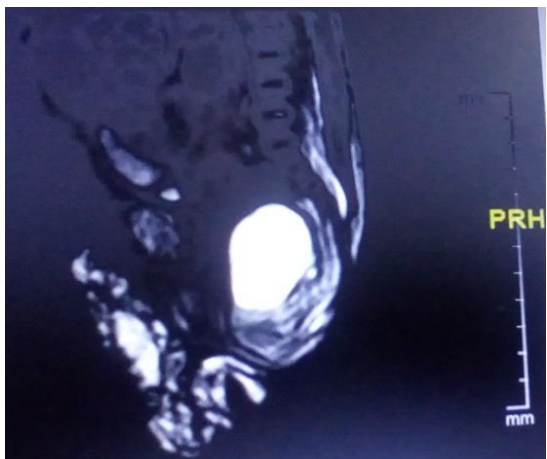
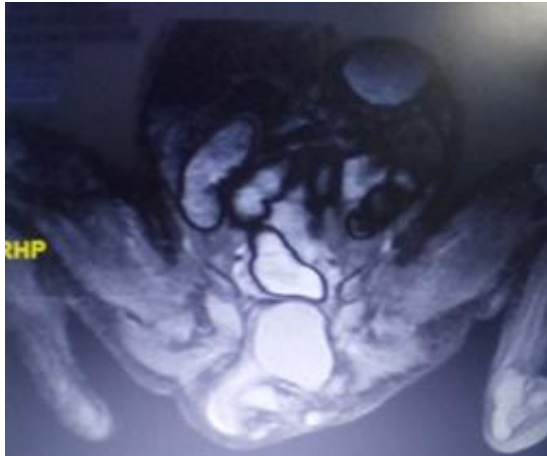
air. The abdomen was soft and bowel sound present. The right gluteal mass was soft, around 3-4 cm, non-tender and not attached to overlying skin. The MRI pelvis showed large ovoid mass in presacral region extending into bilateral ischiorectal fossa and subcutaneous right gluteal region. The mass showed solid cystic areas with few calcific foci/teeth like structure. The mass measured 5.2 x 2.8 x 5.1cm and was displacing the anal canal, rectum, uterus and bladder anteriorly. The findings were suggestive of large complex presacral mass most likely sacrococcygeal teratoma type II/III.

After pre-anesthesia checkup and arranging adequate blood products the patient was planned for excision of sacrococcygeal teratoma. The haemogram showed Haemoglobin of 13 gm% and normal platelets count. Urine, liver function tests and kidney function tests were normal. Two intravenous cannulae were secured in view of high vascularity of tumour and anticipated blood loss. Right radial artery cannulation and central venous line insertion via femoral vein was done for invasive monitoring. Injection glycopyrrolate 0.01 mg given and intravenous fluid (isolyte P) 10ml/hr continued. Efforts were done to keep the patient warm like wrapping the baby in cotton, keeping the theatre warm and blowing warm air. The patient was anesthetized with sevoflurane with oxygen, fentanyl 5 mcg, atracurium 1.25 mg and intubated with 3 mm internal diameter uncuffed endotracheal tube. Anesthesia was maintained with oxygen, air, sevoflurane (1-2%), atracurium and fentanyl. The complete surgical resection of tumour and coccyx was done without spillage of tumour in prone position with minimal blood loss. The patient was

Name & Address of Corresponding Author

Dr Mamta Jain
MBBS MD IDCCM
Assistant Professor
Department Of Anaesthesiology And Critical Care
Pt BDS, PGIMS Rohtak, Haryana, India.

haemodynamically stable during intraoperative period and extubation was planned after good respiratory effort with glycopyrrolate and neostigmine at the end of surgery. The patient was shifted back to NICU for further management. After few days the histopathological examination of the tumour confirmed sacrococcygeal teratoma with mature type of cells. The patient was discharged from hospital in satisfactory condition.



DISCUSSION

Sacrococcygeal teratoma is a commonest neoplasm in new born with incidence of 1:35000 to 1:40000 live births with female preponderance.^[1,2,5] It arises from remnant of the primitive streak and has different tissue types because all three germ cell layers are involved. Most of the tumours diagnosed antenatally by USG between 22-34 weeks.^[5,6] The outcome depends upon size and type of tumour, low birth weight, poor appgar score after birth, appearance of tumour before 20 weeks of gestation and preterm delivery of baby.^[4] Large tumours have both solid and cystic component with high vascularity. Classification according to their location: type - I—Predominantly external with minimal presacral component. Type-II—Present externally but with significant intrapelvic extension. Type-III—

Apparent externally but predominantly a pelvic mass extending into the abdomen. Type-IV—Presacral with no external presentation.

Histological classification: Grade 0—Tumour contains only mature tissue. Grade 1—Tumour contains rare foci of immature tissues. Grade 2—Tumour contains moderate quantities of immature tissues. Grade 3—Tumour contains large quantities of immature tissue with or without malignant yolk sac elements.^[3]

Antenatal diagnosis is important because during delivery highly vascular tumour may rupture and patient may go into hemorrhagic shock.^[6] Fetus with Small and non-vascular tumours may be delivered vaginally. Fluid and water retention may occur in fetus and mother which causes hydrops in fetus and pre-eclampsia like features in mother. It may become malignant during infancy and probability of turning malignant increases with age so earliest complete surgical resection along with excision of coccyx should be done. In the perioperative period, patient should be adequately warmed to prevent hypothermia because of large body surface area and high vascularity of the tumour.^[4] The blood and blood products should be in hand before start of surgery. Large bore intravenous cannula and Invasive monitoring is mandatory for large and highly vascular tumour. The most common operation table deaths are due to sudden high blood loss and electrolyte imbalance.^[7] Distal motor deficit and neurological sequel like bladder dysfunction may occur after resection.^[8] Extubation and ICU admission should be planned according to the blood loss, duration of surgery, body temperature and hemodynamic condition of patient. Some patients may need postoperative chemotherapy for residual tumor. Follow up of the patients is required because recurrence rate is high particularly in cases without excision of coccyx. The other reasons for recurrence are residual tumor or spillage of tumour during resection.^[3] Alpha feto protein level is measured in the post-operative period and persistently high level may indicate recurrence or residual tumour.

CONCLUSION

Resection of large and highly vascular tumour in a new born is a challenge to anesthetists but adequate preparation and anticipation of perioperative risks reduces the morbidity and mortality in the patient.

REFERENCES

1. Choudhury S, Kaur M, Pandey M, Jain A. Anaesthetic management of sacrococcygeal teratoma in infants. *Indian J Anaesth* 2016;60:374-5
2. Girwalkar-Bagle A, Thatte WS, Gulia P. Sacrococcygeal teratoma: A case report and review of literature. *Anaesth Pain & Intensive Care* 2014;18(4):449-51

3. Tuladhar R, Patole SK, Whitehall JS Sacrococcygeal teratoma in the perinatal period. Postgraduate Medical Journal 2000;76:754-759.
4. Abraham E, Parry T, Ghafoor A. Complications with massive sacrococcygeal tumor resection on a premature neonate. J Anesth 2010;24:951-4.
5. Hassan, Hussam S, Elbatarny, Akram M. Sacrococcygeal teratoma: management and outcomes. Ann Pediatric Surg. 2014;10(3):72-7.
6. Krishnan S, Solanki R, Sethi SK. Sacrococcygeal teratoma- role of ultrasound in antenatal diagnosis and management. J Hong Kong Coll Radiol 2004;7:35-9.
7. Kim JW, Gwak M, Park JY, Kim HJ, Lee YM. Cardiac arrest during excision of a huge sacrococcygeal teratoma - A report of two cases. Korean J Anesthesiol. 2012 Jul; 63(1): 80-4.
8. Smith B, Passaro E, Clatworthy HW. The vascular anatomy of sacrococcygeal teratomas: Its significance in surgical management. Surgery 1960;49:534-9.

How to cite this article: Singh A, Jain M, Majumdar M, Jain BB. Anesthetic Management of Sacrococcygeal Teratoma-A Case Report. Ann. Int. Med. Den. Res. 2018; 4(4):AN01-AN03.

Source of Support: Nil, **Conflict of Interest:** None declared