

A Clinico- Pathological Study of Enteric Perforation with Special Reference to Prognostic Factors

Garima¹, Abhay^{2*}

¹Associate Professor, Department of Pathology, General Surgery, Shri Venkateshwara University, Rajabpur, NH-24, Venkateshwara Nagar, Gajraula, Uttar Pradesh, India.

Email: gbhatnagar1@rediffmail.com

Orcid ID: 0000-0002-4550-7767

²Associate Professor, General Surgery, Shri Venkateshwara University, Rajabpur, NH-24, Venkateshwara Nagar, Gajraula, Uttar Pradesh, India.

Email: abhay_bhatnagar1@rediffmail.com

Orcid ID: 0000-0003-4807-1548

*Corresponding author

Received: 11 August 2021

Revised: 28 October 2021

Accepted: 09 October 2021

Published: 22 October 2021

Abstract

Background: Aim: To assess clinical and pathological cases of typhoid enteric perforation with special reference to prognostic factors. **Methods:** Sixty- four patients with typhoid perforation of either gender were selected in the study. All patients underwent emergency exploratory laparotomy via a midline incision under general anaesthesia. Operative findings were recorded, and the amount of pus and fecal material drained were estimated. **Results:** Out of 64 patients, mortality was noted in 6 cases. Timing of surgery <24 hours had 1 and >24 hours had 5 mortalities. Duration of symptoms within 2 weeks had 2 and after 2 weeks had 4, no. of perforation single had 3 and multiple had 3. Amount of peritoneal Fluid <1000 ml had 1 and >1000 ml had 5 mortalities. Ileal resection had 2 and simple closure had 4 mortalities. A significant difference was observed ($P < 0.05$). **Conclusions:** Prognostic factors in cases of typhoid enteric ileal perforation were Timing of surgery >24 hours, duration of symptoms after 2 weeks, multiple number of perforation and amount of peritoneal Fluid >1000 ml.

Keywords:- Enteric fever, ileal perforation, exploratory laparotomy, Salmonella.

INTRODUCTION

The incidence of perforation is on the rise due to the increased prevalence of gastritis in the population and also due to the increased use of NSAIDs which abolish the gastro-protective effects of prostaglandins.^[1] The incidence of Ileal perforation is also increasing mainly due to increased number of people presenting to the emergency department and also due to better diagnosis and improved reporting of cases. Ileal perforations account for about 20 % of all cases of hollow viscus perforation.^[2]

Among the causes for Ileal perforations, typhoid Ileal perforations are the commonest

followed by tubercular and other etiologies.^[3] Typhoid fever is a systemic infection caused by the bacterium *Salmonella enterica* subspecies *enterica* serotype Typhi (*S. Typhi*). The disease causes much morbidity and mortality in developing countries and is characterized by prolonged fever, bacterial growth in cells of the reticuloendothelial system, and significant inflammation of the lymphoid organs of the small intestine.^[4]

Typhoid fever is endemic in poor and underdeveloped countries of the world causing fatal complications such as intestinal perforation, which leads to generalized peritonitis, septicemia, fluid and electrolyte

derangements.^[5] Typhoid intestinal perforation is a common cause of surgical acute abdomen in our environment. The incidence of perforation varies considerably, with the West African subregion having one of the highest perforation rates in the world (15-33%), and the reasons for this remain speculative.^[6] Patients with typhoid perforation usually require surgical intervention and vigorous antimicrobial therapy. In cases of perforation, laboratory confirmation of a clinical diagnosis of typhoid fever is difficult, because blood and bone marrow cultures often show no growth.^[7] Considering this, we selected clinical and pathological study of enteric perforation with special reference to prognostic factors.

MATERIAL AND METHODS

A total of sixty- four patients with typhoid perforation of either gender were selected in the study. All had given written consent for the participation. Higher authorities were consulted for the approval of the study. The diagnosis of typhoid ileal perforation was made through clinical examination, Widal test, radiological findings of pneumoperitoneum, intraoperative findings of ileal perforation and an acutely inflamed and edematous terminal ileum.

All patients underwent emergency exploratory laparotomy via a midline incision under general anaesthesia. Preoperative investigations such as packed cell volume, urea and electrolytes, and chest and abdominal radiographs were performed. Operative findings were recorded, and the amount of pus and fecal material drained were estimated. The edge of the ileal perforation was excised, and

double-layer closure was done with chromic catgut 2/0 and silk 2/0. Post- operative outcomes were recorded. Results of the present study after recording all relevant data were subjected for statistical inferences using chi-square test. The level of significance was significant if p value is below 0.05 and highly significant if it is less than 0.01.

RESULTS

There were 40 males and 24 females. Common symptoms were fever in 64, cough in 35, abdominal pain in 51, diarrhea in 26, constipation in 12, vomiting in 35, headache in 40 and dizziness in 28. Signs were hepatomegaly in 32, splenomegaly in 26, cholecystitis in 27, coated tongue in 43, chest rales in 38 and jaundice in 51. A significant difference was observed ($P < 0.05$) [Table 1, Figure 1].

Out of 64 patients, mortality was noted in 6 cases. Timing of surgery <24 hours had 1 and >24 hours had 5 mortalities. Duration of symptoms within 2 weeks had 2 and after 2 weeks had 4, no. of perforation single had 3 and multiple had 3. Amount of peritoneal Fluid <1000 ml had 1 and >1000 ml had 5 mortalities. Ileal resection had 2 and simple closure had 4 mortalities. A significant difference was observed ($P < 0.05$) [Table 2, Figure 2].

Edge of perforation was rolled in 60 and punched in 4. Appearance of tissue was erythematous in 64, fragile in 62 and inflamed in 60. Liver condition was normal in 2 and congested in 5 cases. A significant difference was observed ($P < 0.05$) [Table 3].

Table 1: Patient characteristics.

Characteristics	Variables	Number	P value
Gender	Male	40	<0.05
	Female	24	
Symptoms	Fever	64	<0.05
	Cough	35	
	Abdominal pain	51	
	Diarrhea	26	
	Constipation	12	
	Vomiting	35	
	Headache	40	
	Dizziness	28	
Signs	Hepatomegaly	32	>0.05
	Splenomegaly	26	
	Cholecystitis	27	
	Coated tongue	43	
	Chest rales	38	
	Jaundice	51	

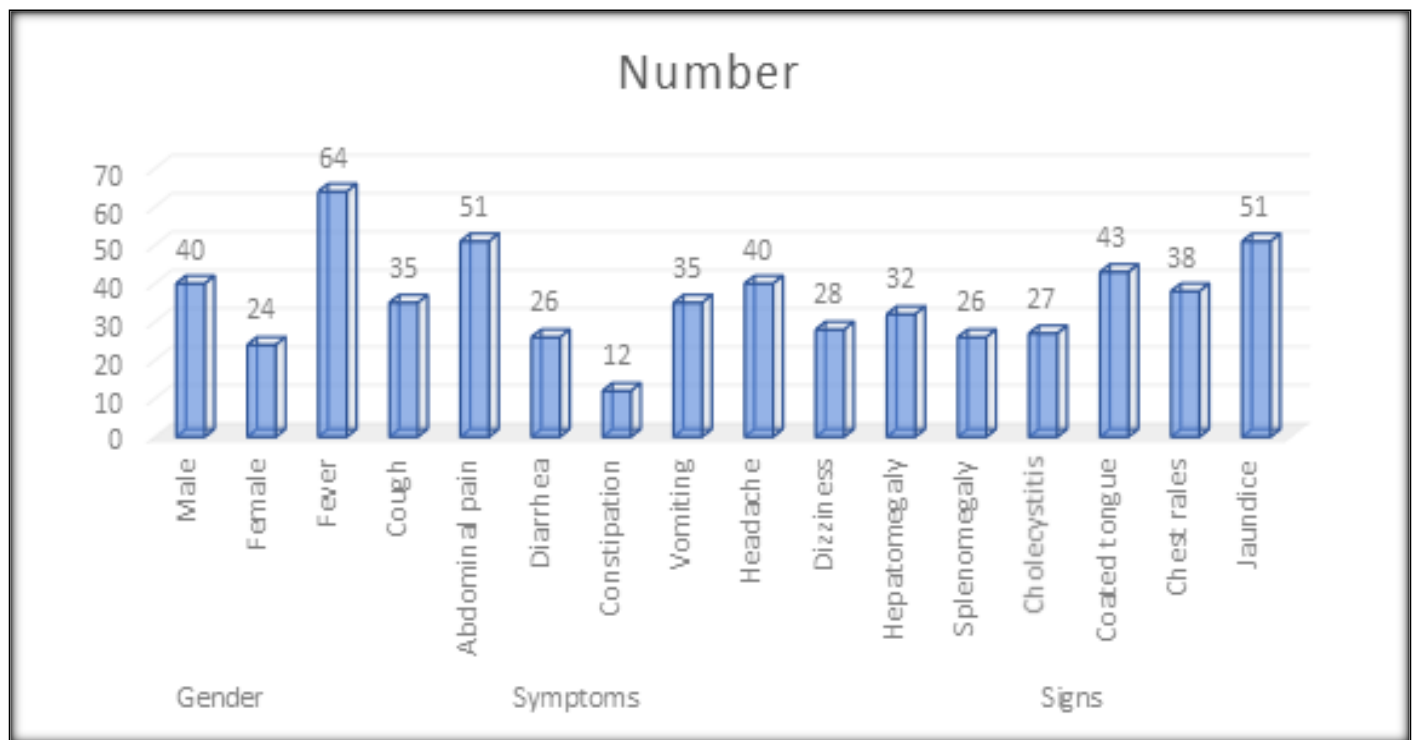


Figure 1:

Table 2: Variables associated with prognosis.

Parameters	Variables	Number of mortality	P value
Timing of surgery	<24 hours	1	<0.05
	>24 hours	5	
Duration of symptoms	Within 2 weeks	2	<0.05
	After 2 weeks	4	
No. of perforation	Single	3	>0.05
	Multiple	3	
Amount of Peritoneal Fluid	<1000 ml	1	<0.05
	>1000 ml	5	
Type of operation	Ileal resection	2	<0.05
	Simple closure	4	

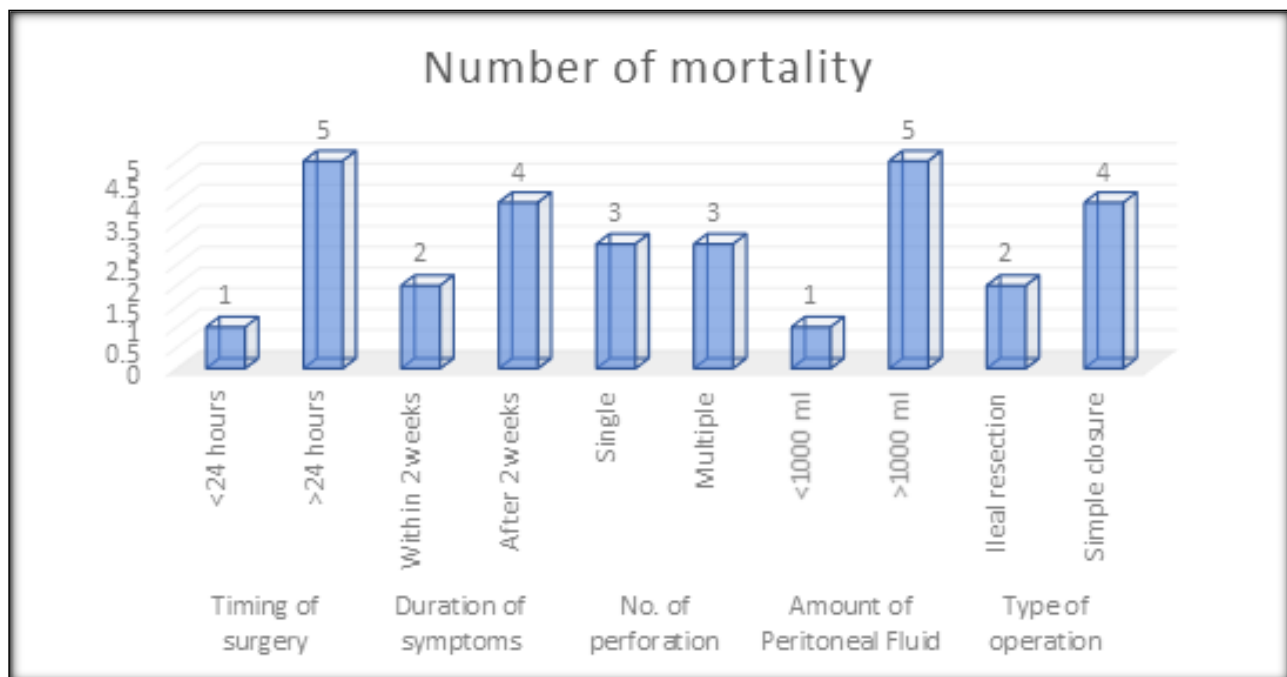


Figure 2:

Table 3: Pathological findings in patients.

Parameters	Variables	Number	P value
Edge of perforation	Rolled	60	<0.05
	Punched	4	
Appearance of tissue	Normal	0	>0.05
	Erythematous	64	
	Fragile	62	
	Inflamed	60	
Liver condition	Normal	2	<0.05
	Congested	5	

DISCUSSION

The present study was selected to assess clinical and pathological study of enteric perforation with special reference to prognostic factors. We enrolled 64 patients. Males were 40 and females were 24. Typhoid fever also known as enteric fever, a severe febrile infectious disease caused by *Salmonella typhi* and *salmonella para typhi* occurs in areas where poor socioeconomic levels and unsanitary environment.^[8,9] The majority of cases in endemic countries are due to *S. typhi*, while infection by *S. paratyphi* is more common among travellers. After ingesting contaminated food or water, during the first week of infection multiplication of bacteria occurs in the reticuloendothelial system during an incubation period of 1-14 days.^[10] During the enteric phase of typhoid fever, distinctive lesions develop restricted to the solitary lymphoid follicles or lymphoid aggregates of the mucosa, especially in the ileum. The leucocyte response is lympho-plasmacytic in type and is typically accompanied by cells of the mononuclear phagocyte system, which usually have swollen eosinophilia cytoplasm often containing ingested nuclear debris and red cells (typhoid histiocytes).^[11]

In our study, common symptoms were fever in 64, cough in 35, abdominal pain in 51, diarrhea in 26, constipation in 12, vomiting in 35, headache in 40 and dizziness in 28. Signs were hepatomegaly in 32, splenomegaly in 26, cholecystitis in 27, coated tongue in 43, chest rales in 38 and jaundice in 51. Steven et al,^[12] determined the prognostic factors in typhoid perforation in 53 consecutive patients with typhoid perforation managed surgically. There were 26 (49.1%) males and 27 (50.9%) females,

with age range of 2-55 years and a mean \pm SD of 12.2 ± 10.2 years. The morbidity was 49.1% and the most common post-operative complications included wound infection, wound dehiscence, burst abdomen, residual intra-abdominal abscesses and enterocutaneous fistula. Mortality was 15.1% and was significantly affected by multiple perforations, severe peritoneal contamination and burst abdomen. The mean duration of hospital stay for survivors was 16.1 days with a range of 8-57 days.

Our study showed that mortality was noted in 6 cases. Timing of surgery <24 hours had 1 and >24 hours had 5 mortalities. Duration of symptoms within 2 weeks had 2 and after 2 weeks had 4, no. of perforation single had 3 and multiple had 3. Amount of peritoneal Fluid <1000 ml had 1 and >1000 ml had 5 mortalities. Ileal resection had 2 and simple closure had 4 mortalities. Chanh et al,^[13] in their study, 67% were male, with a median age of 23 years and a median duration of illness of 10 days. *Salmonella enterica* subspecies *enterica* serotype Typhi (*S. Typhi*) was isolated from 11 (41%) of 27 patients; of 27 patients, only 4 (15%) had positive cultures from gut biopsies. *S. Typhi* DNA was detected by polymerase chain reaction for all perforation biopsy samples. Detailed histological examination of the gastrointestinal mucosa at the site of perforation in all cases showed a combination of discrete acute and chronic inflammation. Acute inflammation at the serosal surface indicated additional tissue damage after perforation. Immunohistochemical results showed that the predominant infiltrating cell types at the site of perforation were CD68+ leukocytes

(macrophages) or CD3+ leukocytes (T lymphocytes).

Our study demonstrated that edge of perforation was rolled in 60 and punched in 4. Appearance of tissue was erythematous in 64, fragile in 62 and inflamed in 60. Liver condition was normal in 2 and congested in 5 cases. The pathogenesis of intestinal perforation in patients with typhoid fever is poorly understood with respect to the host and bacterial factors involved. It is generally believed that perforation occurs in the Peyer patches of the distal ileum.^[14]

Poornima et al,^[15] included a total of 64 patients with Ileal perforation of which 52

were males and 12 were females accounting for 81.25 percent and 18.75 percent respectively. The causes for perforation were enteric fever (82.81%), nonspecific inflammation (9.38%), and tuberculosis (7.81%). Simple closure of the perforation (74.58%) and the remaining primary resection and anastomosis were the mainstay of the surgical management.

CONCLUSIONS

Prognostic factors in cases of typhoid enteric ileal perforation were Timing of surgery >24 hours, duration of symptoms after 2 weeks, multiple number of perforation and amount of peritoneal Fluid >1000 ml.

REFERENCES

1. Mock CN, Amaral J, Visser LE. Improvement in survival from typhoid ileal perforation. Results of 221 operative cases. *Ann Surg.* 1992;215(3):244-9. doi: 10.1097/0000658-199203000-00008.
2. Vaidya R, Habermann TM, Donohue JH, Ristow KM, Maurer MJ, Macon WR, et al. Bowel perforation in intestinal lymphoma: incidence and clinical features. *Ann Oncol.* 2013;24(9):2439-43. doi: 10.1093/annonc/mdt188.
3. Hatzaras I, Palesty JA, Abir F, Sullivan P, Kozol RA, Dudrick SJ, et al. Small-bowel tumors: epidemiologic and clinical characteristics of 1260 cases from the connecticut tumor registry. *Arch Surg.* 2007;142(3):229-35. doi: 10.1001/archsurg.142.3.229.
4. Buettner M, Lochner M. Development and Function of Secondary and Tertiary Lymphoid Organs in the Small Intestine and the Colon. *Front Immunol.* 2016;7:342. doi:10.3389/fimmu.2016.00342
5. Rehaman SA, Ramachandra CS, Jackaya RP. Primary Gastro Intestinal Lymphoma Presenting as Perforation Peritonitis. *J Clin Diagn Res.* 2016;10(3):PD22-4. doi: 10.7860/JCDR/2016/15462.7483.
6. Abdullah MS, Rassam RE, Almarzooq TJ. A study of 82 patients of non-traumatic terminal Ileal perforation in al-kindy teaching hospital. *J Fac Med Baghdad.* 2011;53(2):148.
7. Khalid S, Burhanulhuq, Bhatti AA. Non-traumatic spontaneous ileal perforation: experience with 125 cases. *J Ayub Med Coll Abbottabad.* 2014;26(4):526-9.
8. Nuhu A, Dahwa S, Hamza A. Operative management of typhoid ileal perforation in children. *Afr J Paediatr Surg.* 2010;7(1):9-13. doi: 10.4103/0189-6725.59351.
9. Mogasale V, Desai SN, Mogasale VV, Park JK, Ochiai RL, Wierzba TF. Case fatality rate and length of hospital stay among patients with typhoid intestinal perforation in developing countries: a systematic literature review. *PLoS One.* 2014;9(4):e93784. doi: 10.1371/journal.pone.0093784.
10. Hosoglu S, Aldemir M, Akalin S, Geyik MF, Tacyildiz IH, Loeb M. Risk factors for enteric perforation in patients with typhoid Fever. *Am J Epidemiol.* 2004;160(1):46-50. doi: 10.1093/aje/kwh172.
11. Mukhopadhyay A, Dey R, Bhattacharya U. Abdominal tuberculosis with an acute abdomen: our clinical experience. *J Clin Diagn Res.* 2014;8(7):NC07-NC9. doi:10.7860/JCDR/2014/8654.4574
12. Edino ST, Yakubu AA, Mohammed AZ, Abubakar IS. Prognostic factors in typhoid ileal perforation: a



- prospective study of 53 cases. *J Natl Med Assoc.* 2007;99(9):1042-5.
13. Nguyen QC, Everest P, Tran TK, House D, Murch S, Parry C, Connerton P, Phan VB, To SD, Mastroeni P, White NJ, Tran TH, Vo VH, Dougan G, Farrar JJ, Wain J. A clinical, microbiological, and pathological study of intestinal perforation associated with typhoid fever. *Clin Infect Dis.* 2004;39(1):61-7. doi: 10.1086/421555.
14. Kouame J, Kouadio L, Turquin HT. Typhoid ileal perforation: surgical experience of 64 cases. *Acta Chir Belg.* 2004;104(4):445-7.
15. Poornima R, Venkatesh KL, Goutham MV, Nirmala, Hassan N. Clinicopathological study of Ileal perforation: study in tertiary center. *Int Surg J* 2017;4:543-9. <https://dx.doi.org/10.18203/2349-2902.isj20164796>

Source of Support: Nil, Conflict of Interest: None declared