

Hollow Viscus Injury Following Blunt Abdominal Trauma: A Retrospective Study.

Bhuban Mohan Das¹, Sibabrata Kar², Tapas Ranjan Behera³

¹Associate Professor, Department of Surgery, Sri Ramachandra Bhanj (S.C.B) Medical College, Cuttack, Odisha, India.

²Assistant Professor, Department of Surgery, Sri Ramachandra Bhanj (S.C.B) Medical College, Cuttack, Odisha, India.

³Assistant Professor, Department of Community Medicine, Sri Ramachandra Bhanj (S.C.B) Medical College, Cuttack, Odisha, India.

Received: November 2017

Accepted: November 2017

Copyright: © the author(s), publisher. It is an open-access article distributed under the terms of the Creative Commons Attribution Non-Commercial License, which permits unrestricted non-commercial use, distribution, and reproduction in any medium, provided the original work is properly cited.

ABSTRACT

Background: Gastrointestinal and mesenteric injuries are the third most common type of injury from blunt trauma abdomen and are associated with high rates of morbidity and mortality. Objectives: To determine the clinico-demographic profile, localization of injury, diagnostic and management methods and the outcome in cases of hollow viscus injury (HVI) following blunt trauma abdomen which were admitted to our unit. **Methods:** Records of patients who were admitted emergently with gastrointestinal injuries and blunt abdominal trauma between July 2014 and July 2016 were reviewed retrospectively. **Results:** The study group comprised 65 patients with mean age of 33.3 ± 16.2 years and a male predominance (89.2%). The commonest cause of injury was road traffic accident in 44 (67.7%) cases. Ileum was the most common site of injury detected in 31 (41.3%) followed by jejunum in 26 (34.7%) cases. Treatment comprised primary closure of perforation in 48 (64%) cases, segmental resection and anastomosis in 22 (29.3%), and stoma in 5 (6.7%) cases. Three out of 5 cases of anastomotic leak occurred in patients who were operated at 8-24 hours or beyond. Associated injury to intra-abdominal solid viscera and other sites were present in 30.7%. The mean duration of hospitalization was longer in patients with associated injuries as compared to those with isolated HVI (12.2 ± 4.6 days versus 9.3 ± 0.8 days). **Conclusion:** Early diagnosis followed by prompt surgical intervention and careful monitoring for associated injuries is the key to favourable outcome in blunt HVI.

Keywords: Blunt abdominal trauma; colon injury; gastrointestinal injury; small bowel injury.

INTRODUCTION

The incidence of hollow viscus injury (HVI) following blunt abdominal trauma is on the rise due to increasing rates of road traffic accidents and is associated with high rates of morbidity and mortality.^[1] Moreover, HVI may be associated with injury to other intra-abdominal viscera and poses a diagnostic as well as therapeutic dilemma. Physical examination alone has inadequacies in determining the need for laparotomy^[2]; additional meticulous imaging techniques are required to aid in diagnosis. The main challenge is to timely detect lesions that require prompt surgical repair as diagnostic delay has been associated with poor outcome.^[3] Since the incidence of blunt HVI is low and there is limited published data from India, we share our experience from a tertiary care centre in Eastern India. In the present study we retrospectively review cases of HVI following blunt trauma

abdomen which were admitted and managed in our unit and determine the clinico-demographic profile, localization of injury, diagnostic and management methods and the outcome. We further compare our experience with previous studies reported in the literature.

MATERIALS AND METHODS

Records of all patients who were admitted emergently for blunt abdominal trauma under our unit between July 2014 and July 2016 were reviewed. Patients with gastrointestinal injuries due to blunt abdominal trauma were enrolled in the study. Only those patients who had been subjected to one or more of the following procedures (abdominal ultrasound, abdominal computed tomography scan, diagnostic peritoneal lavage, or exploratory laparotomy) were included. A retrospective analysis was done in terms of clinico-demographic profile, injury mechanism and localization, associated injuries, diagnostic and repair techniques, time from admission to operation, complications, duration of hospital stay and mortality. Ethical Committee approval was obtained. Patient informed consent was not required in view of the retrospective study

Name & Address of Corresponding Author

Dr. Sibabrata Kar
Assistant Professor, Department of Surgery, Shri Ramachandra Bhanj (S.C.B) Medical College, Cuttack-753007, Odisha, India.

design; however, patient confidentiality was maintained throughout.

Statistical analysis was performed using the Statistical Package for Social Sciences for Windows (SPSS, version 20.00). Continuous variables were expressed as mean ± standard deviation. A p-value of <0.05 was considered as statistically significant.

RESULTS

Total 65 patients were included in the study. There were 58 (89.2%) males and 7 (10.8%) females. The mean age of the patients was 33.3 ± 16.2 (ranging from 15 – 67) years. The commonest cause of injury was road traffic accident in 44 (67.7%) cases; in rest it was fall from height (26.1%), or physical assault (6.2%). Abdominal signs such as features of peritonitis and distension were present in 45 (69.2%) patients and haemodynamic instability was present in 4 (6.2%) patients. Erect abdominal radiography was done in 61 patients of whom 50 (81.9%) patients had free gas under the diaphragm. Abdominal ultrasonography (USG) was performed in 26 (40%) patients, of whom 14 (53.8%) had intra-abdominal pathological findings suggestive of haemoperitoneum or solid organ injury. Total 13 (20%) patients underwent computed tomography (CT) scan preoperatively. Among the most common CT findings, free peritoneal fluid was found in 6, bowel wall thickening in 3 and extraluminal intraperitoneal air in 2 patients.

A total of 75 HVIs occurred in 65 patients. Multiple gastrointestinal injuries were present in 6 (9.2%) patients while in rest single HVI was present. The localization of injuries to the gastrointestinal tract is summarized in Figure-I. Exploratory laparotomy was performed based on clinical and /or radiological findings. Treatment comprised primary closure of perforation in 48 (64%) cases, segmental resection and anastomosis in 22 (29.3%), and stoma in 5 (6.7%) cases. Associated injury to intra-abdominal solid viscera and other sites were present in 20 (30.7%) cases [Table 2].

Total 39 (60 %) patients were operated within 0-4 hours of admission, 11 (16.9%) within 4-8 hours, and 10 (15.4%) within 8-24 h. Five (7.7%) patients underwent laparotomy at >24 h following admission. Out of these 5, three had normal abdominal X-ray finding at the time of admission but subsequent CT done 18-24 hours later showed features of bowel injury. All 3 cases of wound infection, 1 case of burst abdomen, 3 out of 5 cases of anastomotic leak occurred in patients who were operated at 8-24 hours or beyond. The complications rate and mortality trend in HVI is shown in Table 3. The mean duration of hospitalization was longer in patients with associated injuries as compared to those with isolated hollow viscus injury (12.2±4.6 days versus 9.3±0.8 days); however the difference was not statistically significant (p>0.05).

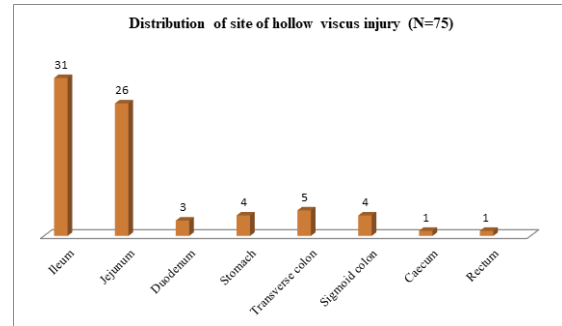


Figure 1: Frequency of gastrointestinal injuries encountered in 65 patients

Table 2: Localization and distribution of associated injuries.

Site of injury	Frequency (N=20)
Liver	04 (6.2%)
Spleen	03 (4.6%)
Pancreas	01 (1.5%)
Kidney	01 (1.5%)
Skeletal	06 (9.2%)
Head trauma	02 (3.1%)
Thorax	03 (4.6%)

Table 3: Complications and mortality trend in patients with hollow viscus injury after blunt abdominal trauma treated in our unit.

Complications	Frequency	Mortality
Anastomotic leak	05 (7.7%)	03
Solid organ injury	09 (13.8%)	01
Wound infection	03 (4.6%)	00
Burst abdomen	01 (1.5%)	00
Chest infection	02 (3.1%)	01

DISCUSSION & CONCLUSION

Gastrointestinal and mesenteric injuries occur in 3-5% cases of blunt abdominal trauma (BAT).^[1] They represent 16% of all lesions seen in BAT and are the third most common type of injury from blunt trauma to abdominal organs. Direct compression force may crush the gastrointestinal tract or cause a sudden increase in intra-luminal pressure resulting in bursting injuries; rapid deceleration may produce shearing force between fixed and mobile portions of the tract.^[4] Motor vehicle accidents were the most common cause of these injuries in various series which accords with our findings.^[5, 6] Seat belts form a closed loop within the abdomen and cause gastrointestinal injury.

Early diagnosis followed by prompt surgical intervention is the key to favourable outcome in hollow viscus injury (HVI). Presence of features of peritonitis or active bleeding calls for urgent laparotomy; however a high index of suspicion for HVI should be kept in all cases of BAT even in the absence of characteristic clinical findings.^[1] In our study 16 (24.6%) patients did not have positive findings on clinical examination initially at the time of admission but further evaluation led to a diagnosis of HVI. Ultrasonography and erect X-ray abdomen are the first diagnostic methods for evaluation of

blunt abdominal trauma. Erect abdominal radiography was able to detect HVI in 76.9% cases in our series which is comparable to the observation in Jha et al study.^[6] Focused abdominal sonography for trauma (FAST) is highly accurate for detecting intra-abdominal fluid; however it lacks sensitivity and specificity for identifying bowel and mesenteric trauma.^[7] Computed tomography (CT) scan is the investigation of choice in haemodynamically stable patients. CT has an accuracy of 86%, sensitivity of 94%, and a positive predictive value of 92% for detection of bowel injuries.^[8] Presence of free fluid is highly sensitive in diagnosing hollow viscus injury; the value of this finding increases in the absence of solid organ injury.^[9] In our series intra-peritoneal fluid on CT was present in 6 (46.1%) cases. Specific findings for hollow viscus injuries on abdominal CT are free intra-peritoneal air, retroperitoneal air, oral contrast extravasations, bowel wall defect, patchy bowel enhancement, and mesenteric abnormality.^[10] However, the sensitivity of these signs is low.^[11]

Small bowel is the most common site of injury to the intestine in BAT followed by injury to the colon and stomach in decreasing frequency.^[12, 13] The points of anatomic fixity in particular, proximal jejunum near the ligament of Treitz, distal ileum near the ileocecal valve, intestinal segments close to adhesions are susceptible to shearing forces. In our study too, ileum was the most common site of HVI detected in 41.3% followed by jejunum in 34.7% cases. Significant bowel injury consists of a complete tear of the bowel wall or an incomplete tear of the serosa that extends to but does not involve the mucosa. Nonsignificant bowel injuries include a hematoma or a tear limited to the serosa. The various procedures for repair of hollow viscus perforation are primary closure, segmental resection and anastomosis or temporary ileostomy/colostomy as the case may be. Hartman's procedure is done in extensive rectal injuries. Higher mortality rates have been observed in patients with gastric, duodenal or colonic injuries.^[14] In one third of the patients, bowel and mesenteric injury coexists with pancreatic or other solid organs.^[6] Therefore blunt trauma patients with HVI should be carefully monitored for associated injuries as higher morbidity and mortality rates are associated.^[13]

Anastomotic leak is the most dreaded postoperative complication as it can double the length of hospital stay and increase the mortality by threefold.^[15] It was the most common complication observed in the postoperative period and was associated with 3 out of 5 deaths in our series. The mortality rate in our study was 7.7%. Some authors reported a mortality rate of around 12% whereas others reported a rate as high as 25%.^[6, 14] Similar to our study, other series reported considerably higher duration of hospitalization in patients with intestinal trauma who sustained additional intra-abdominal visceral injuries.^[5]

In the Nastase et al study^[14], 81% patients were operated within 6 hours whereas 7% were diagnosed and operated on at >24 hours. Another study reported detection and laparotomy within 8 hours in 76% cases whereas 11% were detected with HVI at >24 hours.^[7] Their findings accord with our study. Delay to laparotomy following blunt small bowel injury results in significantly higher mortality rates, from 2% within the first 8 h, to 30% if the delay is >24 h.^[3] Contradictory to this, some studies reported that a delay to surgery of >24 hours following injury was associated with an increase in bowel-related complications but not mortality.^[7, 16]

Lawson et al in their review described bowel injury as the most common missed injury in BAT.^[17] Reliability of clinical examination may be reduced in the presence of altered mental status, intoxicated state or distracting injuries. If treatment of HVI is based on clinical assessment alone, it can have a high negative laparotomy rate of 40%.^[12] Imaging modalities specifically CT scan, when performed soon after the injury, may fail to demonstrate them. Conservative management of blunt abdominal trauma can add to the delay in diagnosis of HVI. Prognosis in BAT is significantly influenced by timely diagnosis of cases which require emergency surgery.^[18] Therefore radiological evaluation besides serial physical examination should be the protocol of tertiary survey in all patients of BAT and the decision for laparotomy should be judiciously based on the mechanism of injury, and clinical as well as radiological findings together. Our study was marked by the limitation of small sample size. Larger multi-centric trials from India in future might further define the demographic profile, diagnostic and management techniques, the associated morbidity as well as risk factors for poor outcome in blunt HVI.

Disclosure

The authors declare no conflict of interests.

REFERENCES

1. Bege T, Brunet C, Berdah SV. Hollow viscus injury due to blunt trauma: A review. *J Visc Surg* 2016; 153(4): 61-8.
2. Hoff WS, Holevar M, Nagy K K, Patterson L, Young J S, Arrillaga A, et al. Practice Management Guidelines for the Evaluation of Blunt Abdominal Trauma: The EAST Practice Management Guidelines Work Group. *Journal of Trauma-Injury Infection & Critical Care* 2002; 53(3): 602-615.
3. Fakhry SM, Brownstein M, Watts DD, Baker CC, Oller D. Relatively short diagnostic delays (<8 hours) produce morbidity and mortality in blunt small bowel injury: An analysis of time to operative intervention in 198 patients from a multicenter experience. *J Trauma* 2000; 48:408-14.
4. Hughes TM, Elton C. The pathophysiology and management of bowel and mesenteric injuries due to blunt trauma. *Injury* 2002; 33(4):295-302.
5. Gonullu D, Ilgun S, Gedik M L, Demiray O, Oner Z, Er M, et al. Gastrointestinal Injuries in Blunt Abdominal Traumas. *Chirurgia* 2015; 110(4):346-350.

6. Jha NK, Yadav SK, Sharma R, Sinha DK, Kumar S, Kerketta MD, et al. Characteristics of Hollow Viscus Injury following Blunt Abdominal Trauma; a Single Centre Experience from Eastern India. *Bull Emerg Trauma* 2014; 2(4):156-160.
7. Alsayali MM, Atkin C, Winnett J, Rahim R, Niggemeyer LE, Kossmann T. Management of blunt bowel and mesenteric injuries: Experience at the Alfred hospital. *Eur J Trauma Emerg Surg* 2009; 35(5):482-8.
8. Killeen KL, Shanmuganathan K, Poletti PA, Cooper C, Mirvis SE. Helical computed tomography of bowel and mesenteric injuries. *J Trauma* 2001; 51(1):26-36.
9. Brody JM, Leighton DB, Murphy BL, et al. CT of blunt trauma bowel and mesenteric injury: typical findings and pitfalls in diagnosis. *RadioGraphics* 2000; 20:1525-1537.
10. Bhagvan S, Turai M, Holden A, Ng A, Civil I. Predicting hollow viscus injury in blunt abdominal trauma with computed tomography. *World J Surg* 2013; 37(1):123-26.
11. Brofman N, Atri M, Hanson JM, Grinblat L, Chughtai T, Brennenman F. Evaluation of bowel and mesenteric blunt trauma with multidetector CT. *Radiographics* 2006; 26(4):1119-31.
12. Iaselli F, Mazzei MA, Firetto C, D'Elia D, Squitieri NC, Biondetti PR et al. Bowel and mesenteric injuries from blunt abdominal trauma: a review. *Radiol med* 2015; DOI 10.1007/s11547-014-0487-8.
13. Watts DD, Fakhry SM. EAST Multi-Institutional Hollow Viscus Injury Research Group. Incidence of hollow viscus injury in blunt trauma: an analysis from 275,557 trauma admissions from the East multi-institutional trial. *J Trauma* 2003; 54(2):289-94.
14. Nastase IL, Beuran M. Blunt Abdominal Trauma: Severity Factors in Hollow Viscus Injuries. *Therapeutics, Pharmacology and Clinical Toxicology* 2011; 15(1):31-34.
15. Chen C. The Art of Bowel Anastomosis. *Scandinavian J Surg* 2012; 101:238-40.
16. Fang JF, Chen RJ, Lin BC, Hsu YB, Kao JL, Kao YC, et al. Small bowel perforation: is urgent surgery necessary? *J Trauma* 1999; 47(3):515-20.
17. Lawson C, Daley BJ, Ormsby CD, Enderson B. Missed injuries in the era of the trauma scan. *J Trauma* 2011; 70(2):452-6; discussion 456-8.
18. Malinoski DJ, Patel MS, Yakar DO, Green D, Qureshi F, Inaba K, et al. A Diagnostic Delay of 5 Hours Increases the Risk of Death After Blunt Hollow Viscus Injury. *Journal of Trauma-Injury Infection and Critical Care* 2010; 69(1):84-87.

How to cite this article: Das BM, Kar S, Behera TR. Hollow Viscus Injury Following Blunt Abdominal Trauma: A Retrospective Study. *Ann. Int. Med. Den. Res.* 2018; 4(1): SG28-SG31.

Source of Support: Nil, **Conflict of Interest:** None declared