

# Efficacy of Nanosilver with Collagen Matrix Vs Povidone Iodine in Healing of Lower Limb Ulcers.

Amit Katlana<sup>1</sup>, Ashish Agrawal<sup>1</sup>, Iqbal Khan<sup>2</sup>, Etta Praneeth,<sup>2</sup> K S Narwariya<sup>2</sup>

<sup>1</sup>Professor, Department of General Surgery, Index Medical College Hospital & Research Centre, Indore.

<sup>2</sup>Post Graduate Student, Department of General Surgery, Index Medical College Hospital & Research Centre, Indore.

Received: April 2017

Accepted: April 2017

**Copyright:** © the author(s), publisher. It is an open-access article distributed under the terms of the Creative Commons Attribution Non-Commercial License, which permits unrestricted non-commercial use, distribution, and reproduction in any medium, provided the original work is properly cited.

## ABSTRACT

**Background:** Wounds expose a patient to serious hazards like wound infection, tissue destruction, disfiguring and disabling scars. Use of nanosilver with collagen matrix in infected wounds, ulcers, diabetic wounds, burns reduced morbidity and hospital stay with its early wound healing effect. To evaluate the effect of nanosilver with collagen matrix Vs povidone iodine on similar types of wounds. **Methods:** This prospective study included one hundred patients with different types of wounds who attended Department of Surgery, index medical college & hospital, indore from January 2015 to January 2017. The patients were divided into two groups. Group A where topical management and dressing was done using nanotrix and group B where topical management and dressing was done using povidone iodine. **Results:** A standard grading in terms of percentage decrease in wound size, peri wound oedema/ erythema, pus discharge and percentage increase in granulation, fibrin and epithelisation was noted in various types of wounds in both groups. Nanotrix treated wounds showed significant reduction in inflammation and earlier healing than those treated with povidone iodine. **Conclusion:** Nanotrix application was found to be safe having no pain and allergic manifestation.

**Keywords:** Nanosilver, Povidone Iodine, Ulcer,

## INTRODUCTION

Wounds and their management are fundamental in the practice of surgery. In trauma, road side accidents, stabs, war injuries, bites and burns, wound is frequently the primary pathology. The inflammatory phase of healing starts at the moment of injury. Initial vasoconstriction is followed by increased blood flow to the wound edges along with chemotaxis of polymorphs, macrophages, platelets and release of chemical mediators like cytokines and growth factors that activate and stimulate the healing process. Inflammatory phase (vasoconstriction followed by vasodilatation, platelet aggregation & phagocytosis) is followed by proliferative phase & granulation. Fibroblasts lay bed of collagen, fills defect and produces new capillaries. Contraction of wound edges pull together to reduce defect.<sup>[1]</sup> Epithelization occurs across moist surface, cell travelling in all directions from point of origin. In remodelling phase new collagen forms which increases tensile strength of wounds. Various growth factors stimulate cellular proliferation, chemotaxis,

angiogenesis and enzyme production. Important growth factors include Platelet derived growth factor PDGF, fibroblast growth factors FGF, epidermal growth factor EGF, transforming growth factor TGF, insulin like growth factors IGF. The platelets are considered critical to initiation of healing as they are rich source of PDGF, PGF and EGF. Various factors affecting wound healing are host related factors or endogenous factors. Healing is rapid in children and young persons and delayed in debilitated or malnourished having anemia and hypoproteinaemia.<sup>[2]</sup> Obesity also has an adverse effect on wound healing. Uncontrolled diabetes results in reduced inflammation, angiogenesis and collagen synthesis. Jaundice and uraemia adversely affect wound healing. Wasting caused by chronic illness leads to poor wound healing. Malignancy is natural to cause poor wound healing. Patients on cytotoxic agents, chronic steroids intake and those having autoimmune deficiencies are more prone to wound infection and delayed healing.<sup>[3,4]</sup>

Exogenous factors include duration of surgery, glove punctures, emergency procedures, air borne contamination, wound contamination, tissue perfusion, microbes causing infection. Tissue level factors or local factors like poor blood supply, inadequate oxygenation undue tension in suturing, tissue necrosis and local infection have profoundly deleterious effect on all aspects of wound healing. Although a multimodel therapy is the basis of wound

### Name & Address of Corresponding Author

Dr. Amit Katlana  
Professor,  
Department of General Surgery,  
Index Medical College Hospital & Research Centre,  
Indore.

healing, an ideal antiseptic is one that is rapidly lethal to all forms of bacteria and their spores, capable of bactericidal activity for a prolonged period, has no injurious effect on wound healing tissues. There has always been a search for an ideal antiseptic that is rapidly lethal to all forms of bacteria and their spores, capable of bactericidal property for a prolonged period with no ill effect on host tissues. Nanosilver with collagen matrix may represent an alternative to the currently available antiseptics for the disinfection of skin and wounds.<sup>[7]</sup> Nanosilver with collagen matrix have shown to be both safe and efficient as a wound care product that moistens, lubricates, debrides and reduces the microbial load of various types of lesions electrochemically processed aqueous solutions manufactured from pure solutions which is rich in reactive oxygen species with neutral pH and longer half life (>12 months).

#### Mechanism of Action

Collagen is the most abundant protein. It can influence the cell physiology and morphology, create a good matrix for endothelial cells in vitro, induce platelet aggregation, promote blood clotting and consequently accelerate the healing of skin wounds.<sup>[5-7]</sup>

Silver nano particles helps to control bacterial activity and have high levels of bacteriocidal and bacteriostatic activities.<sup>[8,9]</sup> Ability to treat a broad spectrum bacteria flora, high biocompatibility and low toxicity in viv.<sup>[10]</sup> in particular, the shape and concentration of Silver nano particles in solutions are important factors in ensuring the effective contacts of the particles with the bacterial membrane and in determining the amount of silver nano particles for effectively inhibiting the target bacteria.<sup>[11-13]</sup> Some literature reported the application of Silver nano particle for treating the wounds of mice and this particles showed excellent tensile properties and resulted in improved alignment of fibers for skin repairs.<sup>[16]</sup>

### **MATERIALS AND METHODS**

The present study was carried out in department of surgery, imchrc, indore in year january 2015 – January.<sup>[17]</sup> the study proposal was studied and approved by department review committee. total of 100 patients with lower limb ulcers were studied. the patients underwent dressings after obtaining informed consent the pts were randomized to be divided in 2 different groups as follows

Group A consists of 50 patients which were treated by meticulous surgical debridement followed by dressing with nanosilver with collagen matrix and skin grafting if needed.

Group B consists of 50 patients with ulcers which were treated by meticulous surgical debridement followed by dressing with povidone iodine solution

Along with the dressing the patients received broad spectrum antibiotics according to the pus culture sensitivity results. daily dressing once or twice done

#### Inclusion Criteria

1. Age > 18 yrs
2. Traumatic ulcers
3. Diabetic ulcers
4. Acute / chronic ulcers

#### Exclusion Criteria

1. age < 18 YrS
2. Ischaemic ulcers
3. Venous ulcers
4. Malignant ulcers
5. Decubitus ulcers
6. Tropic ulcers
7. Osteomyelitis
8. Sinuses
9. Chronic renal failure
10. Autoimmune disorders
11. Cytotoxic drugs / corticosteroids
12. Immunosuppression

Clinical assessments of ulcers were performed at beginning of treatment and at each dressing change for each group

Assessments were done on day 1, 5, 9, 12, 21 and the observations were noted in the written proforma. Various tools were used to assess the efficacy of nanosilver with collagen matrix which included

1. wound size
2. Appearance of granulation tissue
3. Epithelisation
4. Organism isolated/growth on c/s
5. Procedures done (skin grafting/ debridement/ no procedure)
6. Duration of hospital stay

### **RESULTS**

Current study comprises of total 100 patients with lower limb ulcers admitted in the Department of General Surgery, IMCHRC, Indore. Patients were divided randomly in two groups A and B with each group containing 50 patients.

All patients were evaluated by brief history, local and systemic examination and necessary investigations.

Patients in Group A underwent dressing with Nanosilver with Collagen Matrix while in group B dressing was done with povidone iodine. Clinical assessments of ulcers were performed at beginning of treatment and at each dressing change for each group and recorded and analyzed under the following headings:

1. Age incidence.
2. Sex incidence.
3. Etiological types of ulcers.
4. Sites and distribution of ulcers.
5. Healing was assessed on the basis of following criteria:

- Decrease in ulcer surface area on day 1,5,9,12,21.
  - Appearance of granulation tissue on day 1,5,9,12,21.
  - Epithelisation on day 1,5,9,12,21.
6. Incidence of infection.
  7. Any adverse reaction.
  8. Final outcome.
  9. Duration of hospital stay.

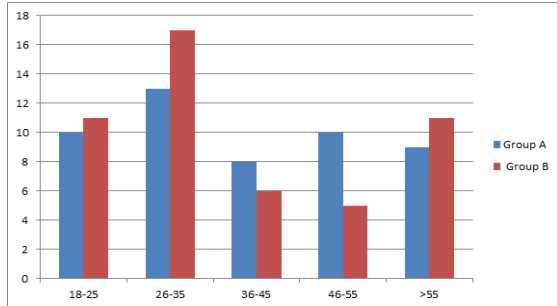


Figure 1: Distribution of Age Groups.

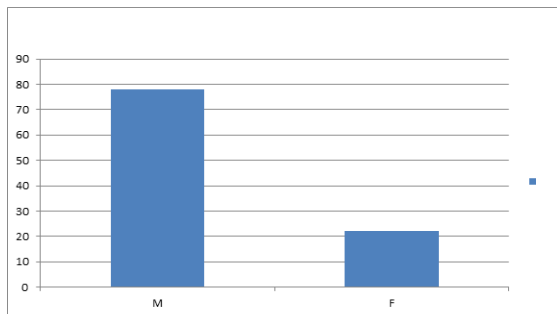


Figure 2: Sex Ratio in Study Groups

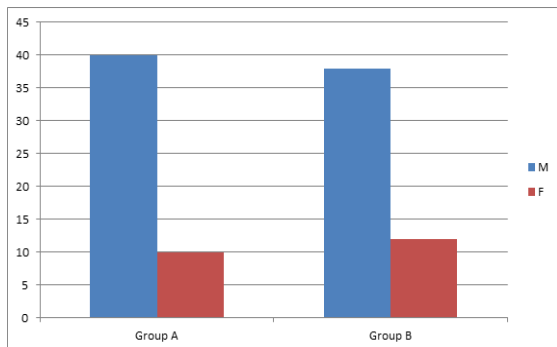


Figure 3: Distribution of Sex in Both Groups.

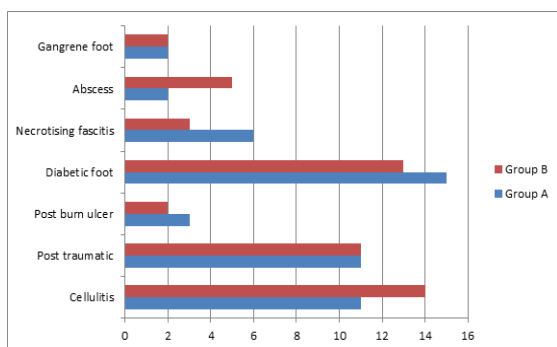


Figure 4: Etiology of Types of Wound in Patients of Both Groups.

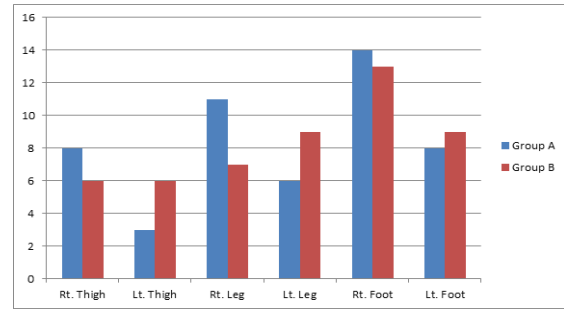


Figure 5: Site and Distribution of Wounds.

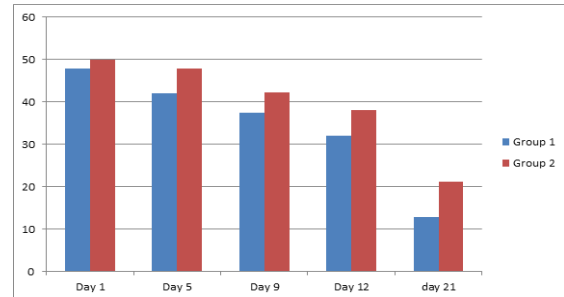


Figure 6: Wound size (in cm2) after day 1,5,9,12,21 of Dressing.

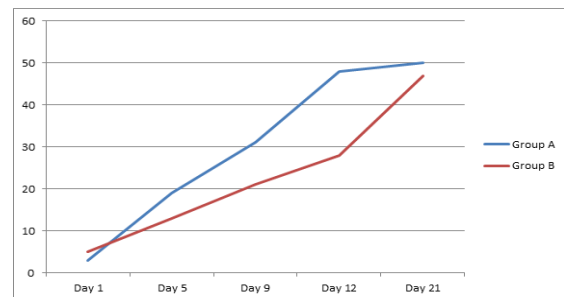


Figure 7: Rate of appearance of granulation tissue at day 1, 5, 9, 12, 21.

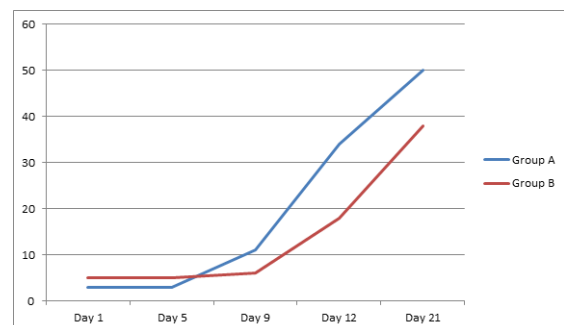


Figure 8: Rate of epithelisation in %.

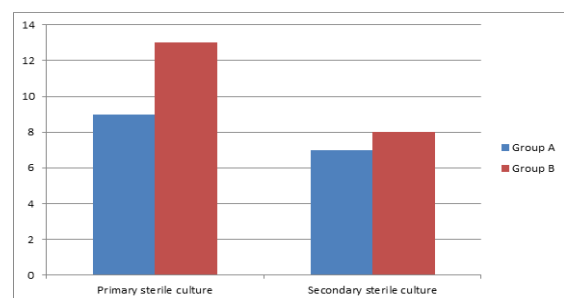


Figure 9: Incidence of infection in primary sterile cases.

## DISCUSSION

The management of wounds is fundamental in the practice of surgery. In this study, we compare the efficacy of Silver nanoparticles Vs Povidone iodine in healing of lower limb ulcers. The present study conducted in Index Medical College Hospital and Research Centre in Department of Surgery. The study was designed in two groups A and B each comprising 50 patients. Group A patients were treated with meticulous debridement and application of Silver nanoparticles. Group B patients were treated with meticulous debridement and application of conventional topical agent povidone iodine. Observation were recorded on the basis of age, sex, etiology of ulcers, wound healing in terms of wound surface area, granulation tissue, epithelisation, wound cultures, adverse reactions, surgical procedures done and duration of hospital stay. Observation data were analysed using various statistical tools like mean, range, paired t test. Maximum patients belong to age group 26-35 years with total 30 patients. Mean age of the Group A was  $39.18 \pm 14.38$ . Mean age for Group B was  $38.8 \pm 14.52$ . Male patients were more than female patients and sex ratio of 3.54:1 was obtained.

Most common etiology of ulcer was diabetic foot. Other etiologies were gangrene foot, post traumatic ulcer, cellulitis, post burn ulcers and abscess. Most common site of the ulcers was foot in 44 cases.

In Group A decrease in wound surface area was faster than Group B. At the time of presentation mean surface area for Group A was  $47.80 \pm 27.81$  cm<sup>2</sup> and Group B was  $49.96 \pm 26.82$  cm<sup>2</sup>. At day 5 mean wound surface area for group A was  $42.08 \pm 25.04$  cm<sup>2</sup> and Group B was  $47.84 \pm 26.19$  cm<sup>2</sup>. At day 9 mean wound surface area for Group A and Group B was  $37.48 \pm 23.44$  cm<sup>2</sup> and  $42.28 \pm 24.174$  cm<sup>2</sup>. At day 21 mean wound surface area for Group A and Group B was  $12.14 \pm 10.81$  cm<sup>2</sup> and  $21.20 \pm 13.84$  cm<sup>2</sup>.

All these results were compared by paired t test and found to be significant in favour of Silver nanoparticles. Appearance of granulation tissue and epithelisation was earlier in Group A as compared to Group B. At day 12 in Group A 96% patients developed granulation and in Group B 56% patients had granulation. At day 12 in Group A 68% patients had epithelisation and in Group B 36% patients had epithelisation.

Rate of secondary infection for Group A was 22.22% and Group B was 38.44%.

Most common bacteria isolate at initial cultures was Staphylococcus Aureus. Reduction in infection rate was more in Group A as compared to Group B. SSG was performed in 8 (16%) cases of Group A 13 (26%) cases of Group B.

Average duration of hospital stay for Group A was 19.84 days with SD of 16.041 while average hospital

stay time for Group B was 25.31 with  $\pm 6.129$ . No adverse reaction was seen in either group.

In the management of lower limb ulcer, a Silver nanoparticle debrides necrotic tissue, reduces microbial load, promotes granulation and decreases the healing time, without damaging the normal tissue or complications. Those patients who have small superficial ulcers or not fit for surgery, can be managed conservatively with Silver nanoparticles. So Silver nanoparticle is safe, more effective and efficacious as compared to povidone iodine for ulcer management.

However, new controlled trials must be conducted to fully establish the antimicrobial, anti-inflammatory, and positive effects in wound healing.

## CONCLUSION

The results of our study favours the effective role of Silver nanoparticle in wound healing, and we found it to give better efficacy as compared to conventional topical agent (Povidone Iodine). It promotes rapid healing without damaging the normal tissue. Silver nanoparticle is safe and effective in lower limb ulcers. No adverse events or complications were noted.

## REFERENCES

1. GUO S & DIPIETRO LA. Factors affecting wound healing. J dent res 2010 mar; 89(3):219-29
2. Laplante AF, Germain I, Auger FA & Moulin V. Mechanisms of wound reepithelisation hints from a tissue engineered reconstructed skin to long standing questions FASEB J 2001 NOV 15 (13): 2377-89
3. Galeano M, Altavilla D, Cucinotta D et al recombinant human erythropoietin stimulates angiogenesis and wound healing in the genetically diabetic mouse diabetes 2004 sep ; 53(9)
4. Block ER, Tolino MA, Lozano JS et al free edges in epithelial cell sheets stimulate epidermal growth factor receptor signaling. Mol Biol Cell 2010 Jul 21(13):2172-81
5. Wang XH, Li DP, Wang WJ, Feng QL, Cui FZ, Xu YX, Song XH, Van der Werf M: Crosslinked collagen/chitosan matrix for artificial livers. Biomaterials. 2003, 24: 3213-3220. 10.1016/S0142-9612(03)00170-4.
6. Nishikawa AK, Taira T, Yoshizato K: In vitro maturation of collagen fibrils modulates spreading, DNA synthesis, and collagenolysis of epidermal cells and fibroblasts. Exp Cell Res. 1987, 171: 164-177. 10.1016/0014-4827(87)90259-X.
7. Wang XH, Li DP, Wang WJ, Feng QL, Cui FZ, Xu YX, Song XH, Van der Werf M: Crosslinked collagen/chitosan matrix for artificial livers. Biomaterials. 2003, 24: 3213-3220. 10.1016/S0142-9612(03)00170-4.
8. Nehrer S, Breinan HA, Ramappa A, Young G, Shortkroff S, Louie LK, Sledge CB, Yannas IV, Spector M: Matrix collagen type and pore size influence behaviour of seeded canine chondrocytes. Biomaterials. 1997, 18: 769-776. 10.1016/S0142-9612(97)00001-X.
9. Matsuda K, Suzuki S, Isshiki N, Yoshioka K, Okada T, Ikada Y: Influence of glycosaminoglycans on the collagen sponge component of a bilayer artificial skin. Biomaterials. 1990, 11: 351-355. 10.1016/0142-9612(90)90113-5.
10. Srivastava S, Gorham SD, French DA, Shivas AA, Courtney JM: In vivo evaluation and comparison of collagen, acetylated collagen and collagen/glycosaminoglycan composite films and

- sponges as candidate biomaterials. *Biomaterials*. 1990, 11: 155-161. 10.1016/0142-9612(90)90148-J.
11. Perng CK, Wang YJ, Tsi CH, Ma H: In vivo angiogenesis effect of porous collagen scaffold with hyaluronic acid oligosaccharides. *J Surg Res*. 2011, 168: 9-15. 10.1016/j.jss.2009.09.05212
  12. Bakare RA, Bhan C, Raghavan D: Synthesis and characterization of collagen grafted Poly(hydroxybutyrate-valerate) (PHBV) scaffold for loading of bovine serum albumin capped silver (Ag/BSA) nanoparticles in the potential use of tissue engineering application. *Biomacromolecules*. 2014, 15: 423-435. 10.1021/bm401686v.
  13. Jithendra P, Rajam AM, Kalaivani T, Mandal AB, Rose C: Preparation and characterization of aloe vera blended collagen-chitosan composite scaffold for tissue engineering applications. *ACS Appl Mater Interfaces*. 2013, 5: 7291-7298. 10.1021/am401637c.
  14. Lok C, Ho C, Chen R, He Q, Yu W, Sun H, Tam PK, Chiu J, Che C: Proteomic analysis of the mode of antibacterial action of silver research articles. *J Proteome Res*. 2006, 5: 916-924. 10.1021/pr0504079.
  15. Shahverdi AR, Fakhimi A, Shahverdi HR, Minaian S: Synthesis and effect of silver nanoparticles on the antibacterial activity of different antibiotics against *Staphylococcus aureus* and *Escherichia coli*. *Nanomedicine*. 2007, 3: 168-171. 10.1016/j.nano.2007.02.001Panáček A, Kvítek L, Pucek R, Kolář M, Večeřová R, Pizúrová N, Sharma VK, Nevěčná TJ, Zbořil R: Silver colloid nanoparticles: synthesis, characterization, and their antibacterial activity. *J Phys Chem B*. 2006, 110: 16248-16253. 10.1021/jp063826h.Gnanadhas DP, Ben Thomas M, Thomas R, Raichur AM, Chakravorty D: Interaction of silver nanoparticles with serum proteins affects their antimicrobial activity in vivo. *Antimicrob Agents Chemother*. 2013, 57: 4945-4955. 10.1128/AAC.00152-13.
  16. Pal S, Tak YK, Song JM: Does the antibacterial activity of silver nanoparticles depend on the shape of the nanoparticle? A study of the Gram-negative bacterium *Escherichia coli*. *Appl Environ Microbiol*. 2007, 73: 1712-1720. 10.1128/AEM.02218-06.Morones JR, Elechiguerra JL, Camacho A, Holt K, Kouri JB, Ramírez JT, Yacaman MJ: The bactericidal effect of silver nanoparticles. *Nanotechnology*. 2005, 16: 2346-2353. 10.1088/0957-4484/16/10/059.
  17. Kwan KHL, Liu X, To MKT, Yeung KWK, Ho C, Wong KKY: Modulation of collagen alignment by silver nanoparticles results in better mechanical properties in wound healing. *Nanomedicine*. 2011, 7: 497-504. 10.1016/j.nano.2011.01.003.
  18. Alarcon EI, Udekwu K, Skog M, Pacioni NL, Stampelcoskie KG, González-Béjar M, Poliseti N, Wickham A, Richter-Dahlfors A, Griffith M, Scaiano JC: The biocompatibility and antibacterial properties of collagen-stabilized, photoche.

**How to cite this article:** Katlana A, Agrawal A, Khan I, Praneeth E, Narwariya KS. Efficacy of Nanosilver with Collagen Matrix Vs Povidone Iodine in Healing of Lower Limb Ulcers. *Ann. Int. Med. Den. Res*. 2018; 4(1): SG74-SG78.

**Source of Support:** Nil, **Conflict of Interest:** None declared