

# A Novel Comparative Study of Phlebectomy with Invagination Stripping of the GSV Done Under Tumescant and Spinal Anaesthesia: A Prospective Cohort from Tertiary Centre in South India.

Chandrasekaran Sukumaran<sup>1</sup>, Siddharth Matad<sup>2</sup>, Sasi M Parambil<sup>3</sup>

<sup>1</sup>Assistant Professor, Department of General Surgery, Calicut Medical College, Kerala, India.

<sup>2</sup>Senior Resident, Department Of General Surgery, Calicut Medical College, Kerala, India.

<sup>3</sup>Proffessor & HOD, Department Of General Surgery, Calicut Medical College, Kerala, India.

Received: November 2017

Accepted: November 2017

**Copyright:** © the author(s), publisher. It is an open-access article distributed under the terms of the Creative Commons Attribution Non-Commercial License, which permits unrestricted non-commercial use, distribution, and reproduction in any medium, provided the original work is properly cited.

## ABSTRACT

**Background:** Varicose veins are commonly encountered vascular disease with wide variety of surgical and minimally invasive /interventional modes of treatment .we put forth a novel economical and efficient technique of performing high ligation, long saphenous vein stripping and Muller's hook phlebectomy in tumescant local anaesthesia compared with spinal anaesthesia. **AIM & OBJECTIVE:** The purpose of the study was to compare a novel technique of performing phlebectomy and invagination stripping of the GSV using tumescant anaesthesia and spinal anaesthesia in terms of post operative pain, complications. **Methods:** A total of 200 patients (100 patients in each arm of spinal anaesthesia group, and tumescant anaesthesia group) diagnosed cases of varicose vein lower limb being operated with phlebectomy and invagination stripping of the GSV at Surgery Department of Government Medical College and Hospital, Kozhikode, Kerala were considered in this study. Consecutive sampling was done. **Results:** Of these patients, 120 (60%) were female and 40 were male (40%) with a mean age of  $35.4 \pm 8$  and  $47.4 \pm 14$  years, respectively No statistically significant difference with respect to the wound infection, local discomfort, postoperative recurrence rates of varicosity and patients satisfaction score was observed ( $P > 0.05$ ). **Conclusion:** Tumescant local anaesthesia is a novel, economical and efficient technique of performing high ligation, long saphenous vein stripping and Muller's hook phlebectomy when compared to doing under spinal anaesthesia with similar results.

**Keywords:** Varicose vein , GSV stripping, Tumescant anaesthesia.

## INTRODUCTION

Chronic venous disorders range from telangiectasia or spider veins to varicose veins, venous swellings, skin changes and venous ulcerations. Incompetence of superficial veins in the lower limb affects over 40% of the population and the main risk factors are: age, lifestyle, bodyweight and number of pregnancies.<sup>[1,2]</sup> The disease is typically manifested by telangiectases, varicose veins, oedema, eczema and ulcers.<sup>[3]</sup> Three anaesthetic techniques are commonly used in varicose vein surgery: spinal anaesthesia, femoral nerve block and local anaesthesia. Our study describes another novel method using tumescant anaesthesia. Tumescant anaesthesia is widely used in plastic surgery, has few contraindications. Thousands of patients are treated

every year for this pathology and it is important to examine the impact of anaesthetic techniques on the recovery process after ambulatory surgery because the choice of anaesthetic technique can affect postoperative morbidity.

## MATERIALS AND METHODS

### Study Group & Setting

A total of 200 patients (100 patients in each arm of spinal anaesthesia group, and tumescant anaesthesia group) diagnosed as varicose vein lower limb attending Surgery out Patient Department of Government Medical College and Hospital, Kozhikode, Kerala were considered in this study. Study was undertaken after the approval from the Ethics Committee. Consecutive sampling was done satisfying the inclusion exclusion criteria till the sample size was attained in each group.

### Study Period

March 2016 – September 2017

### Study Design

Prospective Cohort (comparative) Study

### Name & Address of Corresponding Author

Dr. Siddharth Matad  
Senior Resident,  
Department Of General Surgery,  
Calicut Medical College,  
Kerala, India

**Inclusion Criteria**

A total of 200 subjects, age >18years, with clinical and venous Doppler diagnosis of varicose vein with SFJ incompetence were enrolled after informed written consent.

**Exclusion Criteria**

Patients who are not willing for the study; Patients with clinically significant respiratory, cardiovascular, renal, hepatic diseases were excluded. Secondary varicose veins and recurrent varicose veins were not included in the study. peripheral arterial disease, lymph oedema, BMI exceeding 40 kg/m<sup>2</sup>, pregnancy, allergy to lidocaine, severe general illness, malignancy, previous deep vein thrombosis and coagulation disorder.

**Statistical Analysis**

Data was entered in Excel and the analysis was performed on SPSS software. Friedman test and Wilcoxon rank sum (Mann-Whitney) test were used to find out the differences between the two groups. A P value of <0.05 was accepted as significant.

**Method**

A total of 200 patient's diagnosed cases of varicose vein with SFJ incompetence were included in this study. Patients were assessed by the consultant surgeon. The patients were assessed preoperatively by duplex ultrasonography .Preoperatively basic laboratory tests (blood tests: ESR, blood count, INR, serum sodium and potassium, urea, and creatinine), ECG, chest X-ray and clinical examination were done. Patients were divided into 2 groups by consecutive sampling (100 patients in each arm of spinal anaesthesia group and tumescent anaesthesia group) .patients preoperatively received iv fluids ,single dose of 1st generation cephalosporin antibiotic and postoperative nausea and vomiting (PONV) prophylaxis .All patients underwent phlebectomy and invagination stripping of the GSV .spinal anaesthesia was given by anaesthetists . Tumescent anaesthesia was given by the operating surgeon. Tumescent lidocaine solution was prepared mixing 30 ml containing 600 mg of lignocaine and 0.5 mg epinephrine plus 10 mEq sodium bicarbonate in 10 mL added to 400 mL of 0.9% physiologic saline for a final lidocaine concentration of 0.75mg/ml. The saphenofemoral junction (SFJ) was exposed in the groin and side branches were ligated back to the femoral vein. Retrograde invagination stripping of the GSV was done, usually down to above the knee. Serial injections of Tumescent solution was injected into the tunnel of the perivenous area both from above and below GSV. After stripping, hook phlebectomies were done through tiny incisions, using tumescent solution to minimize haematoma formation. The wound in the groin was closed with vertical mattress sutures. Phlebectomy wounds were closed with simple skin sutures After completion of the procedure compression stockings were applied on the

intervened leg till the upper thigh. Patients received tablet paracetamol up to 1gm as an analgesic in the post operative period. Visual Analogue Pain Scale (VAS) was used for pain assessment and complete follow up of the patients was done till 6 wks. None of the patients in our study group were complicated by lignocaine toxicity or deep venous thrombosis. Follow-up examination and venous Doppler was performed one week and one month after the procedure.

**RESULTS****Table 1: Distribution of cases according to age**

	(N)
20-30	26
30-40	96
40-50	56
50-60	15
60-70	07

**Table 2: Distribution of cases according to SEX**

(SEX)	(N)
MALES	80
FEMALES	120

**Table 3: Distribution of cases according to laterality of leg involved**

Laterality	(N)
Right	54
Left	97
Bilateral	49

**Table 4: Distribution of cases according to duration of disease at presentation**

Duration Of Disease At Presentation	
<5 YEARS	55
5-10 YEARS	90
10-15 YEARS	42
>15 YEARS	13

**Table 5: Distribution of cases according to CEAP "C" CLASS at presentation**

Ceap "C" Class At Presentation	Both Sexes	Females	Males
C2	25	18	7
C3	45	30	15
C4	55	34	21
C5	62	35	27
C6	13	3	10

**Table 6: Surgical time and the duration of hospital stays, and patient's satisfaction scores in two groups (means ± SD)**

	Surgical time (min)	Duration of hospital stays (days)	Satisfaction score
Group 1	85(22) (range 45-139)	3.15 ± 0.76	4.15 ± 0.75
Group 2	90(25) (range 55-150)	4.25 ± 0.74	3.95 ± 0.84
Statistical value	1.415	t = 1.286	t = 1.316
P value	P > 0.05	P > 0.05	P > 0.05

A total of 200 patients (100 patients in each arm of spinal anaesthesia group, and tumescent anaesthesia group) diagnosed as varicose vein lower limb were selected for high ligation, long saphenous vein stripping and Muller's hook phlebectomy by Consecutive sampling. Of these patients, 120 (60%) were female and 40 were male (40%) with a mean age of  $35.4 \pm 8$  and  $47.4 \pm 14$  years, respectively [Table 1,2 & Figure 1,2]. All patients were symptomatic for their venous problems, with or without skin changes. The majority were in the C5 group of the CEAP classification (30 patients in Group 1 and 32 in Group 2), followed by C4 (27 patients in Group 1 and 28 in Group 2), C3 (23 patients in Group 1 and 22 in Group 2) and C2 (13 patients in Group 1 and 12 in Group 2) [Table 5]. There were no statistically significant differences with respect to patients stratification scores between the groups ( $P > 0.05$ ). The mean (s.d.) duration of treatment was 85(22) (range 45–139) min in the spinal anaesthesia group and 90(25) (range 55–150) min in the tumescent anaesthesia group ( $P > 0.05$ ). no significant difference with respect to the duration of hospital stays & patients satisfaction scores was observed in the group2 as compared to the group1 ( $P > 0.05$ ) [Table 6]. Pain measured on a visual analogue scale (VAS; 1, none; 10, worst possible) in the post operative period showed no significant differences. [Figure 4]. In our study we found no significant difference with respect to complications like Wound infection, Local hematoma, seroma and paraesthesias between the two groups ( $P > 0.05$ ) [Table 7].



Figure 2: Gender Distribution Among Subjects

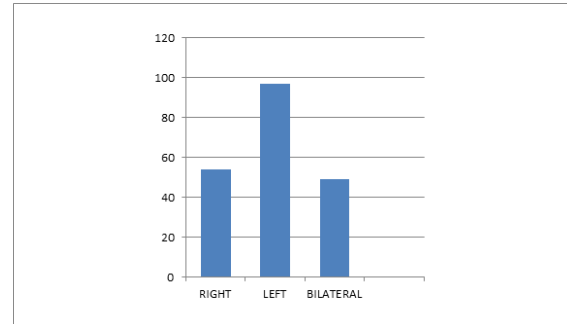


Figure 3: Distribution Among Subjects According To Laterality Of Leg Involved

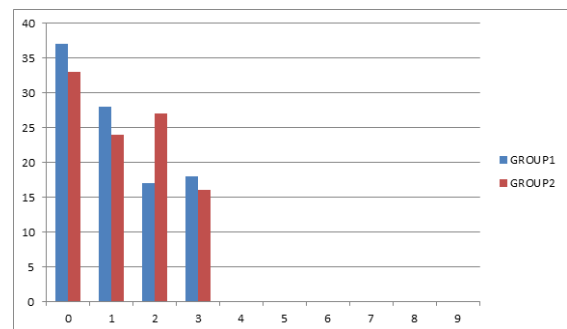


Figure 4: Pain Measured On A Visual Analogue Scale (Vas; 1, None; 10, Worst Possible) Between Two Groups

Table 7: Outcome of surgical treatment in two groups.

	Wound infectio n	Local hematom a	seroma	paraesthesia s
Group 1	4	3	7	2
Group 2	6	4	6	3
Statistica l value	$\chi^2 = 2.03$	$\chi^2 = 1.59$	$\chi^2 = 2.89$	$\chi^2 = 1.019$
P value	$P > 0.05$	$P > 0.05$	$P > 0.05$	$P > 0.05$

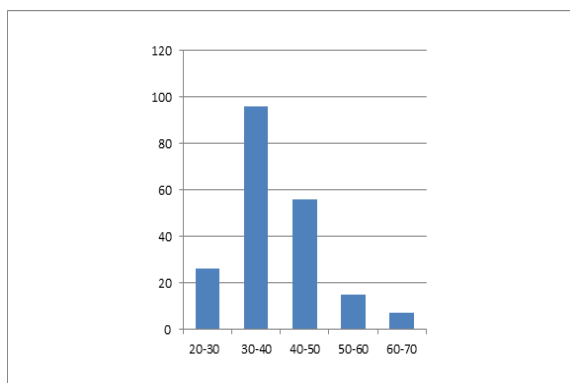


Figure 1: Age Distribution among Subjects

## DISCUSSION

Varicose vein surgery has advanced in the dawn of interventional radiology,<sup>[4]</sup> with the introduction of Minimally invasive techniques such as endovenous laser therapy, radiofrequency ablation, and ultrasound guided foam sclerotherapy are widely used in the treatment of lower extremity varicosities around the world,<sup>[5]</sup> but in spite of these advances the number of such procedures done in south India is very less. the affordability for these endovascular procedures by the patients attending our medical college is not possible hence at our institution we practice varicose vein surgery by high ligation /trendelenberg operation, great saphenous vein stripping with multiple incompetent perforator ligation under spinal anaesthesia .we came up with this novel technique to circumvent the problems of spinal anaesthesia like increased costs, limited operation theatre slots. Most patients in our study were diagnosed with grade C5 venous insufficiency followed by C4 which is similar to other study done

by John B. Chang et al.<sup>[6]</sup> Tumescence anaesthesia (large-volume, low-concentration lidocaine) is useful for this purpose improved haemostasis, reduced hematoma and hyper pigmentation, predissection of the vein from surrounding tissue by the solution pumped into the subcutaneous space, cooling effect during endovenous ablation of varicose veins.<sup>[7-9]</sup> these principles of tumescence anaesthesia was used to perform stripping in our study. In our study we found no significant difference with respect to the duration of hospital stay, patients satisfaction scores & Pain measured on a visual analogue scale between group1 and group2 (P>0.05). Wound infection, Local hematoma, seroma and paraesthesias were the observed complications in both the groups and they are not statistically significant. Spinal anaesthesia has been used for varicose vein stripping, but persistent weakness of the leg renders this technique unsuitable for day-case surgery.<sup>[10]</sup> Hence our technique is also feasible for day care surgery.

### CONCLUSION

Tumescence local anesthesia is a novel, economical and efficient technique of performing high ligation, long saphenous vein stripping and Muller's hook phlebectomy when compared to doing under spinal anaesthesia with similar results.

### REFERENCES

1. Chiesa R, Marone EM, Limoni C, Volonte` M, Petrini O. Chronic venous disorders: correlation between visible signs, symptoms, and presence of functional disease. *J Vasc Surg* 2007 Aug;46(2):322e30. (accessed 16/09/17)
2. Lee AJ, Evans CJ, Allan PL, Vaughan Ruckley C, Fowkes FGR. Lifestyle factors and the risk of varicose veins Edinburgh Vein Study. *J Clin Epidemiol* 2002 Aug;56(2):171e9. (accessed 16/09/17)
3. Eklof B, Rutherford RB, Bergan JJ, Carpentier PH, Gloviczki P, Kistner RL, et al. Revision of the CEAP classification for chronic venous disorders: consensus statement. *J Vasc Surg* 2004 Dec; 40(6):1248e52.(accessed 16/09/17)
4. Hardman RL, Rochon PJ. Role of interventional radiologists in the management of lower extremity venous insufficiency. *In Seminars in interventional radiology* 2013 Dec (Vol. 30, No. 04, pp. 388-393). Thieme Medical Publishers. (accessed 16/09/17)
5. Van den Bos R, Arends L, Kockaert M, Neumann M, Nijsten T. Endovenous therapies of lower extremity varicosities: a meta-analysis. *Journal of Vascular Surgery*. 2009 Jan 31;49(1):230-9. (accessed 16/09/17)
6. Chang JB, Stein TA. Management of varicose veins from chronic venous insufficiency. *International Journal of Angiology*. 2002 Dec;11(04):234-7. (accessed 16/09/17)
7. Weiss R, Ramelet AA. Varicose veins treated with ambulatory phlebectomy. *eMedicine*. 2007 Aug. (accessed 16/09/17)
8. Keel D, Goldman MP. Tumescence anaesthesia in ambulatory phlebectomy: addition of epinephrine. *Dermatologic surgery*. 1999 May 1;25(5):371-2. (accessed 16/09/17)
9. Munavalli GS, Weiss RA. Advances in techniques for endovenous ablation of truncal veins. *Skin Therapy Lett*. 2006 Apr;11(3):4-7. (accessed 16/09/17)
10. Nabatoff RA, Stark DC. Complete stripping of varicose veins with the patient on an ambulatory basis. *The American Journal of Surgery*. 1972 Nov 1;124(5):634-6. (accessed 16/09/17)

**How to cite this article:** Sukumaran C, Matad S, Parambil SM. A Novel Comparative Study of Phlebectomy with Invagination Stripping of the GSV Done Under Tumescence and Spinal Anaesthesia: A Prospective Cohort From Tertiary Centre In South India. *Ann. Int. Med. Den. Res.* 2018; 4(1):SG43-SG46.

**Source of Support:** Nil, **Conflict of Interest:** None declared