

# Evaluation of Palpable Breast Masses by Ultrasound and its Correlation with Tissue Diagnosis in a Tertiary Care Centre in Northern Kerala.

Krishnananda Holla<sup>1</sup>, Junise M<sup>2</sup>, Sandeep Sojan<sup>2</sup>, Harshavardhan N<sup>3</sup>

<sup>1</sup>Associate professor, Department of Radiodiagnosis, ACME, Pariyaram.

<sup>2</sup>Junior resident, Department of Radiodiagnosis, ACME, Pariyaram.

<sup>3</sup>Assistant Professor, Department of Radiodiagnosis, ACME, Pariyaram.

Received: November 2017

Accepted: November 2017

**Copyright:**© the author(s), publisher. It is an open-access article distributed under the terms of the Creative Commons Attribution Non-Commercial License, which permits unrestricted non-commercial use, distribution, and reproduction in any medium, provided the original work is properly cited.

## ABSTRACT

**Background:**According to numerous studies the positive predictive value for biopsy can be improved by proper complete diagnostic work up in which sonography is also included. Developments in imaging technique with high resolution ultrasonography has helped us to distinguish between benign and malignant masses. This study has been carried out for the ultrasonological characterization of palpable breast masses and to categorize them as benign and malignant and to correlate these benign and malignant breast masses with tissue diagnosis. **Methods:**Our study was a prospective analysis. The study included 150 patients with age range between 22–75 years (mean age, 40 years) and with a history of palpable breast masses. Data for our study was collected from the patients referred to Department of Radio diagnosis at Academy of medical sciences, Pariyaram, Kannur for the period of two years. A structured, pre-prepared case proforma (CP) was used to enter the clinical history, physical examination findings, investigations-sonography and histopathology findings. Initially sonography was performed with GE Voluson 730 expert scanner with 7.5-10 MHz linear array transducer and data was obtained of only solid masses. Then tissue diagnosis was obtained in all 150 cases. Later the tissue diagnosis results were correlated with sonological findings by statistical analysis. **Results:**The US features most predictive of a benign tissue diagnosis were oval or round shape, circumscribed margins, and width-to-AP dimension ratio greater than 1.4. The features most predictive of a malignant tissue diagnosis were spiculated or microlobulated margins, irregular shape, ill-defined margins, and width-to-AP dimension ratio of 1.4 or less. Some features like the effects of masses on posterior echo intensity were not reliable in differentiating between benign and malignant lesions. Some features like echogenicity showed excellent correlation with a benign or malignant tissue diagnosis were too infrequent to be generally applicable. **Conclusions:**In our study we performed the prospective analysis of the sonomammography findings in correlation with tissue diagnosis. The US features in our study most predictive of a benign tissue diagnosis were oval or round shape, circumscribed margins, presence of edge refraction, and width-to-AP dimension ratio greater than 1.4. The features most predictive of a malignant tissue diagnosis were spiculated or microlobulated margins, irregular shape, ill-defined margins, and width-to-AP dimension ratio of 1.4 or less. The results of our study were encouraging in that we were able to identify the most applicable US features for differentiating benign from malignant solid masses. These features have the potential to help decrease the number of biopsies performed for benign solid masses.

**Keywords:**Sonomammography; benign mass; malignant mass.

1

## INTRODUCTION

Breast cancer remains one of the leading causes of non preventable cancer death. Lump in the breast is a serious concern to women and fear to both patient and doctor. Breast cancer is one of the best-studied human tumors, yet remains poorly understood. Fortunately a disease process does not have to be understood to be treated successfully, but needs to be detected. The emphasis on early detection of cancer

and not to miss a malignant lesion in early stage of disease and the current medico-legal environment encourage an aggressive biopsy approach to breast problems. The large number of biopsies performed for benign breast abnormalities has long been recognized as a serious problem. Excessive biopsies for benign lesions have adverse effects on society and on the women who undergo them by increasing the costs of screening projects, causing morbidity, and adding to the barriers that keep women from using a potentially life saving procedure.<sup>[1-3]</sup> Attempts have been made to increase the positive predictive value for biopsy (biopsy yield of cancer) by performing a complete diagnostic work-up that often includes ultrasonography (US). For a palpable lesion, characterization of lesion is important in further management of the problem. Improvements

### Name & Address of Corresponding Author

Dr. Sandeep Sojan  
Junior resident,  
Department of Radiodiagnosis,  
ACME, Pariyaram.

in US equipment have prompted more recent studies with findings that describe reliable signs for differentiating benign from malignant masses. We conducted a prospective analysis of 50 consecutive cases in which patients presented palpable breast masses and underwent breast US followed by tissue diagnosis.

### **Aims and Objectives**

According to many studies the positive predictive value for biopsy can be increased by proper complete diagnostic work up in which sonography is also included. Improvements in imaging technique with high resolution ultrasonography, many studies have described the reliable signs to differentiate benign and malignant masses. However, there are very limited Indian studies to investigate the general applicability of US features to distinguish benign from malignant solid masses. Hence this study was carried out for,

1. Ultrasonological characterization of palpable solid breast masses and categorizing each mass as benign and malignant.
2. To correlate categorized benign and malignant breast masses with tissue diagnosis

### **Review of Literature**

1989 Edward.A.Sickles M.D. systematically evaluated different breast lesions with respect to their mammographic characteristics and provided a systematic and practical approach to the imaging evaluation of breast masses. He concluded that the ultimate decision for biopsy vs. mammographic follow up of a lesion depends on the probability of malignancy determined by combination of mammographic and physical findings as well as pertinent data from medical history.1983 Patricia Harper M.D. et al evaluated 1300 patients with solid breast lesions by ultrasound and concluded that by ultrasound it was possible to differentiate benign from malignant lesions with high degree of accuracy as specific image characteristics predominate in certain breast pathologies.1991 Lawrence.W.Bassett M.D. et al reviewed 1016 women under 35 years who underwent mammography during 8-year period. He concluded that ultrasound is more sensitive in evaluation of lesions. However a tailored mammographic examination would help to solve persistent localized breast symptoms. He also emphasized that a biopsy specimen of a dominant palpable solid mass should be obtained despite the fact that the patient is younger than 35 yrs if ultrasound and mammographic findings are equivocal.<sup>[4-6]</sup>

1995 A.T.Stavros et al prospectively evaluated 750 solid breast nodules and concluded that when combined with excellent sonographic technique, optimal machine and transducer characteristics and strict adherence to the criteria for a benign lesion which requires the absence of even a single malignant characteristic, can be used to accurately

classify some solid lesions as benign allowing imaging follow up rather than biopsy.1989 Jack.E.Meyer et al studied 24 medullary carcinomas by both mammography and sonography. These carcinomas mimicked benign mass on both mammography and sonography. In these lesions he showed image characteristics of benign lesion and so he concluded that a benign image finding should not deter from biopsy if clinical index of suspicion is high.1991 Novotny D.B.et al evaluated 25 cases of pregnancy related breast masses 3 months gestation to 3 months postpartum and lactating adenoma accounted for maximum numbers of cases. Galactocele was seen in 20% patients.<sup>[7-9]</sup>

1993 Nani.M.T et al studied mammary duct ectasia by ultrasound and concluded that radial ultrasound is an essential for evaluation of retro areolar masses, which showed rosary like dilatations and pseudo cystic ectasia the peak age group was between 50-60yrs.1995 Sweeney D.J. et al evaluated 14 cases of duct ectasia by mammography and concluded that lesion cannot be differentiated from malignancy in 40% of cases. He showed micro calcification in more than 50% of cases.1998 Kolb TM et al concluded screening US can depict small, early-stage, otherwise occult cancers similar in size and stage to mammographically identified nonpalpable cancers and smaller and lower in stage than palpable cancers in dense breasts.<sup>[10-12]</sup>

1999 Guita Rahbar et al evaluated and characterized different breast lesions based on mammography and sonography and showed that certain imaging features are very specific and showed that hyper echogenic lesion is almost a sure sign of benignity.1999 Harvey S.C. et al evaluated 853 breast lesions by large core needle biopsy and compared with imaging findings of 38 cases of fibrous nodule of breast.2001 Jamal A.A. evaluated 1084 benign breast lesions with respect to their age incidence and presentations of different lesions.2002 Sawhney et al evaluated 10 cases of galactocele by ultrasound. All the cases had well defined thin echogenic wall. He also studied other characteristics by ultrasound and mammography.<sup>[13-15]</sup>

2003 Baicheve.G et al evaluated breast cysts and concluded that the peak age was between 30-50 and 0.3% of cysts showed cancer within the system.2004 Georgian Smith et al evaluated 41 cases of hamartoma by both mammography, sonography and compared with histological findings.2004 Sakar A.A .et al studied 10 cases of tuberculous mastitis and in each study 305 of the lesions mimicked malignancy on both ultrasound and mammography.2005 Martha B et al concluded that in the absence of suggestive mammographic features, sonographically probably benign masses have an acceptably low likelihood of malignancy such that follow-up can be an acceptable alternative to biopsy.<sup>[16-19]</sup>

**Sonomammogram<sup>[20,21]</sup>**

Ultrasound reflects the acoustic characteristics of breast tissue and is well established as an ancillary technique for evaluating breast lesions. However, it is operator-dependent and requires optimal technique, and findings must be correlated with the mammogram whenever possible. Because it is a non-ionizing technique, ultrasound is particularly advantageous for evaluation of palpable masses in young, pregnant, or lactating women. It can differentiate cysts from solid masses seen on mammography or found on palpation. Because taut compression is not required for ultrasound, it can be useful in evaluating a painful, inflamed breast to determine if a focal, drainable abscess is the problem. Also, ultrasound can be helpful when no mammographic abnormality is seen in a clinically suspicious area of the breast. If results of mammography and ultrasound are both normal in a woman with a palpable, suspicious mass, a biopsy of the mass should always be done, regardless of the imaging results. A palpable mass not seen in dense parenchyma is suitable for ultrasound evaluation. However, ultrasound does not visualize all solid masses (or malignant tumors), nor can it consistently show micro calcifications.

Ultrasound is also helpful for determining whether lesions incompletely visualized on a mammogram or palpable masses that cannot be included on a mammogram are cystic or solid. The mammographic features of certain solid masses may suggest a benign lesion and allow the radiologist to assign it to a short-term follow-up category. On the other hand, if certain features are characteristic of malignancy, biopsy is recommended. Clinical studies evaluating possible future uses for breast ultrasound technology and research into three-dimensional breast ultrasound are under way. The utility of ultrasound in the detection of clinically and mammographically occult breast cancer is also being studied. Until the results of these clinical studies are available, ultrasound screening is not advocated for routine clinical use.

The primary use of ultrasound is to determine whether a solitary mass, detected by mammography, is cystic or solid. Because the risk of axillary nodal metastasis and the associated diminished survival doubles for tumors greater than one centimeter, solitary masses approaching this size should be investigated by ultrasound, aspiration or biopsy. If the lesion is sharply marginated, contains no internal echoes and has enhanced sound transmission, the diagnosis of a cyst can be made confidently and studies suggest that no further intervention is required. If a solid lesion is demonstrated by ultrasound, then the decision to pursue further evaluation should be made in conjunction with the clinical situation, because ultrasound cannot reliably differentiate benign from malignant solid lesions.

The primary role for breast ultrasound is the evaluation of lesions that are not clinically evident,

as a complement to mammography, and as a guide for needle procedures. The use of ultrasound in the management of palpable lesions is somewhat more controversial. The use of ultrasound for palpable lesions is cost-effective if it is coordinated with clinical decisions. As with any test, the decision to use ultrasound should be determined by the likelihood that its results would influence clinical management. If a palpable lesion is of sufficient concern to the patient or her physician that it will be aspirated or removed, regardless of the imaging analysis, then the use of ultrasound will produce an unjustified expense since the majority of these lesions will be cysts, and a cyst will be diagnosed and "treated" at the same time by clinically guided needle aspiration. If the demonstration of a cyst by ultrasound will result in no further intervention and aspiration will be avoided, its use is clinically and economically valuable as long as it does not cost more than a clinically guided aspiration. Many women prefer that a palpable mass be eliminated. The majority of such masses are cysts that are easily aspirated by the referring physician after mammography. Thus, diagnosis and treatment are accomplished in a single step. The performance of ultrasound only adds a superfluous study and unnecessary expense unless aspiration is not desired. If clinically guided aspiration fails to produce fluid or resolve the mass, ultrasound can be useful. Using this approach, only a small percentage of palpable masses that defy clinically guided aspiration will require ultrasound. Aspiration may fail due to the thickness of the surrounding fibrotic tissue or the presence of fluid that is too viscous for the gauge of the needle used. The demonstration of a cyst by ultrasound makes it possible to be somewhat more aggressive in aspiration; moreover, when ultrasound guides repeat aspiration, many such lesions can be resolved without surgery. As more and more women receive their breast evaluations from primary care physicians who have little experience with breast problems, the use of ultrasound to evaluate palpable abnormalities has increased. Ultrasound of a palpable abnormality is not advocated as a standard of care, but it may be helpful in assisting clinical management.

## MATERIALS & METHODS

### Type of study

Our study was prospective analysis type.

### Source of data

Data for the study was collected from the patients was referred to/ attended Department of Radio diagnosis at Academy of medical sciences, Pariyaram, Kannur with clinically detected palpable breast masses.

### Study period

The study was performed for the period of two years from July-2015 to July 2017 excluding the period of data analysis and write-up.

Method of collection of data: A structured, pre-prepared case proforma (CP) was used to enter the clinical history, physical examination findings, investigations-sonography and histopathology findings. Total number of subjects selected for the study was 150 patients of age range between 22–75 years (mean age, 40 years). Initially sonography was performed and data was obtained. Then tissue diagnosis was obtained in all 150 cases. Later the tissue diagnosis results were correlated with sonological findings by statistical analysis.

**Inclusion criteria**

Female patients with palpable solid breast masses based on sonological findings and within the age group of 22-75 years.

**Exclusion criteria**

Female patients with palpable cystic breast lesions based on sonological findings and outside the age group of 22-75 years.

Patients that did not undergo both Sonography and FNACTechnique of ultrasound

In our study all USG examinations were performed using a 7-10-MHz high frequency linear-array of GE- Voluson 730 expert model.

**Patients scanning technique**

Before performing the ultrasound scan a detailed history and clinical examination was performed. Patients were examined in the supine position. A thorough ultrasound examination was done in sagittal plane, transverse plane and radial scanning. The following findings were made:

1. Shape (oval, lobulated, round or irregular),
2. Margins (spiculated, circumscribed, ill- defined or microlobulated),
3. Width-to-anteroposterior (AP) dimension ratio,
4. Posterior echoes (unaffected, enhanced or decreased). Beam intensity posterior to lesion was noted and was described as posterior enhancement if the intensity of the beam was augmented behind lesion. And reported as shadowing when the intensity reduced.
5. Echogenicity (intensity of internal echoes) and reflectivity of the lesion were compared with fibroglandular tissue and was reported as hypoechoic if the lesion was less reflectivethan surrounding tissue, anechoic when clear and hyperechoic when echogenicity more than the surrounding tissue.
6. Echotexture (homogeneity of internal echoes),
7. Presence of calcifications,
8. Presence of pseudocapsule
9. Edge rarefaction

**Statistical Methods**<sup>[22,23]</sup>

Statistical Methods: Chi square test/Fisher Exact test has been used to find the significant association of

US features in differentiating Malignancy and Benign.

Statistical software: The Statistical software namely SPSS 15.0, Stata 8.0, MedCalc 9.0.1 and Systat 11.0 were used for the analysis of the data and Microsoft word and Excel have been used to generate graphs, tables etc.

**Table 1: Association of US Features with Malignant versus Benign Tissue diagnosis**

US features	Number of patients (n=50)	Tissue Diagnosis		P value
		Malignant	Benign	
<b>Shape</b>				
Round /Oval	66 (44.0)	3 (4.5)	63(95.5)	0.004**
Three or fewer lobulations	27(18.0)	6 (11.1)	21(77.7)	1.000
>3 lobulations	27(18.0)	9(33.3)	18(66.7)	0.668
Irregular	30(20.0)	18(60.0)	12(40.0)	0.007**
<b>Margins</b>				
Circumscribed	96(64.0)	6(6.3)	90 (93.8)	<0.001**
Microlobulated	9(6.0)	6(66.7)	3(33.3)	0.139
Ill defined	42(28.0)	21(50.0)	21(50.0)	0.023*
Spiculated	3(2.0)	3 (100.0)	0	0.240
Width of AP dimension ratio		12 (13.8) 24(38.1)	75(86.2) 39(61.9)	0.047* 0.047*
>1.4	87(38.0)			
□ 1.4	63(42.0)			
<b>Echotexture</b>				
Heterogeneous	39(26.0)	12(30.8)	27(69.2)	0.506
Intermediate	24(16.0)	9(37.5)	15(62.5)	0.379
Homogeneous	87(58.0)	15(17.2)	72(82.8)	0.189
<b>Echogenicity</b>				
Hyperechoic	3(2.0)	0	3(100.0)	1.000
Isoechoic	69(46.0)	12 (17.4)	57(82.6)	0.313
Hypoechoic	78(52.0)	24(30.8)	54(69.2)	0.243
<b>Posterior Echo Intensity</b>				
Enhanced	60(40.0)	12(20.0)	48(80.0)	0.740
Unaffected	69(46.0)	18(26.1)	51(73.9)	0.750
Attenuated	21(14.0)	6 (28.6)	15(71.4)	1.000
US features	Number of patients	Tissue Diagnosis		P value
		Malignant	Benign	
<b>Pseudocapsule</b>				
Present	57 (38.0)	6 (10.5)	51(89.5)	0.100



Absent	93(62.0)	30(32.3)	63(67.7)	0.100
<b>Edge of refraction</b>				
Present	54 (36.0)	6(11.1)	48(88.9)	0.170
Absent	96 (64.0)	30(31.3)	66(68.8)	0.109
<b>Calcifications</b>				
Present	9 (6.0)	ND	ND	-
Absent	141 (94.0)	ND	ND	-

Significant figures  
 + Suggestive significance 0.05<P<0.10  
 \* Moderately significant 0.01<P 0.05  
 \*\* Strongly significant P 0.01

[Table 1] shows the frequency of specific US features and the correlation between these specific features and the tissue diagnosis (benign vs. malignant). The US features most predictive of a benign tissue diagnosis were oval or round shape, circumscribed margins, presence of edge refraction, and width-to-AP dimension ratio greater than 1.4. The features most predictive of a malignant tissue diagnosis were spiculated or microlobulated margins, irregular shape, ill-defined margins, and width-to-AP dimension ratio of 1.4 or less.

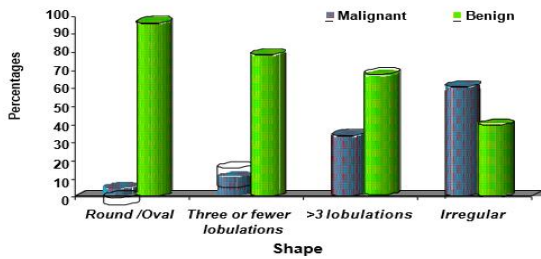


Figure 1: Correlation of shape of the masses with tissue diagnosed benign and malignant masses

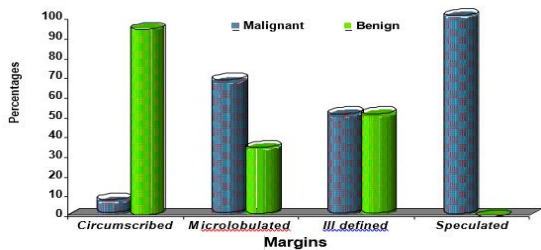


Figure 2: Correlation of margins of the masses with tissue diagnosed benign and malignant masses

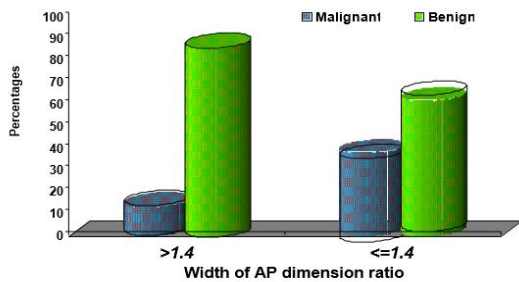


Figure 3: Correlation of AP dimensions of the masses with tissue diagnosed benign and malignant masses

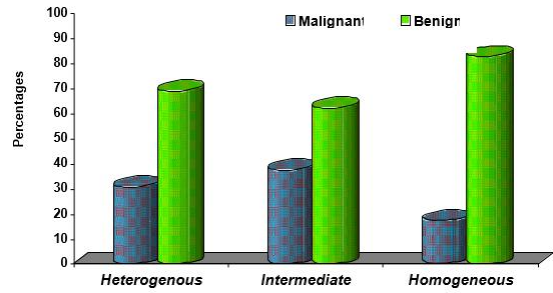


Figure 4: Correlation of echotexture of the masses with tissue diagnosed benign and malignant masses

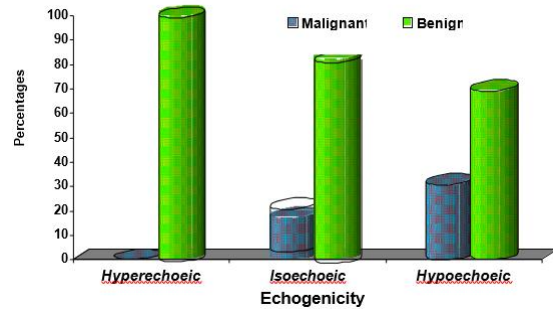


Figure 5: Correlation of echogenicity of the masses with tissue diagnosed benign and malignant masses

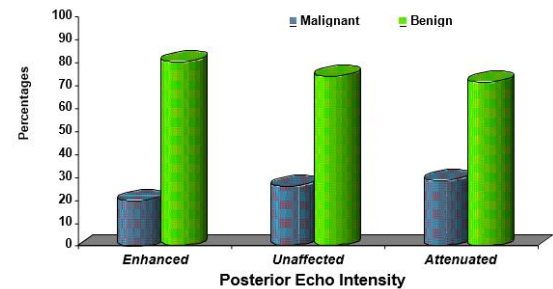


Figure 6: Correlation of posterior echointensity of the masses with tissue diagnosed benign and malignant masses

Some features were not reliable in differentiating between benign and malignant lesions. For example, the effects of masses on posterior echo intensity were not a useful determinant.

Some features that showed excellent correlation with a benign or malignant tissue diagnosis were too infrequent to be generally applicable. For example, a hyperechoic lesion was very reliable as a predictor of benignity but was reported in only 2% of the masses.

RESULTS

?

DISCUSSION

The role of USG in breast imaging has evolved through the years. In most clinical practices, the applications of breast USG has been restricted to

differentiation of cysts from solid masses. Today, USG also play a significant role in guiding interventional procedures that include needle aspiration, core-needle biopsy, and prebiopsy needle localization. Recently, screening USG has also been promoted for the dense breast. The purpose of our study was to study the general applicability of USG features in distinguishing benign from malignant solid breast masses. Since only cases with positive results were evaluated, our study does not address detectability. Also, the role of USG in differentiating benign from malignant solid masses is still under research. The investigators in numerous studies in the past have described specific USG findings to determine if a solid mass is benign or malignant.<sup>[24,25]</sup> The characteristic features of masses usually analyzed are shape, margins, and echogenicity. A recent investigation by Stavros et al has renewed interest in the potential value of these US diagnostic criteria. However, in the latter investigation, one highly experienced radiologist obtained and interpreted the images, so the accuracy might not be reproducible in general practice.<sup>[26,27]</sup> For an individual US characteristic to be deemed to have practical applicability in the differentiation of benign from malignant lesions, we concluded that it must (a) be present frequently and (b) help reliably distinguish benign from malignant lesions. For example, although a hyperechoic lesion was a reliable predictor of benignity if present, it was infrequently observed in our cases and therefore not generally applicable. The effect of a mass on posterior echoes was not reliable for differentiating benign from malignant masses. Overall, the least useful US features in our study were echogenicity, presence of pseudocapsule, posterior echo intensity, presence of calcifications, and echotexture. In our study, we identified three features described in the literature that best met the criteria of frequency and reliability. These three features were the shape, margins, and width-to-AP dimension ratio of the mass [Table 1]. It is important to emphasize that the criteria for differentiating benign from malignant solid masses should be strictly applied, as emphasized by Stavros et al. Therefore, we conclude that these characteristics could be strictly applied to predict a diagnosis of benignity. In our analysis of the data showed that use of these three features alone, to identify masses that did not require biopsy could have improved the overall positive predictive value (biopsy yield of carcinoma) by 16% (from 23% to 39%).

In women younger than 30 years, in whom mammography is less useful, US is often considered the modality of choice to initiate the evaluation of a palpable mass.<sup>[28-30]</sup> In our study, the younger women who underwent US but not mammography would have benefited the most from the application of US criteria for benign versus malignant solid masses. Use of the diagnostic criteria would have

eliminated the need for biopsies in the women who did not have mammograms.<sup>[31,32]</sup>

We believe that our study has several strengths. First, very limited such types of studies are done on Indian populations. So, our study will be very useful in reference to the Indian oriented studies. Second, it proves the results of previous studies results and further strengthening the importance of sonomammography in evaluation of breast masses. Thirdly the fact that our study is a prospective evaluation of the cases, but the sample size was relatively small. Other limitation is the single observer interpretation. So, we did not assess interobserver variability in the evaluation of these features and in the final assessments.

When assessing the general usefulness of these US diagnostic criteria as a method of avoiding unnecessary excisional biopsy, it is also important to remember that there are other options for determining whether a solid mass is benign or malignant. For example, fine-needle aspiration biopsy with cytologic analysis is a relatively inexpensive, minimally invasive procedure that many experienced radiologists find useful in the evaluation of solid masses.<sup>[33,34]</sup> Core-needle biopsy is now widely used for the evaluation of nonpalpable solid masses and is readily adaptable to US guidance.<sup>[35,36]</sup> Some women and their physicians will insist on excisional biopsy of a palpable mass because of fear, physician uncertainty, or traditional standard-of-care protocols despite improvements in diagnostic criteria for determining whether a solid mass is benign or malignant.

In conclusion, the results of our study were encouraging in that we were able to identify the most applicable US features for differentiating benign from malignant solid masses. These features have the potential to help decrease the number of biopsies performed for benign solid masses

## CONCLUSION

Breast cancer is one of the leading killers in both developed and developing countries. So, the consciousness about this is increasing in the society. Screening for the breast cancer is one of the most common prescribed procedure which includes mammography/sonomammography alone or both. The main aim of these investigations is to identify the mass and to differentiate whether the lesion is a benign or a malignant disease. The emphasis on early detection of cancer and not to miss a malignant lesion in early stage of disease and the current medico-legal environment encourage an aggressive biopsy approach to breast problems. The large number of biopsies performed for benign breast abnormalities has long been recognized as a serious problem. Excessive biopsies for benign lesions have adverse effects on society and on the women who undergo them by increasing the costs of screening

projects, causing morbidity, and adding to the barriers that keep women from using a potentially life saving procedure. Improvements in US equipment have prompted more recent studies with findings that describe reliable signs for differentiating benign from malignant masses. Many Indian and foreign studies have published their results with respect to the features differentiating the benign and malignant sonomammography features. In our study we performed the prospective analysis of the sonomammography findings in correlation with tissue diagnosis. The results of our study well correlated the results of the prior studies. The US features in our study most predictive of a benign tissue diagnosis were oval or round shape, circumscribed margins, presence of edge refraction, and width-to-AP dimension ratio greater than 1.4. The features most predictive of a malignant tissue diagnosis were spiculated or microlobulated margins, irregular shape, ill-defined margins, and width-to-AP dimension ratio of 1.4 or less. Some features were not reliable in differentiating between benign and malignant lesions. For example, the effects of masses on posterior echo intensity were not a useful determinant. Some features that showed excellent correlation with a benign or malignant tissue diagnosis were too infrequent to be generally applicable. The results of our study were encouraging in that we were able to identify the most applicable US features for differentiating benign from malignant solid masses. These features have the potential to help decrease the number of biopsies performed for benign solid masses

## REFERENCES

- Miller AB. The costs and benefits of breast cancer screening. *Am J Prev Med* 1993; 9:175-180.
- Howard J. Using mammography for cancer control: an unrealized potential. *Cancer* 1987; 33:33-48.
- Fletcher SW. Why question screening mammography for women in their forties? *Radiol Clin North Am* 1995; 33:1259-1271.
- Wild JJ, Reid JH. Further pilot echographic studies on the histologic structure of tumors of the living intact breast. *Am J Pathol* 1952; 28:839-861.
- Hilton SW, Leopold GR, Olson LK, Willson SA. Real-time breast sonography: application in 300 consecutive patients. *AJR* 1986; 147:479-486
- Rubin E, Miller VE, Berland LL, Han SY, Koehler RE, Stanley RJ. Hand-held real-time breast sonography. *AJR* 1985; 144:623-627.
- DeLand FH. A modified technique of ultrasonography for the detection and differential diagnosis of breast lesions. *Am J Roentgenol Radium Ther Nucl Med* 1969; 105:446-452
- Cole-Beuglet C, Soriano RZ, Kurth AB, Goldberg BB. Ultrasound mammography. *Radiol Clin North Am* 1980; 18:133-143
- Calderson C, Vilkomerson D, Mezrich R, Etzold KF, Kingsley B, Haskin M. Differences in the attenuation of ultrasound by normal, benign, and malignant breast tissue. *J Clin Ultrasound* 1976; 4:249-254.
- Bamber JC, Cosgrove DO. Quantitative evaluation of real time ultrasound features of the breast. *Ultrasound Med Biol* 1988; 14: 81-87.
- Egan RL, Egan KL. Automated water-path full-breast sonography: correlation with histology of 176 solid lesions. *AJR* 1984; 143:499-507
- Jellins J, Kossoff G, Reeve TS, Barraclough BH. Ultrasonic gray scale visualization of breast disease. *Ultrasound Med Biol* 1975; 1:393-404
- Sickles EA, Filly FA, Callen PW. Breast cancer detection with ultrasonography and mammography: comparison using state-of-the-art equipment. *AJR* 1983; 140:843-845
- Fields SI. Ultrasound Mammographic-histopathologic correlation. *Ultrasound imaging* 1980; 2:150-161.
- Kikuchi Y, Uchida R, Tanaka K, Wagai T. Early cancer detection through ultrasonics. *J Acoust Soc Am* 1957; 29:824-827.
- Kopans DB, Meyer JE, Lindfords KK. Whole-breast US imaging: 4-year follow-up. *Radiology* 1985; 157:505-507.
- Forange BD, Toubas O, Morel M. Clinical, mammographic, and sonographic determination of preoperative breast cancer size. *Cancer* 1987; 60:765-771
- Bassett LW, Kimme-Smith C, Sutherland LK, Gold RH, Sarti D, King W, III. Automated and hand-held breast US: effect on patient management. *Radiology* 1987; 165:103-108
- Parker SH, Jobe WE, Dennis MA, et al. US-guided automated large-core breast biopsy. *Radiology* 1993; 187:507-511
- Hilton SW, Wilson SA. Real time breast sonography.: application in 300 consecutive patients. *AJR* 1986; 147:479-486.
- Venta LA, Saloman CG, Flisak ME. Sonographic evaluation of the breast. *Radiographics* 1994; 14: 29-50.
- Bernard Rosner (2000), *Fundamentals of Biostatistics*, 5th Edition, Duxbury.
- M. Venkataswamy Reddy (2002), *Statistics for Mental Health Care Research*, NIMHANS publication, INDIA
- Kobayashi T. diagnostic ultrasound in breast cancer: analysis of retro tumorous echo patterns correlated with sonic attenuation by cancerous connective tissue. *JCU* 1979; 7: 471-479.
- Guita Rahbar, MD et al. Benign versus Malignant Solid Breast Masses: US Differentiation. *Radiology*. 1999;213:889-894.
- Harvey SC, Meyer J. Fibrous nodules found at large core needle biopsy of breast; imaging features. *Radiology*. 1999; 211:535-540.
- Jay M. Feder, MD, Ellen Shaw de Paredes, MD, Jacquelyn P. Hogge, MD and Jennifer J. Wilken, MD. Unusual Breast Lesions: Radiologic-Pathologic Correlation *Radiographics*. 1999;19:S11-S26.
- Cole-Beuglet C, Goldbesrg BB. Fibroadenoma of the breast: sonomammographic correlated with pathology in 122 patients. *AJR* 1983;140:369-375.
- Forange BD, Andry E, Lorrigan JG. Fibroadenoma of the breast: sonographic appearance. *Radiology* 1989; 172:671-675.
- Moskowitz M. circumscribed lesion of the breast. *Radiological society of North America*, 1986; 31-33.
- Mallik R. Bharadwaj VK. Breast lesions of young females. A 20-year study for significance of early recognition. *Indian J Pathol microbial* 2003; 46:559-562.
- A.T.Stavros M D. Solid breast nodules: Use of sonography to distinguish between benign and malignant lesions. *Radiology* 1995;196:123-134.
- Sawhney S. Ultrasound appearance of galactoceles *J Clin Ultrasound* 2002; 30:18-22
- Sickles EA. Use of breast imaging procedures to avert the biopsy of benign lesions. In: Marguilis AR, Gooding CA, eds. *Diagnostic radiology* 1983; 423-426.
- Berkowitz JE et al. equivocal mammographic findings: evaluation with spot compression. *Radiology* 1989; 171:369-371.

36. Basset LW, Ysreal C. usefulness of mammography and sonography in women less than 35 years old. Radiology 1991; 180: 831-835.

**How to cite this article:**Holla K, Junise M, Sojan S, Harshavardhan N. Evaluation of Palpable Breast Masses by Ultrasound and its Correlation with Tissue Diagnosis in a Tertiary Care Centre in Northern Kerala. Ann. Int. Med. Den. Res. 2018; 4(1):RD12-RD19.

**Source of Support:** Nil, **Conflict of Interest:** None declared