

Infiltrating Intramuscular Lipoma: A Rare Case Report.

Prabhjot¹, Simrat Jit Kaur¹, Shilp Rani¹, Ramesh Kumar Kundal², Medhavi¹

¹Junior Resident, Department of Pathology, Government Medical College, Patiala.

²Professor & Head, Department of Pathology, Government Medical College, Patiala.

Received: November 2017

Accepted: November 2017

Copyright: © the author(s), publisher. It is an open-access article distributed under the terms of the Creative Commons Attribution Non-Commercial License, which permits unrestricted non-commercial use, distribution, and reproduction in any medium, provided the original work is properly cited.

ABSTRACT

Lipomas are the common benign tumors of adipose tissue, but sometimes clinically and grossly they simulate malignancy. Lipomas can also occur in deep soft tissues. One of its rare subtype is Intramuscular lipoma which arise within the skeletal muscle fibers. Most common site is trunk, but can also occur in thigh and head and neck. 20 % recur due to incomplete excision. Histopathology is must for confirmation of the diagnosis. Prognosis of intramuscular lipoma is very good and marginal excision is the treatment of choice. We report a case of a 23 Year old female, who presented in surgery OPD with chief complaint of swelling at upper right side of back since 1 year. She got operated for the same 8 months back but presented with similar complaint at same site after 4 months. Excision of the swelling was done and sent for histopathology. On gross examination skin covered soft tissue piece, grayish brown in color was received. Histopathology revealed Infiltrating intramuscular lipoma. The case was reported because of its rarity.

Keywords: Infiltrating intramuscular lipoma, skeletal muscle.

INTRODUCTION

Lipomas are the most common benign soft tissue tumors.^[1,2] Lipomas occur in 2% of the population and make up 50% of all musculoskeletal soft tissue tumors.^[3] Lipomas are composed of mature lipocytes.^[4,5] They can grow to large size; they are usually encapsulated when located in superficial soft tissues but tend to be poorly circumscribed when arising in deeper structures.^[6,7] Deep seated lipomas which arise within skeletal muscle fibres are called intramuscular and which arise between the skeletal muscle fibres are called inter-muscular lipomas.^[1] Most common site of Intramuscular lipoma is trunk, and that of intermuscular lipoma is anterior abdominal wall.^[8] Intramuscular lipoma accounts for 1.8% of all adipose tissue tumors and <1 % of all lipomas.^[2] It usually occurs in age group of 40-70 years, more common in obese.^[1,2] Intramuscular lipomas are of 3 types: infiltrative, well defined and mixed. Many of the inter-muscular and few intramuscular grow by expansion and enclosure of other structures rather than infiltration.^[2]

CASE REPORT

A 23 Year old female, resident of Mandi gobindgarh, district Fatehgarh sahib, Punjab

Name & Address of Corresponding Author

Dr Prabhjot
Junior Resident,
Department of Pathology,
Government Medical College,
Sangrur Road, Patiala – 147001.

presented in surgery OPD with chief complaint of swelling at upper right side of back since 1 year. Swelling was gradually and progressively increasing in size and was non tender. During physical examination swelling was soft to firm, non tender measuring 6x3 cm. She got operated for the same 8 months back but presented with similar complaint at same site after 4 months. Histopathology done from private lab at that time gave the report of lipofibroma. Now, first fine needle aspiration cytology was done in the department of pathology, Government Medical College Patiala from multiple sites of swelling. Cytology showed features of lipoma. Excision of the swelling was done and was sent for histopathological examination.

On gross examination skin covered soft tissue piece, grayish brown in color, measuring 7x4x2 cm was received. Cut section was soft to firm in consistency and cut surface was white yellow in color.

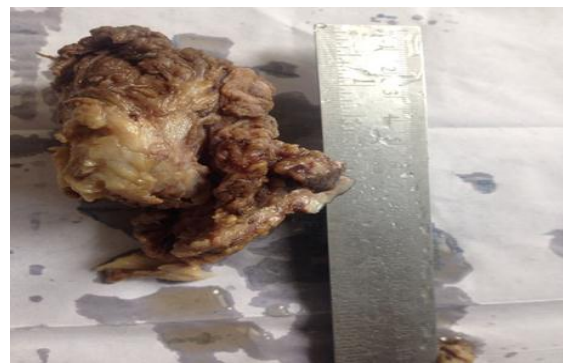

Figure-1: Gross: skin covered soft tissue piece, grayish brown in color.



Figure 2: Cut surface: white yellow in color.

On microscopic examination mature lipocytes infiltrating the skeletal muscle seen. At places muscle showed atrophy. Few areas of fibrosis also seen.

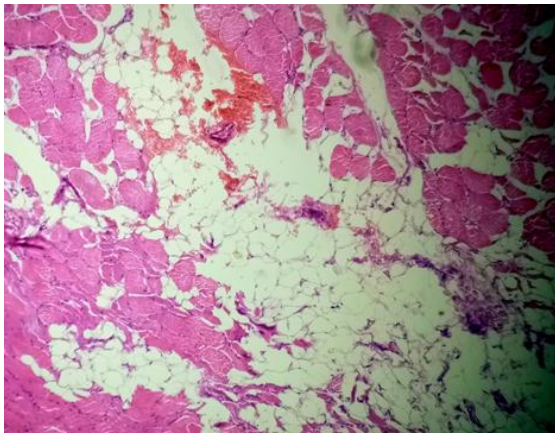


Figure 3: Photomicrograph of mature lipocytes infiltrating the skeletal muscle (H&E, x40).

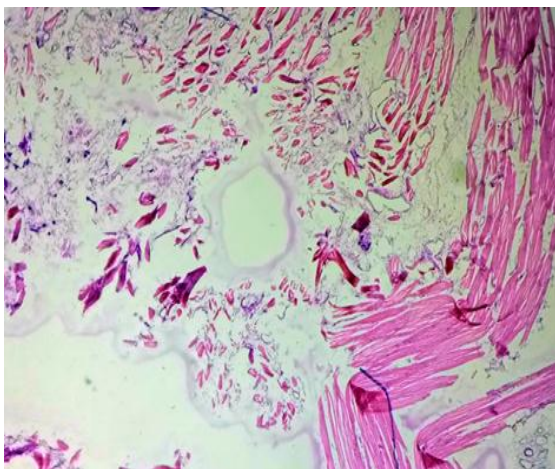


Figure 4: Photomicrograph showing muscle atrophy (H&E, x100).

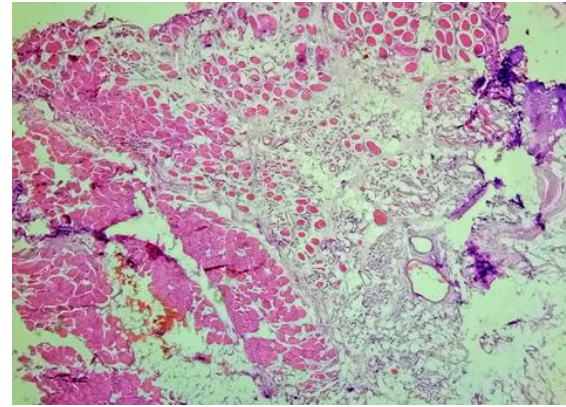


Figure 5: Photomicrograph showing fibrosis (H&E, x40).

DISCUSSION & CONCLUSION

Infiltrating intramuscular lipomas most likely originate from multipotent mesenchymal cells. In our case the probable cause of recurrence is incomplete surgical excision. Clinically, lipomas usually present as a painless soft tissue mass. The larger ones can be painful when they compress peripheral nerves. Superficial lipomas are generally smaller (<5cm) and well circumscribed and the deep seated ones (>5cm) tend to be poorly circumscribed.^[6,7] Consistency varies with density of fibrous tissue stroma. Clinically, infiltrating intramuscular lipomas are difficult to differentiate from other benign and malignant masses of soft tissue.^[1,9] In our case, swelling was soft to firm, non-tender and poorly circumscribed. Grossly it was skin covered soft tissue piece, grayish brown in color, measuring 7x4x2 cm. Cut section was soft to firm in consistency and cut surface was white yellow in color. Intramuscular and inter-muscular lipoma do not show any specific gross features except that a portion of skeletal muscle is often attached to the periphery of the tumor. In infiltrative type, bundles of muscle fibres can be noticed passing through the tumor.^[1,2] In our case, excised soft tissue mass measured around 7x4x2 cm in size.

Microscopically, infiltrative intramuscular lipomas consist of mature adipocytes of uniform size and shape, which infiltrate between muscle fibres and at places, completely replace the muscle fibres. In transverse sections, muscle fibres show chequer board-like appearance. In longitudinal sections, muscle fibres show striations. Adipocytes contain small flattened and peripheral nuclei with no atypia or pleomorphism. No lipoblasts are seen.^[10] While, differentiating infiltrative type from well circumscribed intramuscular lipomas, well circumscribed type is composed of discrete mass of uniform, mature adipocytes, which is clearly delineated from the surrounding muscle. No fatty infiltration of adjacent muscle fibres and entrapped muscle is typically seen within the tumor itself. In these cases, fibrous stroma condenses towards

periphery to form a capsule. Also no cytological atypia or lipoblasts are seen.^[2,10] The sub classification of conventional lipoma does not have any prognostic significance except for the infiltrating intramuscular lipoma that has a higher local recurrence rate. Therefore total removal of the involved muscle or a compartmental resection is advised for these infiltrating tumors in order to minimize local recurrence.^[1] Histologically, differential diagnosis of infiltrating intramuscular lipoma is mainly from well differentiated liposarcoma. Well differentiated liposarcoma contains atypical cells or vacuolated lipoblasts admixed with fibroblasts.

REFERENCES

1. Cummings Charles W., Paul W. Flint. Benign Vocal Fold Mucosal Disorders Cummings Otolaryngology - Head and Neck Surgery. Philadelphia, PA: Mosby Elsevier, 2010.
2. Fletcher CDM, Unni KK, Mertens F. Pathology and Genetics of Tumours of Soft Tissue and Bone, World Health Organization Classification of Tumours. IARC press. Lyon 2002.
3. Murphey M.D., Carroll J.F., Flemming D.J., Pope T.L., Gannon F.H., Kransdorf M.J. From the archives of the AFIP: benign musculoskeletal lipomatous lesions. Radiographics. 2004;24(5):1433-1466.
4. Bispo Junior R.Z., Guedes A.V. Parosteal lipoma of the femur with hyperostosis: case report and literature review. Clinics (Sao Paulo) 2007;62(5):647-652.
5. Terzioglu A., Tuncali D., Yuksel A., Bingul F., Aslan G. Giant lipomas: a series of 12 consecutive cases and a giant liposarcoma of the thigh. Dermatol Surg. 2004;30(3):463-467.
6. Greenberg SD, Isensee C, Gonzalez-Angulo A, Wallace SA: Infiltrating lipomas of the thigh. Am J Clin Pathol 1963; 39:66-72.
7. Kindblom L-G, Angervall L, Stener B, Wickbom I: Intermuscular and intramuscular lipomas and hibernomas. A clinical, roentgenologic, histologic, and prognostic study of 46 cases. Cancer 1974; 33:754-762.
8. Fletcher CD, Martin-Bates E: Intramuscular and intermuscular lipoma: neglected diagnoses. Histopathology 1988; 12:275-287.
9. Bjerregaard P, Hagen K, Daugaard S, Kofoed H. Intramuscular lipoma of the lower limb. Long-term follow-up after local resection. J Bone Joint Surg Br. 1989;71:812-5.
10. Ramos Pascua L, Alonso León A, Santos Sánchez JA, Ferrández Portal L. Intramuscular lipoma of the deltoid mimicking a sarcoma. A case report. Chir Organi Mov. 2001;86:153-7.

How to cite this article: Prabhjot, Kaur SJ, Rani S, Kundal RK, Medhavi. Infiltrating Intramuscular Lipoma: A Rare Case Report. Ann. Int. Med. Den. Res. 2018; 4(1):PT09-PT11.

Source of Support: Nil, **Conflict of Interest:** None declared