

Adenomatoid Tumor of Epididymis: A Rare Case Report.

Simrat Jit Kaur¹, Shilp Rani¹, Prabhjot¹, Ramesh Kumar Kundal², Vikram³

¹Junior Resident, Department of Pathology, Government Medical College, Patiala.

²Professor & Head, Department of Pathology, Government Medical College, Patiala.

³Senior Resident, Department of Pathology, Government Medical College, Patiala.

Received: October 2017

Accepted: October 2017

Copyright: © the author(s), publisher. It is an open-access article distributed under the terms of the Creative Commons Attribution Non-Commercial License, which permits unrestricted non-commercial use, distribution, and reproduction in any medium, provided the original work is properly cited.

ABSTRACT

Adenomatoid tumors are rare benign neoplasms of the paratesticular region, most commonly occurring at the tail of the epididymis. We present a case of adenomatoid tumor in a 65 year old male, known case of prostatic adenocarcinoma, who presented in Urology OPD with painless swelling in testis. Bilateral orchidectomy was done with clinical suspicion of testicular carcinoma. On histopathology, diagnosis of adenomatoid tumor of epididymis was made. Due to its rarity, it is important for the physician and pathologist to be aware of this interesting entity in order to make a correct diagnosis.

Keywords: Adenomatoid Tumor, Epididymis, Paratesticular.

INTRODUCTION

The term “Adenomatoid tumor” was first described by Golden and Ash in 1945 for certain peculiar neoplasms of the genital tract of unknown histogenesis.^[1] In males most common site is epididymis but it can also occur in testicular spermatic cord and ejaculatory duct. These tumors represent 30% of the paratesticular tumors.^[2] In females adenomatoid tumor can occur in fallopian tube and uterus. It is usually seen in the third and fourth decade of life with mean age of 36 years.^[3] Clinically it present as small, firm asymptomatic intrascrotal mass, sometimes associated with pain. According to histology, patterns seen are: tubular, angiomatoid, solid (plexiform), and cystic. Although various theories about their histogenesis have been formulated (mesothelial, endothelial, Mullerian, and mesonephric origin), the hypothesis of their mesothelial origin prevails and is also supported by the electron microscopy study.^[4] Grossly, it appears as small (average size, 2 cm), solid, firm, grayish white nodule. Major microscopic features include fibrous stroma and vacuolated epithelial cells. Vacuoles may vary in size; sometimes they occupy most of the cell’s cytoplasm.^[2] Nuclear atypia and local invasive behavior have sometimes been noticed, especially in tumors in the head of epididymis.^[3,5]

Name & Address of Corresponding Author

Dr Simrat Jit Kaur
Junior Resident,
Department of Pathology,
Government Medical College,
Sangrur Road,
Patiala – 147001

CASE REPORT

A 65 Year old male, known case of prostatic adenocarcinoma diagnosed 2 months back presented in Urology OPD with painless swelling in testis. During physical examination, 2 cm hard nodule was felt on posterior surface in right testis and 7 mm hard nodule in left testis near the epididymal area. Bilateral orchidectomy was done with clinical suspicion of testicular carcinoma. The specimen was sent for histopathological examination in the department of pathology, Government Medical College Patiala.

On gross examination one testis measuring 4x3x2 cm and another measuring 3x2x1 cm were received. In both testis, firm to hard nodule was appreciated near the epididymis, one measuring 1x1 cm and another measuring 0.5x0.5 cm. Grossly, both the testis were normal. Cut surface of nodules were grayish-white.

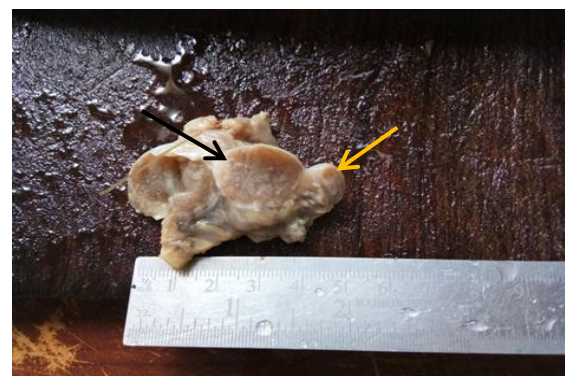

Figure 1: Gross: Cut section showing normal looking testis (Black arrow) and Grayish white nodule in the epididymis (Yellow arrow).

On microscopic examination, sections studied from both the testis were unremarkable. Sections studied from the epididymis showed cystically dilated spaces and tubules. Some of them were lined by flattened cells while other by cuboidal cells. The intervening stroma showed fibrosis and inflammation.

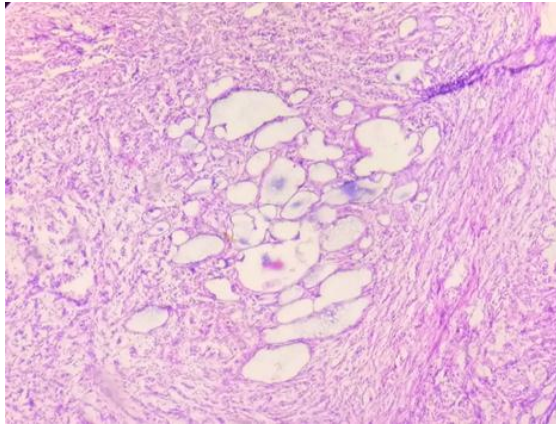


Figure 2: Photomicrograph showing cystically dilated spaces. Stroma is showing fibrosis and inflammation (H&E, ×40).

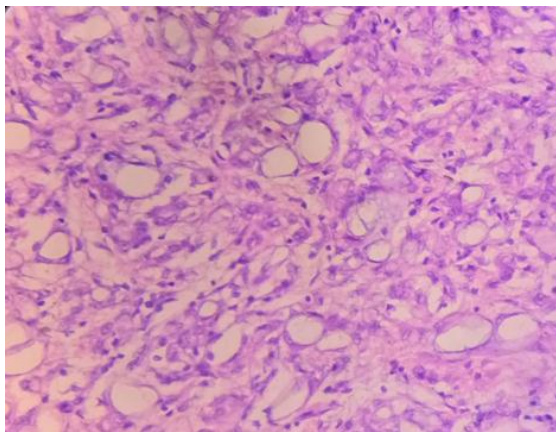


Figure 3: Photomicrograph showing some tubules lined by cuboidal cells (H&E, ×100).

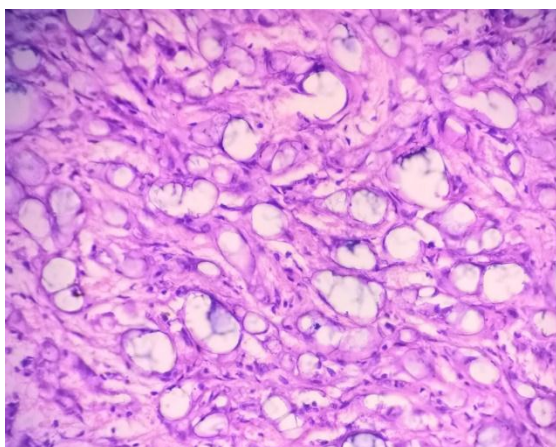


Figure 4: Photomicrograph showing tubules lined by flattened cells giving the appearance of endothelial cells (H&E, ×400).

DISCUSSION & CONCLUSION

Paratesticular tumors are uncommon and comprise less than 5% of all intrascrotal tumors. Epididymal epithelial tumors are a rare subtype of paratesticular tumors with the adenomatoid tumor being most common followed by the papillary cystadenoma and the leiomyoma.^[6] These tumors usually arise in the epididymis, and approximately 14% of paratesticular adenomatoid tumors arise from the testicular tunica.^[7] The main cause for involvement of genital regions is unknown but it may also involve adrenals, lymph nodes, pancreas, mediastinum and pleura.^[8-11] Although these tumours most commonly present between 30 to 40 years but they can affect any age and cases have been reported in children as well as in old age group. They can be bilateral but have propensity towards left side than the right side.^[12] Microscopically, the lesion is uncapsulated and poorly circumscribed (in contrast with its female counterpart), and on rare occasions it may extend to the adjacent testis. There is a proliferation of cells ranging from cuboidal to flattened, which form solid cords with an epithelial appearance alternating with channels having dilated lumina simulating vascular structures. The prominent intervening stroma may contain abundant smooth muscle and elastic fibers.^[13] It may also have a reactive desmoplastic quality and be infiltrated by inflammatory cells. The tumor cells may exhibit prominent cytoplasmic vacuolization. Histochemically, there is positivity for hyaluronidase-sensitive mucosubstances but negativity for lipids. Immunocytochemically, there is strong reactivity for pankeratin, EMA, calretinin, D2-40 and WT1, and negativity for carcinoembryonic antigen (CEA) and factor VIII (FVIII)-related antigen.^[14] By electron microscopy, the tumor cells have prominent microvilli, desmosomes, and tonofilaments, and the intercellular spaces are dilated.^[15] The differential diagnosis includes epithelioid hemangioma, malignant mesothelioma, metastatic adenocarcinoma, papillary cystadenoma of epididymis, Epididymal carcinoma, and carcinoma of rete testis. Immunohistochemical confirmation with mesothelial-related markers (calretinin, HMBE1) is helpful in the differential with non-mesothelial lesions.^[16] Malignant mesotheliomas usually show abundant necrosis and mitoses while papillary cystadenomas can be differentiated on the basis of numerous papillary infoldings which project into cystic spaces. The absence of staining of epithelial markers is of utility in excluding carcinomas (CEA, PSA, MOC 31/BerEP4) and germ cell tumors (OCT 3/4, Sox2, AFP, PLAP) from the differential diagnosis, while negativity of vascular markers (CD34, factor VIII) excludes a diagnosis of epithelioid hemangioma.

REFERENCES

1. Golden, A. and J. E. Ash. Adenomatoid Tumors of the Genital Tract. *Am. J. Path.*, 21:63, 1945.
2. S. Kontos, I. Fokitis, A. Karakosta et al., "Adenomatoid tumor of epididymis: a case report." *Cases Journal*, no. 1, pp. 206–209, 2008.
3. Amin W, Parvani A V. Adenomatoid tumor of testis. *Clin Med Pathol*. 2009; 2: 17–22.
4. M.Nistal, F. Contreras, and R. Paniagua, "Adenomatoid tumour of the epididymis: histochemical and ultrastructural study of 2 cases," *British Journal of Urology*, vol. 50, no. 2, pp. 121–125, 1978.
5. M. A. Maestro, R. T. Gonzalez, J. M. A. Dorrego, J. De la Pena Barthel, and M. N. M. De Serrano, "adenomatoid tumors of the epididymis and testicle: report of 9 cases and bibliographic review," *Archivos Espanoles de Urologia*, vol. 62, no. 2, pp. 137– 141, 2009.
6. Kuhn MT, MacLennan GT: Benign neoplasms of the epididymis. *J Urol* 2005, 174:723.
7. De Klerk DP, Nime F: Adenomatoid tumors (mesothelioma) of testicular and paratesticular tissue. *Urology* 1975, 6:635-41.
8. Chen KT, Schiff JT. Adenomatoid prostatic tumour. *Urology* 1983; 21: 88-89.
9. Fan K, Johnson DF. Adenomatoid tumour of ejaculatory duct. *Urology* 1985; 25: 653-54.
10. Evans CP, Vaccaro JA, Storrs BG, Christ PJ. Suprarenal occurrence of an adenomatoid tumour. *J Urol* 1988; 139: 348-49.
11. Arcadi JA. Adenomatoid tumour in the tunica albuginea of the testis. *J Surg Oncol* 1988; 37: 38-39.
12. Strigley JR, Hartwick RWJ. Tumours and cysts of the paratesticular region. *Pathol Annu* 1990; 25: 51-108.
13. Akhtar M, Reyes F, Young I: Elastogenesis in adenomatoid tumor. *Cancer* 1976; 37:338-345.
14. Barwick KW, Madri JA: An immunohistochemical study of adenomatoid tumors utilizing keratin and factor VIII antibodies. Evidence for a mesothelial origin. *Lab Invest* 1982; 47:276-280.
15. Taxy JB, Battifora H, Oyasu R: Adenomatoid tumors. A light microscopic, histochemical, and ultrastructural study. *Cancer* 1974; 34:306-316.
16. Skinnider BF, Young RH: Infarcted adenomatoid tumor: a report of five cases of a facet of a benign neoplasm that may cause diagnostic difficulty. *Am J Surg Pathol* 2004, 28:77-83

How to cite this article: Kaur SJ, Rani S, Prabhjot, Kundal RK, Vikram. Adenomatoid Tumor of Epididymis: A Rare Case Report. *Ann. Int. Med. Den. Res.* 2018; 4(1):PT06-PT08.

Source of Support: Nil, **Conflict of Interest:** None declared