

Comparative study of functional outcome in Inter-trochanteric femur fracture associated with lateral trochanteric wall fracture treated with Dynamic Hip Screw & Trochanteric stabilization plate.

Lekhraj Patidar¹, Sunil Rajan², Brejesh Kumar Prasad³, Ashiwani Kumar Pankaj⁴, Rajesh Ranjan⁵, Manvinder Pal Singh Marwaha⁶

¹MS Orthopaedics (Consultant), GD Hospital, 80 feet Road, Hanuman Tal Road, Ratlam, Madhya Pradesh.

²MS Orthopaedics (Consultant), Rajshree Apollo Hospital, Scheme No. 74C, Sector D, Vijaynagar, Indore, Madhya Pradesh.

³Assistant Professor, Department of Orthopaedics, ESIC Medical College, Faridabad.

⁴SR, Department of Orthopaedic Surgery, Lal Bahadur Shastri Hospital.

⁵Associate Professor, Department of Community Medicine, ESIC Medical College and Hospital, Faridabad, Haryana.

⁶Aviation Medicine Specialist, Air Force Central Medical Establishment, New Delhi.

Received: December 2017

Accepted: January 2018

Copyright: © the author(s), publisher. It is an open-access article distributed under the terms of the Creative Commons Attribution Non-Commercial License, which permits unrestricted non-commercial use, distribution, and reproduction in any medium, provided the original work is properly cited.

ABSTRACT

Background: Intertrochanteric fractures are one of the commonest fractures especially in the elderly with porotic bones. Our study was aimed to evaluate effectiveness of implant TSP in preventing above complication of DHS for unstable fracture I/T femur (i.e. Evan's type III & V) measured in terms of fracture collapse, screw impaction, limb shortening & overall functional outcome. **Methods:** This prospective study was conducted in the Department of Orthopaedics, Traumatology, M G M Medical College & associated M. Y. Hospital, Indore from June 2008 to September 2010. 145 cases were registered in the study out of which 81 cases with unstable fracture intertrochanteric femur (type III & V of Evan's) admitted and treated by internal fixation using TSP & DHS included. Preoperative assessment of fracture geometry was done using Evan's classification. Intra operatively pattern of reduction achieved was seen on Antero-posterior and Lateral projections by image intensifier. Using TAD index assessment of Screw placement was done in postoperative period. Neck shaft angle measured on immediate post op x-ray with the help of Goniometer. During 1st follow up (2 weeks post op), 2nd follow up (4 weeks post op), 3rd follow up (3 months post op) and 4th follow up plain radiographs (true AP and true lateral hip with thigh) were obtained to look for signs of union and impaction. Functional results were evaluated after a period of 6 months postoperatively using new criteria devised from Harris hip score taking into consideration the needs of Indian patients (Modified Harris Hip Score). **Results:** Average screw impaction (Fracture collapse) was 15.8mm in DHS group & 6.5mm in TSP group. 20 patients (49%) out of 41 had screw impaction more than 15mm at 6 month of follow up, whereas only 1 patient (2.5%) out of 40 in TSP group. Average shortening in DHS group was 2.33cm & 1.42cm in TSP group. 25 (61%) out of 41 patients of DHS group had shortening more than 2cm whereas only 13 (32.5%) out of 40 patients in TSP group. In significant no. of patients excellent to good functional outcome (Harris Hip Score >60) was seen in TSP treated group. Average functional score was 76 in TSP group & 61.68 in DHS group. 28 patients (70%) out of 40 in TSP group had HHS >60 after 6 months of surgery, whereas only 17 patients (41.5%) out of 41 in DHS group. In type III fracture with TSP was having much better outcome than any other group. **Conclusion:** In unstable intertrochanteric fracture with lateral trochanteric wall fracture, reconstruction of lateral trochanteric wall & abductor mechanism using trochanter stabilizing plate helps in achieving anatomical reduction, imparts stability and prevents excessive sliding of screw & collapse, limb shortening. Thus it helps in achieving overall good functional outcome.

Keywords: Inter-trochanteric femur fracture, Lateral trochanteric wall, Dynamic Hip Screw, Trochanteric stabilization plate.

INTRODUCTION

Name & Address of Corresponding Author

Dr. Brejesh Kumar Prasad
Assistant Professor,
Department of Orthopaedics,
ESIC Medical College,
Faridabad.

Intertrochanteric fractures are one of the commonest fractures especially in the elderly with porotic bones, usually due to low energy trauma like simple fall. It occurs most commonly in age

group above 70 year. It's incidence is increasing & involving more younger age group due to increased life expectancy & high energy trauma. The overall increase in the incidence of trochanteric fracture can be attributed to two factors, one, increased life expectancy which increases the aged population, secondly high energy trauma which victimizes more number of young adults. Due to these reasons both developing and developed countries are facing a sort of epidemic of peritrochanteric fractures. With an aging population, an even larger proportion of our resources will be dedicated to treating these hip fractures in the coming years. Preventing complications is of utmost importance to help these frail patients get back to a functional level.^[1]

The aim of Orthopaedic surgeon is combining union in good position with minimal morbidity, maximum comfort to the patient, early mobilization, decreased complication rate and the greatest economy of hospital beds.^[1,2]

Years ago this fractures was often a terminal event in the life of feeble & fragile patients, who used to die from cardiac, pulmonary & renal complications, which were aggravated by recumbence and immobility that was so often enforced due to improper treatment.^[3]

In spite of improvement and modification in conservative line of treatment the ideal anatomical and functional result could not be achieved. Prolonged immobilization in bed was another important threat to the life of elderly patients. The problem is not of union but of complications arising out of immobilization in bed till fractures heal. Also in young age group where high-energy trauma is often the culprit mode, the anatomy is distorted to the extent that, generally conservative treatment finds no scope.^[4-6]

To reduce the extensive surgical trauma, intramedullary devices were designed, which could be inserted by closed technique causing minimal surgical trauma to the patient. It is universally agreed that the treatment of intertrochanteric fractures is stable internal fixation as early as possible. Stable fixation is the keystones of successful union of trochanteric fractures. Some researchers listed the variables that determine the strength of fracture fragment-implant assembly, these are- a) Bone quality, b) Fragment geometry, c) Reduction, d) Implant design and e) Implant placement.^[7-9]

The Lateral Trochanteric Wall is a key element in the reconstruction of unstable peritrochanteric hip fractures.^[2-4] Excessive collapse & femoral medialisation is commoner in specific fracture type particularly if there is comminution of lateral femoral cortex at the site of insertion of the lag screw. Femoral medialisation & excessive collapse is strongly associated with functional deficit (due to reduced hip mobility, limb shortening & pain),

non-union & fixation failure.^[10] Patients with preoperative or intraoperative fracture of the lateral femoral wall are not treated adequately with a sliding compression hip-screw device, and integrity of the lateral femoral wall should be a major factor in determining the internal fixation device used for fracture stabilisation.^[11]

Addition of Trochanteric stabilization plate to DHS reconstruct lateral trochanteric wall & helps to prevent excessive lateral sliding of the proximal fracture fragment. Excessive fracture impaction and consecutive limb shortening prevented by this additional implant.^[7,11,12] TSP effectively supports the unstable greater trochanter fragment and can prevent rotation of the head-neck fragment.^[13] Value of this implant in preventing femoral medialisation in this specific type of intertrochanteric fracture merit further evaluation.^[14]

Our study was aimed to evaluate effectiveness of implant TSP in preventing above complication of DHS for unstable fracture I/T femur (i.e. Evan's type III & V) measured in terms of fracture collapse, screw impaction, limb shortening & overall functional outcome.

MATERIALS AND METHODS

This prospective study was conducted in the Department of Orthopaedics, Traumatology, M G M Medical College & associated M. Y. Hospital, Indore from June 2008 to September 2010.

145 cases were registered in the study out of which 81 cases with unstable fracture intertrochanteric femur (type III & V of Evan's) admitted and treated by internal fixation using TSP & DHS included. Previously operated cases of unstable fracture intertrochanteric femur treated with DHS also included for retrospective comparison with same type of fracture treated with TSP. These cases were selected on the basis of following criterion.

Inclusion Criteria

- Patients aged 20 year to 65 year
- Intertrochanteric femur fracture Evans type III and V
- Cases with stable group of fracture I/T femur in which iatrogenic intraoperative lateral trochanteric wall fracture occurred

Exclusion Criteria

- Pathological intertrochanteric fractures as there functional outcome differs.
- Compound intertrochanteric fractures were excluded.
- Patient with associated lower limb injuries, vertebral column injuries and incompletely recovered surgical illness were excluded from study group, as they act as confounding factors.

Selection of cases for post op follow up

1. Those cases having post op neck shaft angle between 130 to 140 degrees selected for follow up.
2. Those cases having TAD index less than 25 mm selected for follow up.
3. Those cases which have post op complication of infection excluded from study.
4. Those cases in which bone grafting was done were excluded from study.

Preoperative assessment of fracture geometry was done using Evan's classification. Intra operatively pattern of reduction achieved was seen on Antero-posterior and Lateral projections by image intensifier. Using TAD index assessment of Screw placement was done in postoperative period. Neck shaft angle measured on immediate post op x-ray with the help of Goniometer. During 1st follow up (2 weeks post op), 2nd follow up (4 weeks post op), 3rd follow up (3 months post op) and 4th follow up plain radiographs (true AP and true lateral hip with thigh) were obtained to look for signs of union and impaction. Functional results were evaluated after a period of 6 months postoperatively using new criteria devised from Harris hip score taking into consideration the needs of Indian patients (Modified Harris Hip Score).

Grading of Fracture pattern:

Done using Evan's classification (16)

Type I : Undisplaced 2-fragment fracture

Type II : Displaced 2-fragment fracture

Type III: 3-fragment fracture without posterolateral support, owing to displacement of greater trochanter fragment

Type IV: 3-fragment fracture without medial support, owing to displaced lesser trochanter or femoral arch fragment

Type V: 4-fragment fracture without posterolateral and medial support (combination of Type III and Type IV)

Cases were divided in two groups-

Group A – treated with TSP (40 Pts)

Group B – treated with DHS (41 Pts)

Preoperative Management

- Detailed history of selected cases especially regarding mode of trauma, pre-operative medical and associated illness, ambulatory status, activities of daily living before trauma was recorded.
- X-rays of the affected hip – True AP View & True Lateral View
- Depending upon the age and pattern of fracture as per x-ray, above knee skin traction or upper tibial Steinmann pin skeletal traction in Thomas splint was applied.

Preoperative Investigations

- Hb%, TC, DC, ESR
- Blood urea and sugar
- ECG if age more than 30 years
- Chest x-ray if age more than 60 yrs

Operative Management

Majority of the cases were operated under spinal anaesthesia on fracture table in supine position under image intensifier control. Prophylactic antibiotics were used 30 minutes before surgery (third generation IV cephalosporin).

Primary Bone grafting was done in cases where posteromedial cortical contact was not achieved after reduction and fixation.

Interfragmentary screw fixation was done wherever needed.

We followed standard technique for fixation of DHS as recommended by AO.

Dynamic Hip Screw Fixation Technique (As Recommended by AO and used in our institution)

Patient is positioned supine on the fracture table with a radio lucent, padded counter traction post placed between the patient's legs at perineal area. The uninjured leg is abducted and flexed at hip joint and kept held in a well leg holder. Alternatively, the uninjured leg can be held in wide abduction by a boot or foot plate attached to one of the leg extensions of the fracture table. The injured leg is held by a foot plate or boot attached to the other leg extension of the fracture table. Both these positions allow use of C-arm image intensifier positioned between patient's leg to obtain AP and lateral images while keeping the C-arm on non sterile side.

Skin over the hip is prepared by a soap scrub and antiseptic solution. The lateral aspect of hip joint is squared off from iliac crest to the distal thigh with towels and drapes, taking care not to place the towel clips so that they get superimposed over the fracture site on subsequent imaging.

Closed reduction of fracture is performed. Generally, trochanteric fractures can be reduced in neutral or slight internal rotation. Careful adjustment of traction is done to attain reduction avoiding too much traction, which can cause valgus over reduction. Reduction is checked on both AP and Lateral images using image intensifier, paying special attention to cortical contact medially and posteriorly.

Exposure is done through a lateral approach from greater trochanter extending distally. The length of exposure depends upon the length of the implant used.

Trochanter Stabilising Plat Fixation Technique

Procedure is same as DHS except-

1. Slightly longer proximal incision to expose GT.
2. DHS screw must be inserted in a slightly more caudal direction than for the standard technique, if use of antirotation screw is planned.
3. Spoon shaped part of TSP should be contoured appropriately, with plier, to fit GT.
4. Fix DHS TSP plat using 4.5mm cortical screw.
5. Depending on fracture pattern individual fracture fragment of GT can be fixed against spoon shaped

- section of TSP using 4mm screws or cerclage wires.
- An antirotation screw can be inserted cranially & parallel to DHS screw for this a 6.5mm or 7mm or 7.3mm cc screw can be used.
 - Hb%, TC, DC and ESR was done on 2nd postoperative day and check dress on 3rd postoperative day (or as needed).
 - Stitches removed after 12 days.
 - Depending upon type of fracture and stability of fracture fixation, partial weight bearing with support was started accordingly. For stable fractures, partial weight bearing with walker support was allowed within 4 weeks. Unstable fractures and those treated with primary bone grafting partial weight bearing was delayed up to 6 weeks. Full weight bearing was started after confirming sound healing of fracture.

Post Operative Management

- Intravenous antibiotics (Cephalosporins) for 3 days followed by oral antibiotics for another 5 days
- Suction drain removed after 24 hours
- Active and passive physiotherapy of hip, knee and ankle started according to pain tolerance of patients.

Functional result assessment: Harris Hip Score[10]

Pain		Limp	
None	10	None	04
Slight-occasional ache	08	Apparent but habitual	02
Mild-not affecting daily routine relieved with analgesics	06	Permanent	00
Moderate-some limitation in daily activity	04		
Severe-pain is severe but patient is ambulatory	02		
Disabled-severe pain forcing patient to bed	00		
Shortening		Walking Capacity	
None	06	Unaided	12
0-2cm	04	One stick used for long distance only	10
2-4cm	02	One stick routinely	08
>4cm	00	One crutch	04
		Weight relieving calipers	02
		Bed ridden	00
Walking		Climbing Stairs	
Unlimited	08	Unaided	06
Upto 1km	06	With use of banister	04
Upto ½ km	04	With use of stick and banister	02
Indoors only	02	Not possible	00
Bed and chair	00		
Squatting		Cross legged	
Full	06	Full	06
Near full	04	Near full	04
Difficult	02	Difficult	02
Not possible	00	Not possible	00
Knee movement (fixation)		Hip Movement	
>1300	08	75% normal side	03
90-1300	06	50% normal side	02
45-900	04	25% normal side	01
<450	02	None	00
None	00	Scores are given each for individual movements of flexion, extension, adduction, abduction, internal rotation and external rotation, amounting to a maximum of 18 points	
Additional Surgery		Radiological Findings	
None	04	Anatomical reduction	08
Minor procedures	02	Valgus reduction	06
Revision of Surgery	00	Varus reduction	04
		Varus with malrotation	02
		Non-union	00
Working Capacity			
Return to original work	04		
Change of occupation	02		
Not able to work	00		

Measurement of lateral wall impaction/collapse:
Lateral wall impaction measured after 6 months and correlated with functional outcome. Lateral wall impaction is directly proportional to sliding of lag screw out of barrel. Therefore if screw has slid more out of barrel then it means there is

more impaction. This can be measured by subtracting distance of screw thread from barrel tip in 6 month x-ray from similar distance in immediate post op x-ray. If distance of screw thread from barrel tip in 6 months post op x-ray is B and distance between screw thread and barrel tip

is A in immediate post op x-ray then distance through which screw has slid (C) is given by formula:

$$C=A - B$$

This C is directly proportional to lateral wall impaction (I).

$$C= pI$$

(p is coefficient of proportion and it varies with neck shaft angle)

As neck shaft angle selected for study is 130 to 140 degrees, coefficient of proportion is constant for all cases for all practical purpose.

RESULTS

The two groups were compared for their functional outcome at each follow up with Modified Harris Hip score.

Impaction /collapse was measured in both groups at each follow up and correlated with the functional outcome, with the aim to found the relation between two if there is any.

Excellent	90-100
Good	60-89
Fair	30-59
Poor	<30

Table 1: Impaction achieved at fracture site after 6 months.

Group	Impaction measured in mm											
	2-4	>4-6	>6-8	>8-10	>10-12	>12-14	>14-16	>16-18	>18-20	>20-22	>22-24	
Group A	III	06	04	03	00	00	00	00	00	00	00	00
	V	03	09	09	04	01	00	01	00	00	00	00
	Total	09	13	12	04	01	00	01	00	00	00	00
Group B	III	00	01	01	02	02	02	03	01	02	00	00
	V	00	00	00	00	01	06	04	05	05	04	02
	Total	00	01	01	02	03	08	07	06	07	04	02

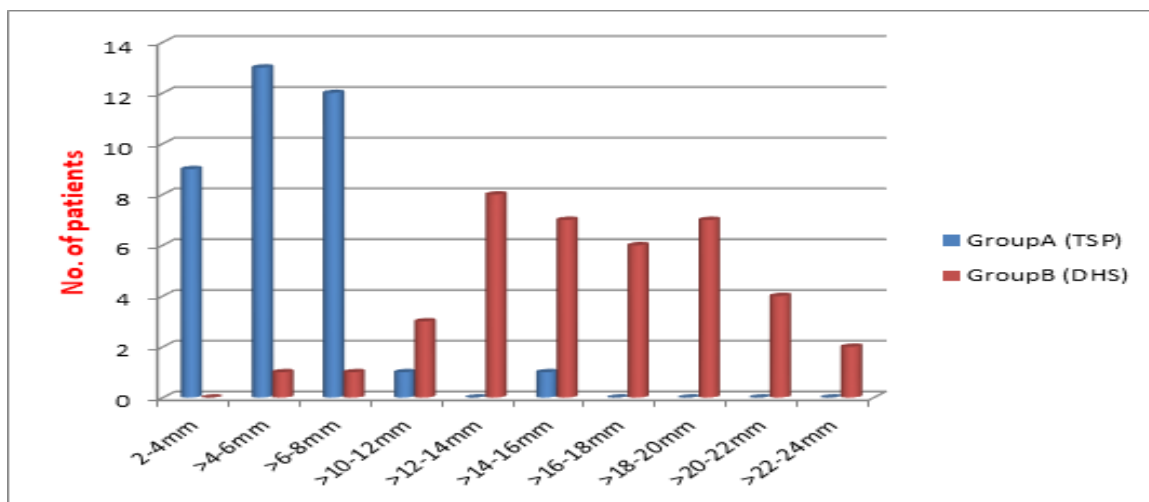


Figure 1: Screw impaction after six months.

Table 2: Limb length shortening after 6 months.

Groups	Grades	Limb shortening in cm after 6 months					Total
		0	0-1	>1-2	>2-3	>3-4	
Group A	III	03	06	04	00	00	13
	V	02	07	05	13	00	27
	Total	05	13	09	13	00	40
Group B	III	01	02	05	06	00	14
	V	00	00	08	15	04	27
	Total	01	02	13	21	04	41

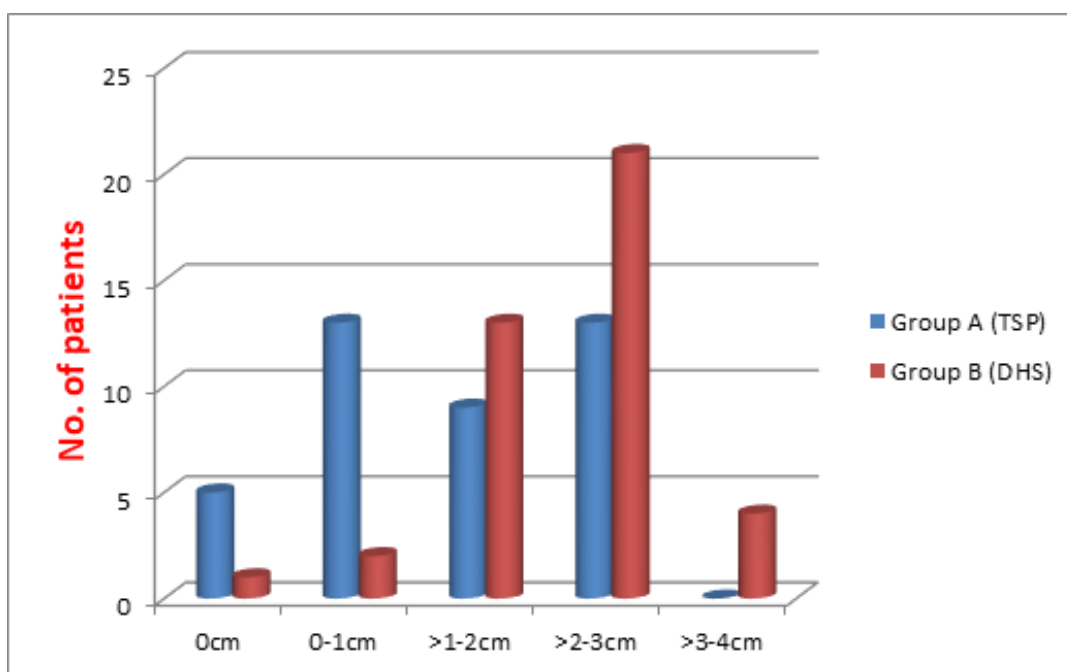


Figure 2: Limb length shortening after 6 months.

Average screw impaction (Fracture collapse) was 15.8mm in DHS group & 6.5mm in TSP group. In our study 20 patients (49%) out of 41 had screw impaction more than 15mm at 6 month of follow up, whereas only 1 patient (2.5%) out of 40 in TSP group. Fisher’s exact test was applied to prove this difference statistically. With a p-value of 0.0001, this difference is statistically highly significant. [Table 1 & Figure 1].

Average shortening in DHS group was 2.33cm & 1.42cm in TSP group. Generally, a leg length discrepancy of 1-2 cm is well tolerated. Gross found no noticeable functional or cosmetic problems in a study of seventy-four adults who had less than 2 centimetres of discrepancy and thirty-five marathon runners who had as much as 2.5 centimetres of discrepancy.

Table 3: Functional outcome (measured by Harris Hip Score) at 6 months.

Group	Grades	Functional Results				Total
		Excellent (HHS 90-100)	Good (HHS 60-89)	Fair (HHS30-59)	Poor HHS<30	
Group A	III	05	05	03	00	13
	V	06	12	08	01	27
	Total	11	17	11	01	40
Group B	III	02	06	05	01	14
	V	00	09	15	03	27
	Total	02	15	20	04	41

In our study 25 (61%) out of 41 patients of DHS group had shortening more than 2cm whereas only 13 (32.5%) out of 40 patients in TSP group. Fisher’s exact test was applied to prove this difference statistically. With a p-value of 0.0143 (<0.05), this difference is statistically significant. [Table 2 & Figure 2].

Average functional score was 76 in TSP group & 61.68 in DHS group. 28 patients (70%) out of 40 in TSP group had HHS >60 after 6 months of surgery, whereas only 17 patients (41.5%) out of 41 in DHS group. Fisher’s exact test was applied to prove this difference statistically. With a p-value of 0.0139 (<0.05), this difference is statistically significant. In significant no. of patients excellent to good functional outcome (Harris Hip Score >60) was seen in TSP treated group. In type III fracture with

TSP was having much better outcome than any other group [Table 3 & Figure 3].

DISCUSSION

Pertrochanteric hip fractures still are a major orthopaedic challenge, and those that are unstable have the poorest prognosis. Despite the fact that union rates are high in intertrochanteric hip fractures, functional outcomes tend to be disappointing.^[9]

Peritrochanteric fractures with lateral wall fracture are very unstable & have poorest prognosis. This extremely unstable fracture results in a severe and prolonged period of postoperative disability. Fracture collapse is one of the postoperative

complications reported in association with these fractures.^[15]

Duty of every orthopaedic surgeon is to get the patient up and out of bed with little pain as soon as possible while causing minimal surgical trauma to the already traumatized patients' as suggested by different authors.^[5]

The age of the patient, the quality of the bone, the pattern of the fracture, the stability of the reduction, the angle of the implant, and the position of the lag screw within the femoral head have all been related to this mechanism of failure. 110 cases were registered in the study treated with dynamic hip screw. In 81 cases neck-shaft angle was between 130 to 140 degrees and TAD index < 25mm.^[8]

A total of 81 cases of trochanteric fractures treated by Dynamic hip screw fixation (41 patients) & Trochanter stabilizing plate (40 patients) were followed in the study for 6 months. The age of patients varied from 28 yrs to 65 yrs. 76% patients were younger than 60 yrs.^[1]

Average age of the patient in this series was 55 yrs, which is significantly lower as compared to various studies published. In 1992, the study showed that cutting out of dynamic hip screw was related to its position. He concluded that central placement for better results than any other location. Although slight inferior location on frontal plane was acceptable, superior placement should always be avoided.^[14]

A research in 1995 showed that central placement of sliding screw resulted in decreased mean value of migration of implant.

The value of the Tip Apex Distance Index in predicting failure of fixation of peritrochanteric fractures of hip from study they concluded that TAD index less than 25mm reduced the chance of cutout to large extend and there is strong statically relationship between increasing Tip-Apex Distance and the rate of cutout, regardless of all other variables related to fracture.^[3]

In 1997 the study concluded that awareness of TAD index reduces the failure of fixation of trochanteric fractures of hip. In their study they attempted to decrease the mean TAD index value to less than 20mm and thereby mechanical failure almost dropped to zero confirming the importance of good surgical technique.^[5]

In 2004 researchers in their milestone study concluded that no. of technical aspect of sliding hip screw fixation affect the final functional outcome. The TAD index with correction for magnification was found to show the most significant difference between patients with cutout against those without (=0.001), followed by the lag screw position on the lateral radiographic reduction of fracture on the anterior-posterior radiograph and the uncorrected TAD index. In our study all the cases with TAD index more than 25 mm were excluded to avoid postoperative failure to be included in study and to

avoid effect of implant placement over post operative functional outcome.^[11]

In elderly, debilitated patients with these type of fracture with severe osteoporotic bone, prosthetic replacement has been claimed to be better option, but again it is technically very demanding surgery and associated with greater blood loss, longer surgical and anaesthetic time, and the potential for more complications, in these already debilitated patients. Of course greater implant cost is also a constrain. Considering all above studies Trochanter Stabilizing Plate appears to be a better option for these very unstable fracture intertrochanteric femur.^[1,9]

CONCLUSION

Average screw impaction (Fracture collapse) was 15.8mm in DHS group & 6.5mm in TSP group. 20 patients (49%) out of 41 had screw impaction more than 15mm at 6 month of follow up, whereas only 1 patient (2.5%) out of 40 in TSP group.

Average shortening in DHS group was 2.33cm & 1.42cm in TSP group. 25 (61%) out of 41 patients of DHS group had shortening more than 2cm whereas only 13 (32.5%) out of 40 patients in TSP group.

In significant no. of patients excellent to good functional outcome (Harris Hip Score >60) was seen in TSP treated group. Average functional score was 76 in TSP group & 61.68 in DHS group. 28 patients (70%) out of 40 in TSP group had HHS >60 after 6 months of surgery, whereas only 17 patients (41.5%) out of 41 in DHS group. In type III fracture with TSP was having much better outcome than any other group.

Therefore it is our conclusion that in unstable intertrochanteric fracture with lateral trochanteric wall fracture, reconstruction of lateral trochanteric wall & abductor mechanism using trochanter stabilizing plate helps in achieving anatomical reduction, imparts stability and prevents excessive sliding of screw & collapse, limb shortening. Thus it helps in achieving overall good functional outcome.

REFERENCES

1. Sarmiento A and Williams EM: Unstable intertrochanteric fracture: Treatment with a valgus osteotomy and I-Beam nail plate. *J Bone Joint Surg* 1970;52:1309-1318.
2. Gotfried Y. The lateral trochanteric wall: a key element in the reconstruction of unstable peritrochanteric hip fractures. *Clin Orthop Relat Res.* 2004; 425:82-86.
3. Rha JD, Kim YH, Yoon SI, et al. Factors affecting sliding of the lag screw in intertrochanteric fractures. *Int Orthop* 1993; 17(5):320-324
4. GS Kulkarni, Rajiv Limaye, Milind Kulkarni, Sunil Kulkarni *IJOYear : 2006 | Volume : 40 | Issue : 1 | Page : 16-23*
5. Bendo JA, Weiner LS, Strauss E, Yang E. Collapse of intertrochanteric hip fractures fixed with sliding screws. *Orthopaedic Review.* 1994; (suppl):30-37.

6. May JMB and Chacha PB: Displacements of trochanteric fractures and their influence on reduction. *J Bone Joint Surg* 1968;50B:318-323.
7. Jensen JS: Classification of trochanteric fractures. *Acta Orthop Scand* 1980;51:803-810.
8. Boyd HB and Griffin LL: Classification and treatment of trochanteric fractures. *Arch Surg* 1949;58:853-866.
9. Kyle RF, Gustilo RB and Premer RF: Analysis of six hundred and twenty two intertrochanteric hip fractures. *J Bone Joint Surg* 1979;61A:216-221.
10. Jewett EL: One-piece angle nail for trochanteric fractures. *J Bone Joint Surg* 1941;23:803-810.
11. McLoughlin SW, Wheeler DL, Rider J, Bolhofner B: Biomechanical evaluation of the dynamic hip screw with two- and four-hole side plates. *J Orthop Trauma*. 2000 Jun-Jul;14(5):318-23.
12. Sarmiento A and Williams EM: Unstable intertrochanteric fracture: Treatment with a valgus osteotomy and I-Beam nail plate. *J Bone Joint Surg* 1970;52:1309-1318.
13. Sarmiento A: Avoidance of complications of internal fixation of intertrochanteric fractures. *Clin Orthop* 1967;53:47-59.
14. Sarmiento A: Intertrochanteric fractures of the femur 150 degree-angle nail plate fixation and early rehabilitation. A preliminary report of 100 cases. *J Bone Joint Surg* 1963;45A:706-722.
15. Dimon JH and Hughston JC: Unstable intertrochanteric fractures of the hip. *J Bone Joint Surg* 1967;49A:440-450.

How to cite this article: Patidar L, Rajan S, Prasad BK, Pankaj AK, Ranjan R, Marwaha MPS. Comparative study of functional outcome in Inter-trochanteric femur fracture associated with lateral trochanteric wall fracture treated with Dynamic Hip Screw & Trochanteric stabilization plate. *Ann. Int. Med. Den. Res.* 2018; 4(2):OR22-OR29.

Source of Support: Nil, **Conflict of Interest:** None declared