

Surgical Outcome in IDEM Tumors in Short Term Follow Up.

Narendra Kumar¹, S. K. Saha¹, S. N. Ghosh¹

¹Bangur Institute of Neurosciences, Kolkata, West Bengal, India.

Received: November 2017

Accepted: November 2017

Copyright: © the author(s), publisher. It is an open-access article distributed under the terms of the Creative Commons Attribution Non-Commercial License, which permits unrestricted non-commercial use, distribution, and reproduction in any medium, provided the original work is properly cited.

ABSTRACT

Background: To review the clinical and histological aspect of IDEM tumors with functional outcome after surgery of all radiologically diagnosed cases of IDEM. **Methods:** 12 cases of IDEM tumors, which had been surgically treated and studied in terms of clinical features as pain by VAS, functional score by Nuricks grading, in preoperative and postoperative period. The correlation of histopathology and tumor size in terms of clinical features and outcome was done. **Results:** Most common diagnosis was schwannoma (83.3%) and rest 2 patients were meningiomas(16.7%), distribution - 3(25%) dorsal, 5(41.6%) lumbar, 2(16.6%) cervical, 1(8%) cervico-dorsal and 1(8%) dorso-lumbar and average percentage of the intradural space occupied by tumor was 77.02%. Average age was 40 years. Meningioma was common in 55 to 60 yr age all female; schwannoma the mean age was 37 year. The most common symptoms were local pain, tingling and numbness, motor weakness which were observed in all the cases. All patients improved postoperatively. VAS score and Nurick grade improved in all. **Conclusion:** Most common pathology was schwannoma then meningioma. All the tumors excised through the posterior approach. The postoperative recovery was good in all the cases regardless of any condition. Therefore, aggressive surgical excision is recommended even for cases with a long duration of symptoms or a severe neurologic deficit.

Keywords: Intra dural extramedullary tumors.

INTRODUCTION

Spinal tumors account for about 15% of central nervous system neoplasm.^[1-3] About two third of tumors are extramedullary. Nerve sheath tumors, meningiomas, and filum terminale ependymomas account for most extramedullary neoplasm.^[4-7] Most nerve sheath tumors are entirely intradural, but 30% extend through the root sleeve as a dumbbell tumor with both intradural and extramedullary component.^[7] Neurofibromas predominate in NF1, schwannomas are more common in NF2.^[8] One percent nerve sheath tumors are intramedullary and are thought to arise from perivascular nerve sheath that accompany penetrating spinal cord vessels.^[9] About 2.5% of of intradural spinal tumors are malignant.^[10]

Meningiomas and nerve sheath tumors occur with equal frequency in adult they usually arises from the arachnoid cap cells embedded in in the dura in root sleeve , accounting for there predominantly lateral position. Meningiomas may also arise from pia or

dural fibroblast, reflecting there probable mesodermal origin,^[3] 75-85% occur in women and about 80% are thoracic.^[7] About 40% of spinal canal ependymomas arise within the filum terminale, most in its proximal intradural portion.

In this study we reviewed the clinical and histological aspect of IDEM tumors along with their functional outcome after surgery of all radiologically diagnosed cases of IDEM and there correlation with size.

MATERIALS AND METHODS

The diagnosed cases of IDEM who underwent surgery between March 2011 to September 2011 in Bangur Institute of Neurosciences, Kolkata, and a non randomized prospective study was done. We had 12 patients in study group.

These patients were studied as in patient and out patient in bangur institute of neurosciences and each patient studied in detail symptomatology according to questionnaire , radiological features, surgical procedure done, follow up of the patient and outcome and histopathological diagnosis. The preoperative duration of symptoms and the symptomatic characteristics were examined. Preoperative pain was assessed by using a 10-point visual analogue scale (VAS). For the assessment of the preoperative neurological function, the patient's ambulation ability was graded into 5 levels according to the Nurick's grading system [Table

Name & Address of Corresponding Author

Dr. Narendra Kumar
Bangur Institute of Neurosciences,
Kolkata,
West Bengal,
India .

1].^[4] For the evaluation of postoperative recovery, functional grading system used.. The location of a tumor on the sagittal and axial MRI images and the percentage of the tumor that occupied the intradural space were investigated to find out any association with out come and severity of preoperative symptoms and the final surgical outcome. The percentage of tumor occupying the intradural space was calculated on the axial image showing the maximum size as follows [Figure 1]: {(the transverse diameter of the tumor mass + the longitudinal diameter of the tumor mass) / (the transvers diameter of the intradural space + the longitudinal diameter of the intradural space)} × 100.

Table 1. Nurick's Functional Grading

Grade	Description
1	Normal walk, possible clinical spinal irritation
2	Slight difficulty in walking with normal domestic and working life
3	Functional disability limiting normal work and domestic activities
4	Significant weakness making walking impossible without help
5	Bedridden or wheelchair bound

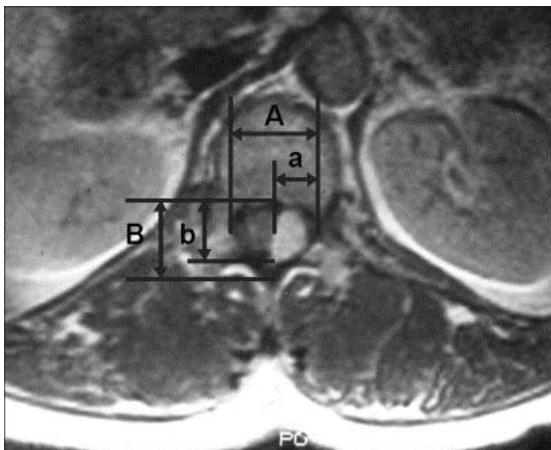


Figure 1: This picture shows how to calculate the percentage of tumor occupying the intradural space on an axial MRI film. It is as follows: $\{(a + b) / (A + B)\} \times 100$. A: transverse diameter of the intradural space, B: longitudinal diameter of the intradural space, a: transverse diameter of the tumor mass, b: longitudinal diameter of the tumor mass.

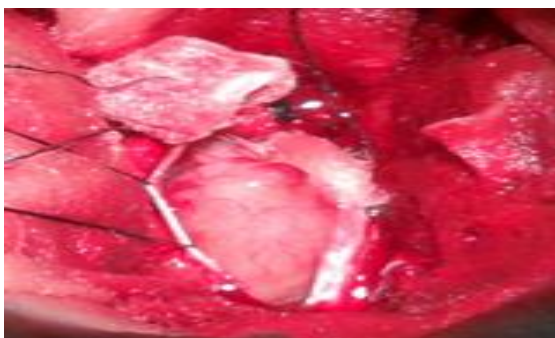

Figure 2: Laminectomy has been done dura opened and tumor dissected the tumor is bulging out in the dural opening.

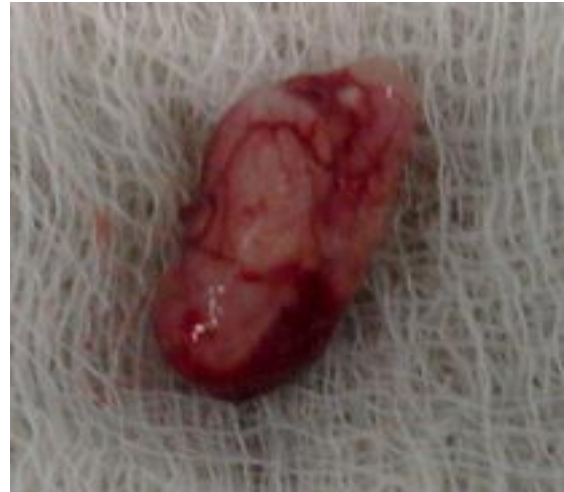

Figure 3: excised tumor.

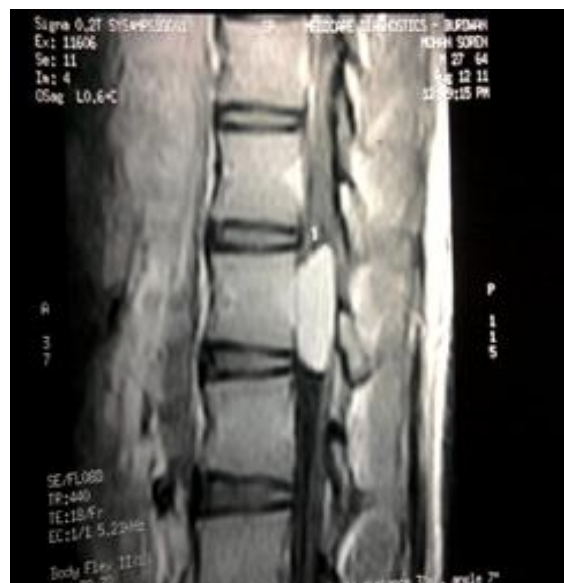

Figure 4: MRI – T1 WI with contrast dorsal spine saggital section (Contrast enhancing lesion anterior to cord)

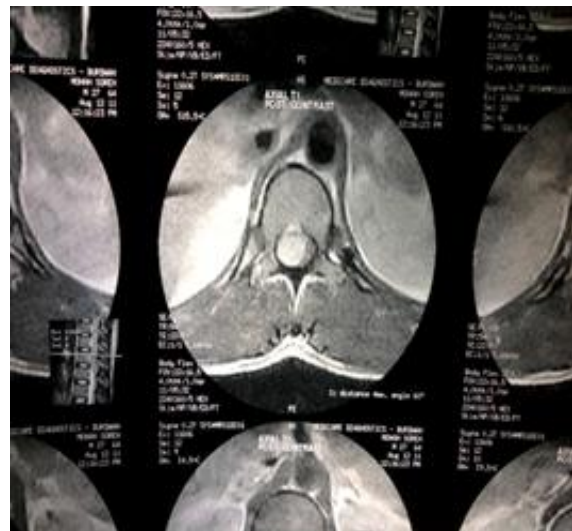

Figure 5: MRI- T1WI with contrast dorsal spine axial section (lesion is Rt. anterio-lateral to cord)

All the patients were operated through posterior approach irrespective of site of tumor laminectomy then durotomy and excision of tumor one carefully with minimal traction, manipulation and those fiber embed or involved sacrificed and in postoperative

period methylprednisolone given in some patient, and incision closure in layers, tissue send for histopathology and follow up done in respect of tone, power reflexes and Nuricks functional grading at 3mth 6 mth and 1 year.

Table 2: Demographic, clinical and radiological data

no	Age/sex	Diagnosis	site	Duration of symptoms	occupancy	VAS score		Nuricks grading		Follow up 3 mth
						preop	postop	preop	postop	
1	35/M	Schwannoma	CD	6YR	80.5%	3	4	3	3	do
2	55/F	meningioma	D	4mth	82%	4	1	4	3	do
3	35/M	Schwannoma	C	3 yrs	85%	0	0	4	4	do
4	32/F	Schwannoma	L	5 days	60%	10	0	5	2	do
5	35/F	Schwannoma	L	6 Yrs	80%	5	1	4	3	do
6	40/M	Schwannoma	C	1.5 yrs	74.2%	8	2	3	2	do
7	29/M	Schwannoma	D	1 Yr	85%	8	1	5	3	do
8	60/F	Meningioma	D	1Yr	85%	6	1	5	4	do
9	45/M	Schwannoma	L	15	65%	9	1	5	3	do
10	35/F	Schwannoma	L	1Yr	80%	8	1	4	3	do
11	55F	Schwannoma	L	3yr	70%	6	2	4	3	do
12	30/F	Schwannoma	DL	6 mth	77.6%	7	1	5	4	do

RESULTS

Pathological diagnosis

There were 10 patients of schwannoma (83.3%) and rest 2 patients were meningiomas (16.7%) in study. Tumor location and percentage of the intra dural space occupying by tumor: - 3(25%) dorsal, 5(41.6%) lumbar, 2(16.6%) cervical, 1(8%) cervico-dorsal and 1(8%) dorso-lumbar and average percentage of the intradural space occupied by tumor was 77.02%.

Age group

Average age group was 40 years. The meningioma was common in 55 to 60 yr age group two cases were in female and rest, for schwannoma the mean age was 37 year from this study.

Symptoms

The mean duration of symptoms was 23.3 months (range from 1 to 72 months) and the mean postoperative follow-up period was 1 months [Table 2]. The most common symptoms were local pain, radicular pain, tingling and numbness, which were observed in all the cases. The symptoms tend to increase during walking rather than during bed rest and sitting. Motor weakness was also observed in all patients (100%). All the cases' symptoms improved postoperatively. the VAS score decreased in all the cases from an average of 6.1 preoperatively to an average of 1.6 at the follow-up of 1 month. The average Nurick's grade improved from 4.25 preoperatively to 3.0 at 1 month follow up. One patient who presented with acute onset of symptoms of 5 days responded very well and improved VAS score and Nuricks grading.

DISCUSSION & CONCLUSION

Previous reports have stated that about 5 females and 3 males out of 1,000,000 people are affected by

primary spinal tumors every year and only 2/3 of them are IDEM tumors.^[5] Due to the rarity of IDEM tumors, it is not easy to enroll a large enough study population to assess a surgical procedure for treating such tumors. Meningiomas account for 25-46% of all primary intraspinal neoplasms and spinal meningiomas are only 7.5-12.5% of all meningiomas because most meningiomas are found in the brain.^[6] Spinal meningiomas are mostly located in the thoracic level and they are more common in females, which is presumably due to the influence of female hormones.^[6] In this study, meningiomas were also found in the thoracic region of female patients. But the incidence was very less Schwannomas have been known to grow with displacing nerve fibers laterally rather than invading them. Even so, complete removal of a schwannoma is only possible when the nerve fibers are also excised in the case of their involvement within the tumor. Most authors have emphasized that the preservation of nerve roots compromises achieving complete tumor removal.^[8-10] Yet according to Kim et al.^[11] only 23% of the complete excisions of schwannomas with functionally important nerve roots resulted in the development of neurological symptoms (not severe ones) because the nerve roots involved in the tumors had already become dysfunctional.

In this study, a posterior approach was used in all the cases regardless of the location of a tumor in and relative to the spinal cord. According to the literature, 31% of the tumors are located ventral to the spinal cord and Slin'ko and Al-Qashqish claimed that an extreme lateral or an anterior approach was necessary for the removal of these tumors.^[12,13] However, extreme lateral approaches require spinal fusion due to the removal of the lamina and the facet joint, and the anterior approaches are difficult to use due to the epidural venous bleeding, the limited field of view and the removal of several vertebral bodies.

In this current study, a posterior approach was used to preserve the bilateral facet joints.

With regard to the factors that influence the prognosis, the longer the preoperative duration of symptoms was, the severe the neurological deficit were.^[1] In addition, we thought that surgical intervention should be recommended for all IDEM tumors regardless of the prognostic factors because the Nurick's grade improved postoperatively for all the cases in our study except one patient. Presumably, the advanced neurological deficits could recover because of the slower progress of nerve compression, as compared with other conditions that present with similar levels of neurological deficit, and provided that the nerve tissues have time enough to adjust.

According to el-Mahdy et al.^[2] the postoperative recurrence rate of IDEM tumors was 16%. According to Asazuma et al,^[8] the recurrence rate of intraspinal neoplasms was 7.2% and 46% of recurred masses were IDEM spinal tumors which recur more commonly than other intraspinal tumors. They also reported that the ventral location of a tumor, extradural invasion, neurogenic tumors and ependymomas were the risk factors for recurrence. According to the study on the treatment of ependymomas by Klekamp and Samii,^[15] the recurrence rate was 29.5% at 5 years after complete resection, and this rate was higher than that of other tumors.

The most prevalent spinal IDEM tumor was schwannoma. Postoperatively, remarkable improvements in neurological deficit were achieved regardless of the percentage of tumor occupying the intradural space, the degree of preoperative symptoms and the duration of symptoms. Therefore, surgical intervention is also recommended for spinal IDEM tumors with prolonged or severe neurological symptoms. For making the diagnosis of IDEM tumors, taking a detailed history, a thorough physical examination and performing MRI scans on the proximal regions are recommended because the symptoms of IDEM tumors can be similar with those of lumbar herniated nucleus pulposus and spinal stenosis.

REFERENCES

1. Albanese V, Platania N. Spinal intradural extramedullary tumors: personal experience. *J Neurosurg Sci.* 2002;46(1):18-24.
2. El-Mahdy W, Kane PJ, Powell MP, Crockard HA. Spinal intradural tumours: Part I Extramedullary. *Br J Neurosurg.* 1999;13(6):550-7.
3. Tredway TL, Santiago P, Hrubes MR, Song JK, Christie SD, Fessler RG. Minimally invasive resection of intradural-extramedullary spinal neoplasms. *Neurosurgery.* 2006;58(1 Suppl):ONS52-8.
4. Nurick S. The natural history and the results of surgical treatment of the spinal cord disorder associated with cervical spondylosis. *Brain.* 1972; 95(1):101-8.
5. Helseth A, Mork SJ. Primary intraspinal neoplasms in Norway, 1955 to 1986: a population-based survey of 467 patients. *J Neurosurg.* 1989;71(6):842-5.
6. Solero CL, Fornari M, Giombini S, et al. Spinal meningiomas: review of 174 operated cases. *Neurosurgery.* 1989; 25(2):153-60.
7. Ahn DK, Jung KW, Lee S, Choi DJ, Park JS, Cha SG. A 6-year observation of multiple spinal schwannomas before excision: 1 case report. *J Korean Soc Spine Surg.* 2003;10(3):277-82.
8. Asazuma T, Toyama Y, Watanabe M, Suzuki N, Fujimura Y, Hirabayashi K. Clinical features associated with recurrence of tumours of the spinal cord and cauda equina. *Spinal Cord.* 2003;41(2):85-9.
9. Parsa AT, Lee J, Parney IF, Weinstein P, McCormick PC, Ames C. Spinal cord and intradural-extraparenchymal spinal tumors: current best care practices and strategies. *J Neurooncol.* 2004; 69(1-3):291-318.
10. Prevedello DM, Koerbel A, Tatsui CE, et al. Prognostic factors in the treatment of the intradural extramedullary tumors: a study of 44 cases. *Arq Neuropsiquiatr.* 2003; 61(2A):241-7.
11. Kim P, Ebersold MJ, Onofrio BM, Quast LM. Surgery of spinal nerve schwannoma: risk of neurological deficit at resection of involved root. *J Neurosurg.* 1989;71(6):810-4. 123.
12. Gottfried ON, Gluf W, Quinones-Hinojosa A, Kan P, Schmidt MH. Spinal meningiomas: surgical management and outcome. *Neurosurg Focus.* 2003;14(6):e2.
13. Slin'ko EI, Al-Qashqish II. Intradural ventral and ventrolateral tumors of the spinal cord: surgical treatment and results. *Neurosurg Focus.* 2004;17(1):ECP2.
14. Klekamp J, Samii M. Surgical results of spinal meningiomas. *Acta Neurochir Suppl.* 1996;65:77-81.

How to cite this article: Kumar N, Saha SK, Ghosh SN. Surgical Outcome in IDEM Tumors in Short Term Follow Up. *Ann. Int. Med. Den. Res.* 2018; 4(1): MC03-MC06.

Source of Support: Nil, **Conflict of Interest:** None declared