

Correlation between Pretherapeutic Clinical and Radiological Staging of Laryngeal Malignancy: A Clinico - Radiological Study.

Geeta¹, Bhawana Pant²

¹Third year Resident, E.N.T Department, Government Medical College & S.T.M.F Hospital, Haldwani.

²Associate Professor, E.N.T Department, Government Medical College & S.T.M.F Hospital, Haldwani.

Received: December 2017

Accepted: December 2017

Copyright: © the author(s), publisher. It is an open-access article distributed under the terms of the Creative Commons Attribution Non-Commercial License, which permits unrestricted non-commercial use, distribution, and reproduction in any medium, provided the original work is properly cited.

ABSTRACT

Background: The aim of the study was to find out the correlation between pretherapeutic clinical and radiological staging of carcinoma larynx. **Methods:** This was a prospective cross sectional study carried out in department of ENT at Government Medical College & Dr. Susheela Tiwari government hospital, Haldwani during the period of September 2015 to 2016. 50 adult patients (mainly 4th, 5th, 6th,7th decade) having complaints of hoarseness, throat pain, neck mass etc were subjected to clinical evaluation.. Provisional clinical diagnosis of laryngeal mass was made followed by diagnostic rigid 90 degree laryngoscopy in OPD setting. It was followed by FNAC in cases of lymph node swelling. Radiological evaluation was done using CECT scan neck and MRI (if required). Biopsy of suspected cases (malignant) was done under local or general anesthesia. Pretherapeutic clinical staging was done in patients diagnosed with carcinoma. Using information from CT and MRI pretherapeutic radiological staging was done and these patients were included in the study. Patients having benign neoplasm, lymphoma, recurrent malignant disease and those having undergone radiotherapy were excluded from the study. Comparison between pretherapeutic clinical and radiological staging of carcinoma larynx was done and its impact on treatment options was analyzed during follow up of patients. **Results:** It was observed in the present study that Carcinoma larynx is a male dominant disease mainly seen in elderly age group with mean age group of 65years consuming alcohol along with habit of smoking. Maximum number of cases were of supraglottic malignancy followed by involvement of glottis with no case of subglottic malignancy. In the present study we found that 32% of cases showed upstaging with CT scan, as a result of deep tumor extent undetectable at clinical examination. **Conclusion:** Clinical or endoscopic evaluation fails to identify invasion of the laryngeal framework and of extralaryngeal soft tissues in a high percentage of cases. An additional radiologic examination, either CT or MR imaging, is essential in most laryngeal carcinomas for the correct pretherapeutic staging and proper treatment.

Keywords: Clinical staging, Radiological staging.

INTRODUCTION

The larynx is the most complex of the mucosal lined structures of the upper aero digestive tract. It has an important role in speech, swallowing and airway protection which makes the treatment consideration of malignancy in this region varied and controversial. The larynx is divided into three anatomic regions namely supraglottic, glottic and subglottic. The cartilaginous framework of larynx includes thyroid, cricoid, arytenoid and corniculate cartilages. The incidence of laryngeal cancer ranges from 2.5 to 17.2 per 100,000 people annually where it represents approximately 3%

of newly diagnosed cases of overall malignancy worldwide per year.^[1] 90% of laryngeal malignancy is squamous cell carcinoma followed by lymphoma. Mostly patients with laryngeal carcinoma develop hoarseness however other clinical symptoms includes neck mass, dysphagia , stridor, hemoptysis etc.

Staging of head and neck cancer is a system designed to express the relative severity and extent of disease. It is meant to facilitate an estimation of prognosis and provide useful information for treatment decisions.^[2] The clinical pretreatment classification (cTNM) is based on examination, imaging, endoscopy and biopsy. It has to be recorded in each and every case after collection of all the information.^[3]

A patient with suspected laryngeal carcinoma after examination should be investigated with endoscopy for defining the accurate position and extent of tumour, locate an occult primary, exclude a second primary tumour and finally to obtain biopsy. Endoscopy may include rigid laryngoscopy

Name & Address of Corresponding Author

Dr. Bhawana Pant
Associate Professor,
E.N.T Department
Government Medical College & S.T.M.F Hospital,
Haldwani.

as well fiberoptic endoscopes which help to assess mucosal spread at the primary site and to evaluate the extension into the ventricle of larynx and the subglottis. Pan endoscopy is only recommended for symptomatic patients with primary tumor. Radiological investigations to evaluate the primary site should be performed prior to biopsy. Radiological Imaging provides important information regarding size, site and extent of the primary lesion, neck node involvement (number of nodes, size, position presence/ absence of necrosis and fixation), distant metastasis, detection of synchronous primary tumours and in some cases for confirmation of diagnosis.

Computed tomography images reflect tissue density, which is good at demonstrating bone detail as well as high volume of data from which high spatial resolution images in all planes can be reconstructed with a few minutes of exposure. This is important in many head and neck cancer patients who have difficulty with breathing, swallowing, lying flat and keeping still. The ability of MRI to show abnormal tumour tissue as high signal and normal tissue as low signal in an image creates improved contrast resolution when compared to CT.^[4] Combined information from CT and MRI can be utilized for staging of disease in cancer patients. As MRI takes longer time for screening it is not possible in each and every cancer patient. Scans to evaluate the primary site should be performed prior to biopsy to avoid the effect of upstaging from oedema caused by biopsy. Biopsy should be taken from the viable part of tumor, i.e. not from the centre, which may be necrotic and not from edge, which may only show dysplasia.^[2]

With the help of information from examination findings of larynx, endoscopy and biopsy pretherapeutic clinical staging is done followed by pretherapeutic radiological staging utilizing information from imaging studies like CT and MRI.

MATERIALS AND METHODS

This was a prospective study carried out in department of ENT and Radiology at Dr.Susheela Tiwari Government Hospital and Government medical college Haldwani over a period of one year from September 2015 to 2016. 50 adult patients (mainly 4th, 5th, 6th, 7th decade) were included in the study. Patients having complaints of hoarseness, throat pain, neck mass etc coming in the ENT OPD were evaluated clinically. Provisional clinical diagnosis of laryngeal mass was made followed by diagnostic rigid 90 degree laryngoscopy in OPD setting. It was followed by FNAC in cases of lymph node swelling. Radiological evaluation was done using CECT scan neck and MRI (if required). Biopsy of suspected cases (malignant) was done under local or general anesthesia. Pretherapeutic clinical staging was done in patients diagnosed with

carcinoma. Using information from CT and MRI pretherapeutic radiological staging was done and these patients were included in the study. Patients having benign neoplasm, lymphoma, etc were excluded from the study. Patients having malignant disease with recurrence, having undergone radiotherapy and who were lost to follow up were not included in the study. Comparison between pretherapeutic clinical and radiological staging of carcinoma larynx was done and its impact on treatment options was analyzed during follow up of patients.

RESULTS

A total of 50 patients of laryngeal malignancy were examined. 17 of them were diagnosed as well differentiated squamous cell carcinoma, 12 as moderately differentiated squamous cell carcinoma and 21 as poorly differentiated squamous cell carcinoma on histopathological examination. Out of 50 patients with age ranging from mainly 4th, 5th, 6th, 7th decade, there were 46(92%) males and 4 (8%) female patients showing male dominance. There was history of smoking and alcoholism in these patients.

Presenting complaints-Patients included in the study presented with variety of symptoms. Hoarseness of voice was present in 30 cases(60%), dysphagia in 28 cases (56%), neck mass in 25 cases (50%), throat pain in 20 cases(40%), stridor in 10 cases(20%), referred otalgia in 10 cases (20%) shown in [Table 1, Figure 1]

Table 1: Table showing presenting complaints.

S. No.	Presenting Symptoms And Signs	No. Of Cases; N=50	Percentage (%)
1	Hoarseness of voice	30	60%
2	Dysphagia	28	56%
3	Neck mass	25	50%
4	Throat pain	20	40%
5	Stridor	10	20%
6	Referred otalgia	10	20%

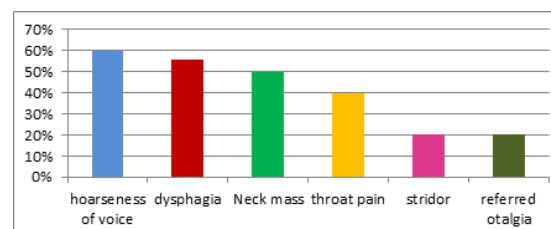


Figure 1: Bar diagram showing symptoms and signs in patients of carcinoma larynx.

Region involvement- When classified according with anatomical sites out of 50 patients, 46 patients(92%) had supraglottic carcinoma followed by glottic carcinoma in 4 cases(6%). There was no subglottic involvement in any of the patients.

Radiological evaluation- Clinical staging was done after complete examination and laryngeal endoscopy. It was followed by radiological imaging. Out of 50 patients, CECT was done in all of the 50 patients. 5 patients required both CECT and MRI (to assess initial cartilage invasion) for final evaluation. On clinical and laryngoscopic examination, 6 laryngeal tumors were classified as T1, 32 patients were as T2, 4 cases were as T3 and 8 cases were classified as T4.

Out of 6 T1 tumors (clinical stage) only 3 tumors were classified as T1 on CT finding. 3 tumors which were classified as T1 clinically found to be T2 on CT scan. In this case upstaging was due to involvement of aryepiglottic fold, which was not confirmed on endoscopy.

Out of 32 T2 tumors (clinically) only 30 tumors were classified as T2 on CT finding. 2 tumors which were T2 clinically were found to be T3 on CT scan. In this case upstaging was due to involvement of paraglottic and Preepiglottic spaces which was better seen on imaging. There was no cases of upstaging of T3 tumor (clinical) to T4 (radiological).

Thus, 5 cases were upstaged due to radiological information obtained from CT and MRI.

In addition to CECT, MRI was also done in 5 patients to rule out earlier cartilage invasion, but didn't show any change and was similar to findings of CT scan. Clinical staging of carcinoma larynx compared with radiological staging.

On clinical examination 24 patients had N0 neck node, 15 were having N1 node, 9 were having N2 and 2 cases had N3 stage of lymph nodes.

Out of 24 N0 neck nodes (clinically) 9 were upstaged to N1 and 1 upstaged to N2 on CT scan. Similarly out of 15 N1 neck nodes (clinically) 2 were upstaged to N2 on CT scan. Clinical examination failed to detect metastatic node of smaller dimensions which was detected better on radiology.

N2 nodes didn't show any upgradation on CT and remains same clinically and radiologically. Thus 12 cases were upstaged on neck node examination by CT.

Final staging was done utilizing information from clinical and radiological assessment. AJCC criteria was applied to all cases for pretherapeutic staging. Out of 50 patients upstaging was seen in 16 patients (32%). Among these 50 patients 5 patients upstaged because of Tumor findings on CT scan and 12 patients upstaged because of node assessment on CT scan. And among these above 17 patients (upstaged)

one patient upstaged from both tumor and neck node assessment making it 16 in number. In rest of the cases there was no change in clinical and radiological staging shown in bar diagram [Figure 2]

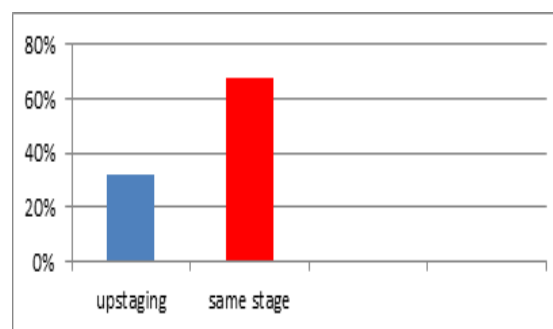


Figure 2: Bar diagram showing pretherapeutic staging of carcinoma larynx.

DISCUSSION

Larynx is oncologically divided into three different subsites: supraglottic, glottic and subglottic. The malignancies in different subsites behave differently. The malignancies in different subsites of larynx have direct impact on the treatment modality, surgical outcome, and prognosis. In laryngeal carcinoma, neck node metastasis is more common in supraglottic and subglottic region while there is hardly any neck metastasis in glottis carcinoma due to anatomical characters. Therefore, glottis carcinomas are easier to manage than supraglottic cancers.

In our study we found that carcinoma larynx is a male dominant disease mainly seen in elderly age group with mean age group of 65 years in concordance with the study carried by Peter Zbaren et al where there were 39 males and 1 female with a mean age of 62 years.^[5] In our study the patients have habit of consuming alcohol and smoking. Maximum number of cases was of supraglottic malignancy followed by involvement of glottis with no case of subglottic malignancy. This is in concordance with the study by Krishna Koirala where all the patients were smokers and out of 86 patients,^[6] 61 patients (70%) had supraglottic carcinoma, 24 (28%) had glottic carcinoma and one patient had subglottic carcinoma.

We found that 32% of cases shows upstaging with CT scan, as a result of deep tumor extent undetectable at clinical examination, which is similar to the study done by Antonio Glison Monte^[7] who evaluated 39 patients with supraglottic squamous cell carcinoma with CT scan resulting in upstaging of 38.5% of cases, as a result of deep tumour extent. Peter Zbaren, Minerva Baker, Hubert studied that clinical evaluation failed to correctly stage 17 tumours due to invasion of paraglottic, preepiglottic space resulting in pretherapeutic staging accuracy of

57.5% They concluded that radiological examination that is CT or MRI resulted in improved staging accuracy.^[5]

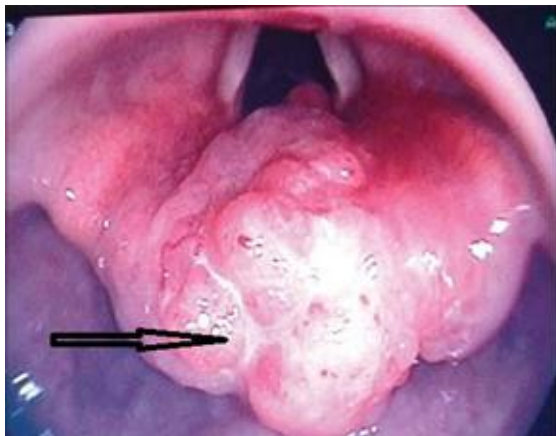


Figure 3: Photograph showing supraglottic mass (arrow) seen in larynx on endoscopy.

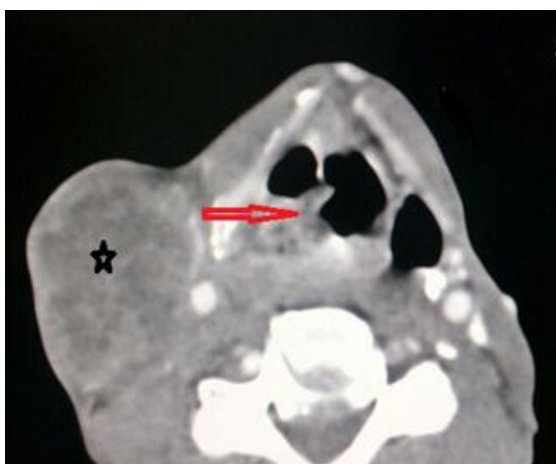

Figure 4: CECT neck axial scan showing heterogeneously enhancing thickening and mass lesion in the right supraglottic region with thickening of right aryepiglottic fold (arrow); a (star) shows necrotic lymph node mass suggestive of secondary deposit.

An accurate pretherapeutic staging is required for optimal treatment planning and, for evaluation and comparison of the results of different treatment modalities. Supraglottic and glottic carcinomas demonstrating pre-epiglottic or paraglottic space invasion are staged as at least T3 tumors, regardless of whether vocal cord fixation is evident clinically. Because these spaces communicate, there is no barrier to prevent spread of tumor between them once one is invaded. Furthermore, tumor involvement of these spaces is associated with a greater likelihood of nodal metastasis and poorer cure rate after RT.^[8-11] Pre epiglottic space invasion also affects reconstructions options for supracricoid laryngectomies, because minor preepiglottic invasion is a contraindication for supracricoid laryngectomies with cricohyoidoepiglottopexy, whereas massive preepiglottic space even precludes

supracricoid laryngectomies with cricohyoidopexy.^[12] Transglottic tumors cross the laryngeal ventricle or anterior commissure to involve both the supraglottic or glottis. Extension of a supraglottic tumor below the laryngeal ventricle to the glottis is a contraindication to performing a standard horizontal supraglottic partial laryngectomy.^[13] Extralaryngeal spread of tumor with carotid artery or prevertebral soft tissue involvement represents very advanced local disease (stage T4b) and is generally considered unresectable. If a tumor contacts less than 180 degree of the circumference of the carotid, then likelihood of invasion is low, whereas encasement of greater than 270 degree of the vessels circumference is associated with a high probability of invasion. When the interface is between 180 degree and 270 degree, the likelihood of carotid invasion cannot be determined reliably with imaging.^[14]

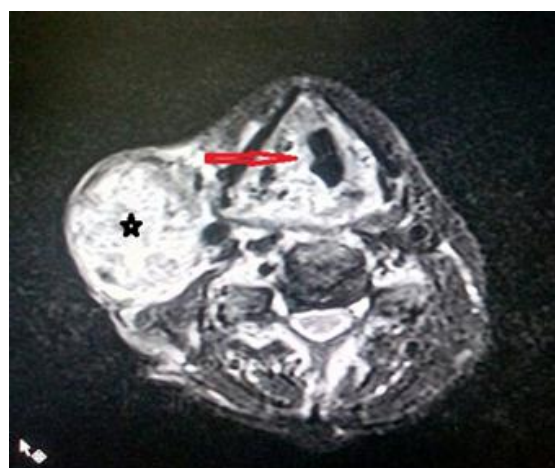


Figure 5: T2 axial MR image showing hyperintense signal intensity mass lesion involving the supraglottic region on right side (red arrow) along with lymph node mass (star).

Positron emission tomography- Positron emission tomography is an imaging technique utilizing radioisotopes that emit positrons. Fluorine-labeled deoxyglucose (18F-FDG), a glucose analogue, is the isotope used for 98 per cent of PET imaging. Like other forms of nuclear medicine, PET imaging provides functional information. As the anatomical detail and special resolution of a PET scan alone is relatively poor, anatomical correlation with CT or MRI is necessary. Combined in-line PET-CT scanners allow accurate co registration of the functional information from the PET scan and the anatomical information from a non-contrasted relatively low-dose CT scan. PET-CT has a higher accuracy of depicting cancer and evaluating its anatomical localization, than PET alone.^[15]

False-positive results in PET-CT can occur due to normal physiological uptake in tissues, such as the tonsils and salivary glands. Tracer also accumulates in metabolically active tissues and in muscles, secondary to contraction, such as phonation, during

the uptake phase. False negative results are seen in tumours with low metabolic activity, such as salivary gland tumours, in necrotic tumour, and in patients who have undergone recent treatment, particularly

PET-CT performed within four months of radiation therapy.^[16]

In patients with suspected head and neck cancer 18F-FDG PET-CT is a valuable tool in the preoperative staging of head and neck tumours, as it can evaluate regional lymph node metastases, detect distant metastases and identify unsuspected synchronous primary lesions. It is also useful in evaluating patients with proven pathological cervical adenopathy but an unknown primary lesion.^[17] However, 18F-FDG PET-CT rarely provides additional information regarding the T stage of tumour over initial clinical evaluation and cross-sectional imaging with CT and MR. 18F-FDG PET-CT is useful in the postoperative patient to monitor tumour recurrence and, after chemo radiotherapy, it can be used to evaluate the response of lesions to treatment, and aid selection of patients for subsequent neck dissection or salvage surgery.^[18]

CONCLUSION

From the present study we have come to conclusion that laryngeal malignancy is a disease of elderly male having habit of smoking and consuming alcohol. Clinical examination alone fails to identify tumor invasion of laryngeal cartilages and of extralaryngeal soft tissue resulting in low staging accuracy. CT and MRI allows excellent depiction of the anatomy of larynx and characteristic pattern of submucosal tumor extension, therefore changing the staging which further has an important impact on treatment of patients.

REFERENCES

- Esteve J, Kricker A, Ferlay J, Parkin NM, editors. Lyon: World Health Organisation; 1993. In facts and figures of cancer in the European Community. International agency for Research on Cancer commission of the European.
- Sobin LH, Gospodarowicz M, Wittekind C. TNM classification of malignant tumours, UICC, 7th edn. New York: Wiley-Liss, 2009.
- Edge SB, Byrd DR, Compton CC et al.(eds). The AJCC cancer staging manual, 7th edn. New York: springer,2009.
- Ronald N. Assessment and staging. Stell & Maran's Textbook of Head and Neck 2007; 29: 986-95.
- Peter Zbaren, Minerva Beker, Hubert Lang, prospectively staged laryngeal carcinoma pretherapeutically by clinical finding, CT and MRI 1996, Head and neck surgery, CH 3000 Bern Switzerland.
- Krishna koirala et al. Epidemiological study of laryngeal carcinoma in western Nepal. Asian Pacific Journal of Cancer Prevention. Vol.16, 2015; 6541-6544.
- Antonio Gilson Monte Aragao Jr, Ricardo Pires de Souza, Abrao Rapoport et al. Computed tomography contribution to the staging of supraglottic squamous cell carcinoma. Radiol Bras 2007; 40(4): 241-246.
- Loenver LA, Yousem DM, Montone KT, et al. Can radiologists accurately predict Preepiglottic space invasion with MR imaging? AJR Am J Roentegol 1997; 169(6): 1681-7.
- Curtin HD. Imaging of larynx: current concepts. Radiology 1989; 173(1): 1-11.
- Dursun G, Keser R, Akturk T, et al. The significance of pre-epiglottic space invasion in supraglottic laryngeal carcinomas. Eur Arch Otorhinolaryngol 1997; 254(suppl 1): S110-2.
- Murakami R, Nishimura R, Baba Y, et al. Prognostic factors of glottic carcinomas treated with radiation therapy: value of the adjacent sign on radiological examinations in the sixth edition of the UICC TNM staging system. Int J Radiat Oncol Biol Phys 2005; 61(2):471-5.
- Ferreiro-Arguelles C, Jimenez-Juan L, Martinez-Salazar JM, et al. CT findings after laryngectomy. Radiographics 2008; 28(3):869-82[quiz: 914].
- Chawla S, Carney AS. Organ preservation surgery for laryngeal cancer. Head Neck Oncol 2009; 1:12.
- Yousem DM, Hatabu H, Hurst RW, et al. Carotid artery invasion by head and neck masses: prediction with MR imaging. Radiology 1995; 195(3): 715-20.
- Schoder H, Yeung HWD, Gonen M et al. Head and neck cancer: clinical usefulness and accuracy of PET/CT image fusion. Radiology 2004; 231: 65-72.
- Blodgett TM, Fukui MB, Snyderman CH et al. Combined PET-CT in head and neck: Part 1. Physiological, altered physiological and artifactual FDG uptake. Radiographics 2005; 25: 897-912.
- Quon A, Fischbein NJ, McDougall IR et al. Clinical role of 18F-FDG PET/CT in the management of squamous cell carcinoma of the head and neck and thyroid carcinoma. Journal of Nuclear Medicine 2007; 48: 58S-67S.
- Ong SC, Schoder H, Lee NY et al. Clinical utility of 18FFDG PET/CT in assessing the neck after concurrent chemoradiotherapy for locoregional advanced head and neck cancer. Journal of Nuclear Medicine 2008; 49: 532-40.
- Haughey BH, Gates GA, Arfken CL et al. meta analysis of second malignant tumours in head and neck cancer: the case for endoscopic screening protocols. Annals of Otolaryngology, and Laryngology 1992; 101 :105-12.
- Houghton DJ, Hughes ML, Garvey C. role of chest CT scanning in the management of patients presenting with head and neck cancer. Head and Neck 1998; 20:614-18.
- Michales L Ear, nose and throat histopathology. New York: springer Verlag 1987.
- Fukui MB, Blodgett TM, Snyderman CH et al. Combined PET-CT in the head and neck: Part 2. Diagnostic uses and pitfalls of oncologic imaging. Radiographics 2005; 25:913-30.
- Wortzman G, Holgate RC, computerized tomography in otolaryngology. Laryngoscope 1976.
- Daniel G. deschler, Terry Day, in the Pocket Guide to TNM staging of head and neck cancer and neck dissection classification; published by American Academy of Otolaryngology -Head and Neck surgery Foundation, Inc. third edition 2008.
- S.Cagh, M.Ozturk, I. Yuce, K. Deniz, E. Guney. prospectively researched the value of routine clinical and radiological in predicting neoplastic invasion of larynx.2009.Department of Otorhinolaryngology and Head and Neck surgery, Radiology and pathology, Erciyes university, Kayseri, Turkey.
- John Watkinson, Mark N Gaze, Janet Wilson Chpt 14; in Steel and Maran's head and neck surgery fourth edition 2008.
- Evidence Based Management Guidelines for Head and Neck Cancer, volume four 2005 published by Tata Memorial Hospital, 2005.
- American joint Committee on cancer, cancer staging handbook 6th. New York: Springer; 2002.

Geeta & Pant; Pretherapeutic Clinical and Radiological Staging of Laryngeal Malignancy

29. Pillsbury HRC, Kirchner JA. Clinical verses histopathologic staging in laryngeal cancer. Arch Otolaryngol Head Neck Surgery 1979.
30. Sulfaro S, Barazan L, Qurein F, Lutman M, Caruso G. T staging of the laryngohypopharyngeal carcinoma. Arch Otolaryngeal Head and Neck surgery 1989.
31. Peter D phelps.chpt 47, pharynx and larynx. In David Suttons textbook of radiology and imaging.

How to cite this article: Geeta, Pant B. Correlation between Pretherapeutic Clinical and Radiological Staging of Laryngeal Malignancy: A Clinico -Radiological Study. Ann. Int. Med. Den. Res. 2018; 4(1):EN19-EN24.

Source of Support: Nil, **Conflict of Interest:** None declared