

Complications of Thyroid Surgery: Our Experience.

Vinti Jain¹, Akshay Jain², Probal Chatterji³

¹Junior Resident, Department of ENT&HNS, TMMC&RC, Moradabad.

²Assistant Professor, Department of ENT &HNS, TMMC&RC, Moradabad.

³Professor & Head, Department of ENT &HNS, TMMC&RC, Moradabad.

Received: February 2018

Accepted: February 2018

Copyright: © the author(s), publisher. It is an open-access article distributed under the terms of the Creative Commons Attribution Non-Commercial License, which permits unrestricted non-commercial use, distribution, and reproduction in any medium, provided the original work is properly cited.

ABSTRACT

Background: The purpose of this study was to evaluate the complications of thyroid surgery and their management. **Methods:** A prospective study was conducted on 50 patients at Teerthankar Mahaveer Medical College and Research Centre Teerthankar Mahaveer University, Moradabad, Uttar Pradesh over a period of 12 months. Patients undergoing thyroid surgery in our department were included in this study after taking proper written informed consent. Complete history was taken and thorough ENT examination was performed. Clinical and laboratory data from the study was recorded as per the pro forma. **Results:** Among the patients undergoing surgery, Isthmusectomy was performed in 3 (6.0%) patients, Left hemithyroidectomy in 5 (10.0%) patients, Right hemithyroidectomy in 28 (56.0%), Subtotal thyroidectomy in 6 (12.0%) patients, Near total thyroidectomy in 3 (6.0%) patients and Total thyroidectomy in 5 (10.0%) patients. The most common complication that occurred was hypocalcemia(16%). Other complications observed were permanent hypoparathyroidism (6%), permanent recurrent laryngeal nerve palsy (4%), superior laryngeal nerve palsy (2%), post-operative haemorrhage (2%), seroma (8%), hypertrophic scar (8%), keloid (2%), wound infection (6%). **Conclusion:** The most common complications generally observed are hypoparathyroidism and recurrent laryngeal nerve injuries.

Keywords: Hemithyroidectomy, subtotal thyroidectomy, subtotal thyroidectomy, total thyroidectomy, hypocalcemia, hypoparathyroidism, recurrent laryngeal nerve palsy.

INTRODUCTION

The thyroid is a gland of internal secretion and a unique site of several diseases which may be managed medically or surgically or by a combination of both. The association of high prevalence of thyroid diseases with publications from diverse regions and different schools of surgery often results in heterogeneous information that helps feed the controversy about their best mode of management.^[1-5]

Thyroid nodules are very frequent. Many patients present with a palpable enlargement of the thyroid gland and surgery is commonly performed on these patients. Numerous complications may arise following the surgical removal of the thyroid gland. These problems often result from surgical technique, aberrant anatomy, infections etc. Although the incidence of these complications is low, some problems are seen more frequently than others.^[6]

Thyroid surgery was rarely performed until the late nineteenth century. Total thyroidectomies were only performed occasionally for indications other than cancer until the last quarter of the twentieth

century.^[2] The use of total thyroidectomy remains controversial for small differentiated thyroid carcinomas, but even more controversial is its use to treat benign diseases.^[7] Most surgeons avoid the procedure owing to the possible complications such as permanent recurrent laryngeal nerve palsy and permanent hypoparathyroidism; subtotal thyroidectomy has been the preferred operation for benign thyroid diseases.^[7]

However, the indication of total thyroidectomy (TT) for certain benign diseases is a trend that is gaining acceptance in the last two decades. Although the extent of resection for benign diseases remains controversial, an increasing number of total thyroidectomies are currently being performed in specialist endocrine surgery units and the indications for this procedure include Graves disease and multinodular goitre.^[7]

The disadvantages of subtotal thyroidectomy to treat multinodular goitre are that the procedure does not reduce the risk of persisting symptoms and has a high recurrence rate (30%–50%) owing to the gland remnants, even under hormonal suppression treatment with L-thyroxine.^[7] Disease recurrence usually requires a repeat surgery which greatly increases the risk (up to 20 times) of damage to the parathyroid glands and laryngeal nerves.

TT should be considered in cases of suspected malignant nodules, multinodular nontoxic goiter

Name & Address of Corresponding Author

Dr. Akshay Jain
Assistant Professor,
Department of ENT &HNS,
TMMC&RC, Moradabad.

with bilateral involvement of thyroid follicular tumors, autoimmune thyroiditis and reoperations. It should also be considered in cases of nodules with a history of prior irradiation to the head and neck and diffuse toxic goiter where resection can be an excellent treatment,^[3,8,9] especially in large goiters, in patients with severe ophthalmopathy, in children, in pregnant women and in those with a mental disability that impairs long-term follow-up.^[10]

The most serious complication is bleeding into the operative site with airway compromise due to formation of a hematoma. Immediate evacuation of the clot and ligation of bleeding vessels is required.^[11] This occurs in early post-operative period.

Complications will occur infrequently if the surgeon is fully knowledgeable about the anatomy of the thyroid gland and its adjacent organs. The nervous, vascular and other structures met in performing a thyroidectomy must be identified and preserved to avoid complications both during operation and after the wound has been closed.^[12]

However these days, parathyroid preservation and implantation has reduced the chances of postoperative hypoparathyroidism.^[13,14]

While prevention of all these complications is a primary goal during thyroid surgery, early recognition and management by the surgeon is essential for the safe recovery of the patient.^[15,16]

MATERIALS AND METHODS

Source of Data

This cross-sectional observational study was conducted to assess the complications among the patients undergoing thyroid surgeries in the ENT department, Teerthanker Mahaveer Medical College & Research Centre, Moradabad.

Study Population

The study population selected was the patients attending the department of ENT, Teerthanker Mahaveer Medical College & Research Centre, Moradabad.

Data collected from the patients was regarding clinical history, physical examinations, hormonal profile, diagnostic investigations, operative procedures and complications of thyroid surgery and post-operative management. A uniform proforma of history taking, clinical examination and investigations was followed.

Inclusion Criteria

1. Euthyroid patient presenting with thyroid swelling
2. Patients without associated parathyroid pathology

Exclusion Criteria

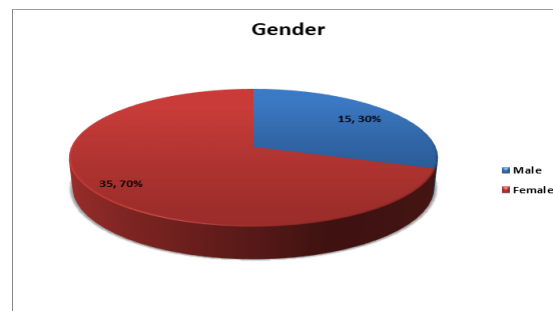
1. Patients refusing thyroid surgeries
2. Patients who did not report for follow-up

RESULTS & DISCUSSION

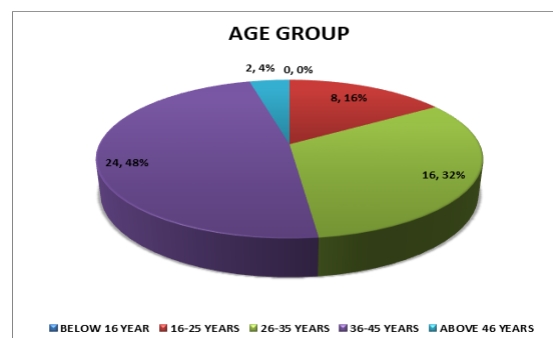
The present cross-sectional observational study was conducted to assess the complications among the patients undergoing thyroid surgeries in our institute.

Age & sex distribution

In our study, there were 30.0% males and 70.0% females. The composition of the study population was similar to the study by Aytac and Karamercan,^[17] 339 (81.1%) were females and 79 (18.9%) were male.



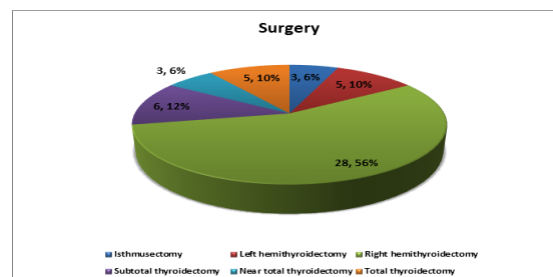
The study population had 8 patients in 16-25 years age group, 16 in 26-35 years age group, 24 in 36-45 years age group and 2 above 46 years.



Distribution according to type of surgery

In the present study, Isthmusectomy was performed in 3 (6.0%) patients, Left hemithyroidectomy in 5 (10.0%) patients, Right hemithyroidectomy in 28 (56.0%), Subtotal thyroidectomy in 6 (12.0%) patients, Near total thyroidectomy in 3 (6.0%) patients and Total thyroidectomy in 5 (10.0%) patients.

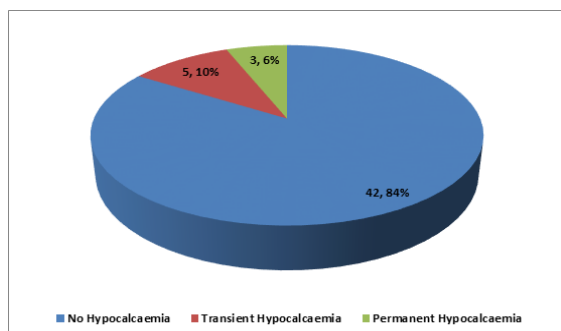
In the study by Flynn et al,^[18] 45 patients (49%) underwent total thyroidectomy, 28 (31%) subtotal thyroidectomy, and 18 (20%) thyroid lobectomy for the surgical resection for thyroid carcinoma.



Complications

A total of 50 patients were studied during the study and their complications observed and recorded. Post-operative wound infection was found among 3 (6.0%) patients.

Hypocalcemia was found amongst 8 (16%) patients in the post operative period. Of them, 5 were transient (2 were seen in cases of total thyroidectomy, 2 in near total thyroidectomy and 1 in subtotal thyroidectomy). Transient hypocalcemia resulted probably due to hampered blood supply to the parathyroids due to stretching of the vessels during surgery or thermal damage due to the use of cautery, which recovered spontaneously in the post operative period especially in the latter two group of patients. This was lesser than the study by Flynn et al, transient hypocalcemia was found among 38 (42%) patients but was higher than the study by Pandey et al.^[19] Temporary and permanent hypocalcemia was reported by 3.75% patients each. In all total thyroidectomy cases at least one parathyroid was preserved by implanting in the sternocleidomastoid muscle but probably their viability was not maintained so that 3 cases of permanent hypocalcemia were seen in this group. In study performed by Bergenfelz et al.^[20] authors reported that this correlation was independent of extent of thyroidectomy and neck dissection. It has also been indicated that routine use of autotransplantation will be useful in postoperative examination of the specimen and identification of parathyroid gland.^[21] Sassonet al.^[22] detected a significant correlation between incidental parathyroidectomy and postoperative hypocalcemia.



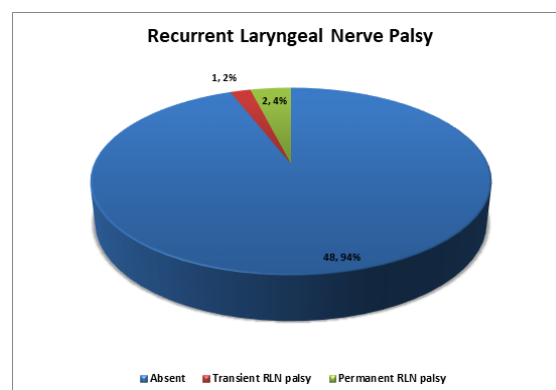
Post-operative Haemorrhage was found in 1 patient in the form of hematoma developing in the immediate post-operative period (within 6 hours of surgery).

Seroma was formed in 4 (8.0%) patients.

Hypoparathyroidism was found in 3 patients (all in cases of total thyroidectomy). The parathyroids were identified and routinely preserved by re-implanting at least one of them in the sternocleido-mastoid muscle. In 2 such cases of total thyroidectomies, the parathyroids regained vascularity but 3 cases resulted in permanent hypoparathyroidism. This was quite lesser than the studies by Ranga et al,^[23] hypoparathyroidism was present in 12% patients

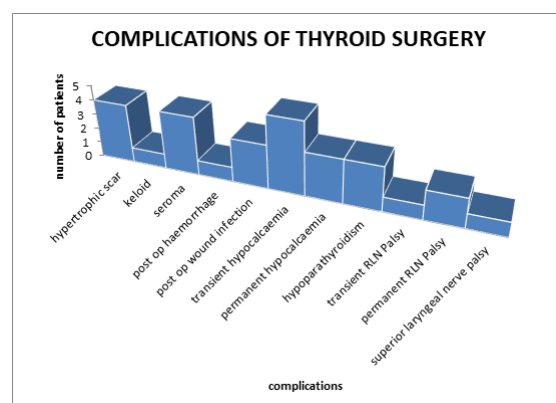
during hospital stay and 3 new patients detected in addition to these 6 patients during follow up, making a total of 9 patients.

Recurrent Laryngeal Nerve palsy was found among 2 (4.0%) patients. Transient palsy was seen in 1 patient which resolved within two weeks of steroid treatment. It was similar to the studies by Ranga et al,^[23] 10% incidence of RLN during thyroid surgery and Wagner and Seiler reported that in total lobectomy the permanent injury rate significantly increased from 3.8% to 7% when the nerve was not identified.^[24]



Superior Laryngeal Nerve Palsy was found in 1 (2.0%) patient. In the study by Osmólski et al,^[25] unilateral permanent laryngeal nerve injury was reported in 1% patients, in one patient it was permanent bilateral nerve injury and unilateral temporary nerve injury in 2%

Hypertrophic Scar was found among 4 (8.0%) patients and keloid was found in 1 (2.0%) patients.



Intraoperative identification of parathyroid glands is recommended. Any part removed should be analyzed to reveal incidental parathyroidectomy, and autotransplantation should be performed when needed to decrease risk of postoperative hypocalcemia. Similarly, in indicated cases, limited surgery, preferably lobectomy, and meticulous dissection in patients with more extensive surgery will decrease rates of incidental parathyroidectomy and development of postoperative hypocalcemia.

Our data support that total thyroidectomy is a valuable option, when surgery is indicated, for treating benign thyroid conditions such as multinodular goitre and Graves' disease. It has been shown that total thyroidectomy achieves immediate and permanent cure with no risk of disease recurrence or repeat surgeries.

The overall rate of complications can be minimized by doing a meticulous dissection, operating in a comparatively bloodless field ensuring proper identification of vital structures and preserving the parathyroid glands and the recurrent and the superior laryngeal nerves wherever possible.

Careful postoperative observation is required for timely intervention and management of symptoms of hypocalcaemia, recurrent nerve palsy and haemorrhage. Incidence of mortality is almost zero but morbidity is still continued. Prompt recognition of complications and its remedy can limit the morbidity in thyroid surgery.

CONCLUSION

The study of 50 cases undergoing thyroid surgery was done in the Department of ENT, Teerthankar Mahaveer University, Moradabad.

Among the study cases the various complications observed were hypocalcemia, hypoparathyroidism, recurrent laryngeal nerve palsies, superior laryngeal nerve palsy, seroma formation, hematoma formation, hypertrophic scar and keloid, post-operative wound infection.

The various complications during thyroid surgery depend on the extent and type of thyroid disease, surgeon's expertise, presence of co-morbidities and the patients' conditions and last but not the least, the extent of the surgery undertaken.

The most common complications generally observed are hypoparathyroidism and recurrent laryngeal nerve injuries. To prevent these, attempts must be made to identify these structures and preserve them.

The most common complication observed in this study was hypocalcemia, with five cases of transient hypocalcemia and 3 cases of permanent hypocalcemia.

5 cases in total had post-operative hypertrophic scar and keloid formation in the follow-up period. 4 cases of post-operative seroma formation were observed. 2 cases of permanent recurrent laryngeal nerve palsies were observed. There was 1 case each of superior laryngeal nerve palsy and post-operative hemorrhage.

Overall asepsis, careful dissection, hemostasis and preservation of other normal vital structures, restitution of function where possible, and following the overall principles of surgeries should be followed. Complications are low in number, when the surgeons are comfortable performing the surgeries and are well-versed about the anatomy and the function of the thyroid gland

The complications that occur are largely avoidable and correctible.

To achieve all this, the surgeons should be appropriately trained, maintain a high level of commitment, follow best practice regarding the surgeries and the management.

REFERENCES

1. Liu Q, Djuricin G, Prinz RA. Total thyroidectomy for benign thyroid disease. *Surgery* 1998; 123(1):2-7.
2. Gough IR, Wilkinson D. Total thyroidectomy for management of thyroid disease. *World J Surg* 2000; 24(8):962-5.
3. Stokes OJ 3rd. Total thyroidectomy (TT) for management of benign thyroid disease. *World J Surg* 2004; 28(2):218; author reply 218-9.
4. Tezelman S, Borucu I, Senyurek Giles Y, Tunca F, Terzioglu T. The change in surgical practice from subtotal to near-total or total thyroidectomy in the treatment of patients with benign multinodular goiter. *World J Surg* 2009; 33(3):400-5.
5. Efremidou EI, Papageorgiou MS, Liratzopoulos N, Manolas KJ. The efficacy and safety of total thyroidectomy in the management of benign thyroid disease: a review of 932 cases. *Can J Surg*. 2009;52(1):39-44.
6. Beaugie John M, Principles of Thyroid Surgery, Kent; Pitman, 9th Medical publishing company Ltd, 2005: Page no 221.
7. Bellantone R, Lombardi CP, Bossola M, et al. Total thyroidectomy for management of benign thyroid disease: review of 526 cases. *World J Surg* 2002;26:1468-71.
8. Friguglietti CU, Lin CS, Kulcsar MA. Total thyroidectomy for benign thyroid disease. *Laryngoscope* 2003; 113(10):1820-6.
9. Hussain M, Hisham AN. Total thyroidectomy: the procedure of choice for toxic goitre. *Asian J Surg* 2008; 31(2):59-62.
10. Boger MS, Perrier ND. Advantages and disadvantages of surgical therapy and optimal extent of thyroidectomy for the treatment of hyperthyroidism. *SurgClin North Am* 2004; 84(3):849-74.
11. Hardy JD. Complications of thyroid and parathyroid surgery. In CP Artz and J D Hardy's Management of Surgical Complications, W B Saunders Company, Philadelphia, London, Toronto 2006: page no 291-308.
12. Scott-Brown's Otorhinolaryngology: Head and Neck Surgery 7thEd. Hodder Arnold Publication. volume 1;351.
13. Serdar T, Ismail B, Yasemin S, Faith T, Tamik T. The change in surgical practice from subtotal to near total or total thyroidectomy in treatment of patients with benign multinodular -goiter. *World J Surg* 2009;33(3):400-405.
14. Liu Q, Djuricin G, Prinza. Total thyroidectomy for benign thyroid disease. *Surg* 1998;123(1):2-7.
15. Geeta Lal, Orlo H Clark. Thyroid and parathyroid. Seymour I, Schwartz Principles of Surgery 8th edition, McGraw-Hill, 2005: Page no 1395-1470.
16. Donald P, Vrabc. "Historical perspectives in thyroid surgeries". Pellitte PK, Mc Cafferey TV. Delmar Endocrine surgery of the head and neck 9th edition, Thomson learning Inc, 2003: page no 1-13.
17. Aytac B, Karamercan A. Recurrent laryngeal nerve injury and preservation in thyroidectomy. *Saudi Med J*. 2005;26(11):1746-9.
18. Flynn MB, Lyons KJ, Tarter JW, Ragsdale TL. Local complications after surgical resection for thyroid carcinoma. *Am J Surg*. 1994;168(5):404-7.
19. Pandey AK, Maithani T, Agrahari A, Varma A, Bansal C, Bhardwaj A, Singh VP, Rathi S. Postoperative Complications of Thyroid Surgery: A Corroborative Study with an Overview of Evolution of Thyroid Surgery. *IntJ Head Neck Surg* 2015;6(4):149-54.

20. Bergenfelz A, Jonson S, Kristoffersson A, Martensson H, Reihner E, Willin G et al. Complications to thyroid Surgery: Results reported in a database from a multicentre audit comprising 3660 patients. *Langenbeck's Archives of surgery* 2008; 393: 667-73.
21. Olson JA Jr, DeBenedetti MK, Baumann DS, Wells SA Jr. Parathyroid autotransplantation during thyroidectomy. Results of long-term follow-up. *Ann Surg* 1996;223:472-8.
22. Sasson AR, Pingpank JF Jr, Wetherington RW, Hanlon AL, Ridge JA. Incidental parathyroidectomy during thyroid surgery does not cause transient symptomatic hypocalcemia. *Arch Otolaryngol Head Neck Surg*. 2001;127(3):304-8.
23. Ranga H, Arora B, Batra R, Garg D, Garg P, Verma N, Kamal H. Profile of Complication of thyroid surgery. *IJARESM* 2015;3(11):25-7.
24. Wagner HE, Seiler C. Recurrent laryngeal nerve palsy after thyroid gland surgery. *Br J Surg*. 1994;81(2):226-8.
25. Osmólski A, Frenkiel Z, Osmólski R. Complications in surgical treatment of thyroid diseases. *Otolaryngol Pol*. 2006;60(2):165-70.

How to cite this article: Jain V, Jain A, Chatterji P. Complications of Thyroid Surgery: Our Experience. *Ann. Int. Med. Den. Res.* 2018; 4(2):EN13-EN17.

Source of Support: Nil, **Conflict of Interest:** None declared